



Contents lists available at BioMedSciDirect Publications

International Journal of Biological & Medical Research

Journal homepage: www.biomedscidirect.com



Case report

The absence of peroneus tertius muscle on the dorsum of the foot

Dr.Sharadkumar Pralhad Sawant, Dr.Shaguphta T. Shaikh, Dr.Rakhi Milind More

Department of Anatomy, K.J.Somaiya Medical College, Somaiya Ayurvihar, Eastern Express Highway, Sion, Mumbai-400 022.

ARTICLE INFO

Keywords:

Peroneus Tertius
Extensor Digitorum Longus
Dorsiflexion and Eversion of Foot
Bipedal Walking
Tendon Graft Surgeries
Foot Surgeons
Anthropologists

ABSTRACT

Peroneus tertius (fibularis tertius) is a uniquely human muscle. It often appears to be part of extensor digitorum longus, and might be described as its 'fifth tendon'. The muscle fibres operating on this tendon arise from the distal third or more of the medial surface of the fibula, the adjoining anterior surface of the interosseous membrane, and the anterior crural intermuscular septum. The tendon passes behind the superior extensor retinaculum and within the loop of the inferior extensor retinaculum it shares with extensor digitorum longus. Peroneus tertius lies lateral to extensor digitorum longus. It is inserted into the medial part of the dorsal surface of the base of the fifth metatarsal bone, and a thin expansion usually extends forwards along the medial border of the shaft of the bone. During routine dissection for the first MBBS students, we observed that the peroneus tertius was absent on the dorsum of the left lower limb of a 70 years old, donated embalmed male cadaver in the Department of Anatomy, K.J.Somaiya Medical College, Sion, Mumbai, India. The photographs of the dorsum of the foot were taken for proper documentation and for ready reference. The absence of the peroneus tertius is very rare and not found in literature. Usually, the peroneus tertius is involved in dorsiflexion and eversion of the foot. The existence of peroneus tertius may help in the swing phase of bipedal walking. The peroneus tertius may be used for tendon graft surgeries. The pull of the peroneus tertius may be responsible for causing stress on the fifth metatarsal bone and account for all stress fractures in any individual. The absent peroneus tertius may misguide foot surgeons performing graft operations and transplant. The absent peroneus tertius is an interesting finding, which could be clinically important for Anatomists, Anthropologists, Surgeons and Orthopedic surgeons.

© Copyright 2010 BioMedSciDirect Publications IJBMR -ISSN: 0976:6685. All rights reserved.

1. Introduction

Peroneus tertius (Fibularis tertius) is a uniquely human muscle. It often appears to be part of extensor digitorum longus, and might be described as its 'fifth tendon'. The muscle fibres arise from the lower part of the medial surface of the shaft of the fibula, the adjoining anterior surface of the interosseous membrane, and the anterior crural intermuscular septum. The tendon passes behind the superior extensor retinaculum and within the loop of the inferior extensor retinaculum it shares with extensor digitorum longus. Peroneus tertius lies lateral to extensor digitorum longus. It is inserted into the medial part of the dorsal surface of the base of

the fifth metatarsal bone, and a thin expansion usually extends forwards along the medial border of the shaft of the bone. Peroneus tertius is supplied by the same vessels as extensor digitorum longus. The blood supply is derived from anterior and lateral branches of the anterior tibial artery, supplemented distally from the perforating branch of the peroneal artery and also proximally from the lateral inferior genicular, popliteal or anterior tibial recurrent arteries. At the ankle and in the foot, it is supplied by the anterior lateral malleolar artery and by lateral tarsal, metatarsal plantar and digital arteries. In the foot it receives an additional supply from the termination of the arcuate artery and the fourth dorsal metatarsal artery. Peroneus tertius is innervated by the deep peroneal nerve (1). During the swing phase of gait electromyographic studies show that peroneus tertius acts with extensor digitorum longus and tibialis anterior to produce dorsiflexion and eversion of the foot. This levels the foot and helps the toes to clear the ground, an action that improves the economy of

* Corresponding Author : - Dr.Sharadkumar Pralhad Sawant
25/2, Samrat Ashok Nagar Society, Shell Colony Road,
Chembur, Mumbai - 400 071, Maharashtra, India.
Telephone no.: 9322061220, 022-22936867
Fax no. : 022 - 2409 1855
E - mail : dr.sharadsawant@yahoo.com

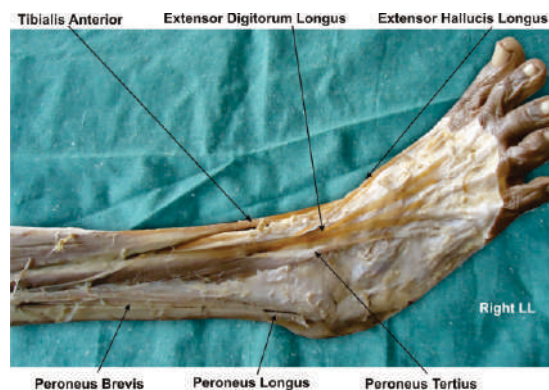
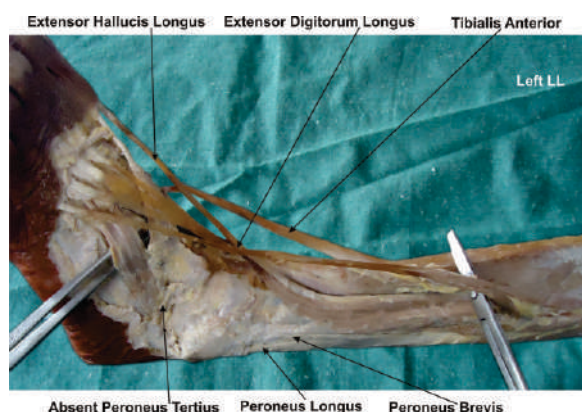
bipedal walking. The peroneus tertius is not active during stance phase, a finding that contradicts suggestions that it acts primarily to support the lateral longitudinal arch or to transfer the centre of pressure of the foot medially. The peroneus tertius cannot be tested in isolation, but its tendon can sometimes be seen when the foot is dorsiflexed against resistance (1). This muscle is seldom found in other primates, a fact that has linked its function to efficient terrestrial bipedalism (1,2,3). The peroneus tertius is considered to be a part of the extensor digitorum longus muscle and it is often described as the fifth tendon of the extensor digitorum longus muscle (1). Although closely associated with the extensor digitorum longus, the peroneus tertius has been considered the migrated part of the extensor digitorum brevis of the little toe (4). The presence of peroneus tertius is important for dorsiflexion and extension of the foot in swing phase of the gait (1). The insertion of the peroneus tertius might play an important role in the causation of torsional stresses as observed in Jones fractures and stress fractures (5). Foot surgeons might use the peroneus tertius muscle flap for transposition and also for correcting any laxity in the ankle joint (6,7). Thus, the presence or absence of peroneus tertius may be important from the academic and clinical point of view.

2. Materials & Methods:

Exposure of the dorsum of the foot was achieved following classical incisions and dissection procedures on a donated embalmed 70 years old male cadaver in the department of Anatomy at K.J. Somaiya Medical College, Sion, Mumbai. All the extensor tendons on the dorsum of the foot were dissected meticulously. The tendon of extensor digitorum longus going to the little toe was also observed carefully to note any thickening. The lower part of the medial surface of the fibula was also dissected properly. The photographs of the dorsum of the foot were taken for proper documentation and for ready reference.

Observations:

All the extensor tendons on the dorsum of the foot were observed. All the tendons of the extensor digitorum longus were observed. There was no thickening seen on the tendon of extensor digitorum longus going to the little toe. There was no signs of any muscle fibres arising from the lower part of the medial surface of the shaft of the fibula. There was no evidence of presence of peroneus tertius on the dorsum of the left foot.



3. Discussion:

Recently the peroneus tertius is called as fibularis tertius (8). The peroneus tertius normally originates from the medial surface of the distal third of the fibula (1,3). In the present study, the peroneus tertius was absent and there was no thickening of the extensor digitorum longus muscle. The peroneus tertius muscle is absent in many primates with much variation in the humans. Interestingly, in the animal kingdom, the peroneus tertius muscle is found occasionally in the apes and the gorillas (9). The variability of the muscle suggests that the absence of peroneus tertius muscle may be a primitive condition for anthropoids (10). The presence of peroneus tertius is an evident of evolution (9).

The peroneus tertius tendon can be used for transplant surgeries. In foot drop, the tibialis posterior tendon manipulation might be required. There are past reports of the tibialis posterior tendon being transferred to the anterior compartment and anastomosed to the peroneus tertius tendon (11). The peroneus tertius causes dorsiflexion and eversion of the foot during the swing phase of gait and it is important that the toes be lifted from the ground to assist in bipedal walking (4). The attachment of the peroneus tertius to the fifth metatarsal might define its role in providing proper support to the outer aspect of the sole of the foot. We, as anatomists believe that in the absence of the peroneus tertius as seen in the present study, the support along the lateral border would be weakened. It should not be forgotten that both Jones' fractures and stress fractures involve the proximal fifth metatarsal and the insertion of the peroneus tertius might play an important role in imposing torsional stress (5). The individuals with out peroneus tertius would be less vulnerable to such stress fractures. The peroneus tertius may be considered as an accessory muscle for eversion and dorsiflexion. Witvrouw et al have noted that eversion or dorsiflexion may not be affected in case of absent peroneus tertius (12). The absent peroneus tertius may misguide foot surgeons performing graft operations and transplant surgeries. Hence radiological imaging techniques must be performed to confirm the existence of the peroneus tertius muscle before planning any operations on the foot.

4. Conclusion:

Anthropologically, the peroneus tertius muscle has been found to be evolutionary in nature with its role in bipedal walking. The individuals with out peroneus tertius would be less vulnerable to stress fractures. The peroneus tertius may be considered as an accessory muscle for eversion and dorsiflexion. The absent peroneus tertius may not affect the eversion or dorsiflexion. The absence of Peroneus tertius may be asymptomatic and hence radiological imaging techniques must be performed to confirm the existence of the peroneus tertius muscle before planning graft operations and transplant surgeries on the foot. The absent peroneus tertius is an interesting finding, which could be important for Anatomists, Anthropologists, Surgeons and Orthopedic surgeons.

Competing Interests

The authors declare that they have no competing interest.

Authors' contributions

SPS wrote the case report, performed the literature review & obtained the photograph for the study. RMM performed the literature search and assisted with writing the paper. STS conceived the study and helped to draft the manuscript. All authors have read and approved the final version manuscript.

Acknowledgement :

All the authors wish to convey our sincere thanks to Dr. Arif A. Faruqui for his valuable help, support and inspiration. Authors also acknowledge the immense help received from the scholars whose articles are cited and included in references of this manuscript. The authors are also grateful to authors / editors / publishers of all those articles, journals and books from where the literature for this article has been reviewed and discussed.

5. References

- [1] Williams P. L., Bannister L. H., Berry M. M., Collins P., Dyson M., Dussek J. E., Ferguson M. W. J. (eds), *Gray's Anatomy. The anatomical basis of medicine and surgery*, 39th edition, Churchill Livingstone, Edinburgh, 2005, 1497 - 1498.
- [2] Snell R. S., *Clinical anatomy for medical students*, 7th edition, Lippincott Williams & Wilkins, Baltimore, 2000, 561-562.
- [3] Sinnatamby C. S., *Last's Anatomy. Regional and Applied*, 10th edition, Churchill Livingstone, Edinburgh, 2000, 148.
- [4] Joshi S. D., Joshi S. S., Athavale S. A., *Morphology of peroneus tertius muscle*, *Clin Anat*, 2006, 19(7):611-614.
- [5] Vertullo C. J., Glisson R. R., Nunley J. A., *Torsional strains in the proximal fifth metatarsal: implications for Jones and stress fracture management*, *Foot Ankle Int*, 2004, 25(9):650-656.
- [6] Arnold P. G., Yugueros P., Hanssen A. D., *Muscle flaps in osteomyelitis of the lower extremity: a 20-year account*, *Plast Reconstr Surg*, 1999, 104(1):107-110.
- [7] Karlsson J., Wiger P., *Longitudinal split of the peroneus brevis tendon and lateral ankle instability: treatment of concomitant lesions*, *J Athl Train*, 2002, 37(4):463-466.
- [8] Rourke K., Dafydd H., Parkin I. G., *Fibularis tertius: revisiting the anatomy*, *Clin Anat*, 2007, 20(8):946-949.
- [9] Kimura K., Takashashi Y., *The peroneus tertius muscle in the crab-eating monkey (Macaca fascicularis)*, *Okajimas Folia Anat Jpn*, 1985, 62(3-4):173-185.
- [10] Jungers W. L., Meldrum D. J., Stern J. T. Jr., *The functional and evolutionary significance of the human peroneus tertius muscle*, *J Hum Evol*, 1993, 25:377-386.
- [11] Ozkan T., Tuncer S., Ozturk K., Aydin A., Ozkan S., *Tibialis posterior tendon transfer for persistent drop foot after peroneal nerve repair*, *J Reconstr Microsurg*, 2009, 25(3):157-164.
- [12] Witvrouw E., Borre K. V., Willems T. M., Huysmans J., Broos E., De Clercq D., *The significance of peroneus tertius muscle in ankle injuries: a prospective study*, *Am J Sports Med*, 2006, 34(7):1159-1163.