

**IJCRR**

Vol 04 issue 21

Section: Healthcare

Category: Case Report

Received on: 14/08/12

Revised on: 28/08/12

Accepted on: 10/09/12

VARIANT AXILLARY ARTERY – A CASE REPORT

Sharadkumar Pralhad Sawant, Shaguphta T. Shaikh, Rakhi Milind More

Department of Anatomy, K. J. Somaiya Medical College, Somaiya Ayurvihar, Eastern Express Highway, Sion, Mumbai, M.S., India

E-mail of Corresponding Author: dr.sharadsawant@yahoo.com

ABSTRACT

During routine dissection for the undergraduate medical students, we observed the variations in the course and distribution of axillary artery in the right upper limb of a 80 years old donated embalmed male cadaver in the Department of Anatomy, K. J. Somaiya Medical College, Sion, Mumbai, India. In the present case the axillary artery, 1cm distal to the outer border of first rib divided into superficial and deep brachial arteries. The superficial brachial artery continued as brachial artery proper and divided at the level of neck of radius into radial and ulnar arteries. The deep brachial artery performed the role of axillary artery in the axilla. It gave rise to all branches which are usually given by the axillary artery. The deep brachial artery first gave superior thoracic, thoracoacromial, lateral thoracic artery & articular branch to the shoulder joint. It then divided into anterior & posterior divisions. The anterior division gave anterior circumflex humeral, posterior circumflex humeral and profunda brachii artery. The posterior division continued as the subscapular artery and it gave rise to the circumflex scapular and thoracodorsal arteries. The deep brachial artery giving rise to all branches which are normally given by first, second and third part of axillary artery is very rare and not found in literature. The profunda brachii artery arising from anterior division of deep brachial artery is also very rare and not found in literature. The axillary vein was on medial side of superficial brachial artery in the arm. The cords of brachial plexus were around the superficial and deep brachial artery. The origin, course and distribution of axillary artery was normal on the left side of the same male cadaver. The photographs of the variations of axillary artery were taken for proper documentation and for ready reference.

Conclusion: Topographical anatomy of the normal and abnormal variations of the axillary artery is clinically important for surgeons, orthopaedicians and radiologists performing angiographic studies on the upper limb. The appropriate diagnostic interpretation and therapeutic intervention can be achieved on the basis of knowledge of such variations.

Key words: Axillary Artery, Superficial Brachial Artery, Deep Brachial Artery, Anterior & Posterior Division Of Deep Brachial Artery, Angiographic Studies, Radiologists, Orthopaedicians, Shoulder Joint.

INTRODUCTION

The axial artery of the upper limb is derived from the lateral branch of the seventh cervical intersegmental artery. This axial artery becomes axillary, brachial, radial and ulnar arteries on further development. At the level of the outer border of the first rib the subclavian artery

continues as the axillary artery. The axillary artery ends at the level of the lower border of the teres major muscle and continues downwards as the brachial artery. The brachial artery is the main artery of the arm. During the course of the axillary artery the pectoralis minor muscle crosses it anteriorly and divides the course of artery into

three parts; proximal to the pectoralis minor muscle is the first part, posterior to the muscle is second part and distal to the muscle is the third part of the axillary artery. The first part of axillary artery gives one branch i.e. superior thoracic artery which is arising at the level of the lower border of subclavius muscle. The superior thoracic artery may arise from the thoraco acromial artery.

The second part of axillary artery gives two branches i.e. thoraco acromial artery and lateral thoracic artery. The thoraco acromial artery is covered by the pectoralis minor muscle. It comes out from the medial border of the pectoralis minor muscle and pierces the clavipectoral fascia. It divides into pectoral, acromial, clavicular and deltoid branches of which the pectoral branch is the largest branch. The lateral thoracic artery comes out from the lateral border of the pectoralis minor muscle. It is large in females and has lateral mammary branches which supply the breast. The third part of axillary artery gives three branches i.e. subscapular, anterior and posterior circumflex humeral arteries. The subscapular artery is the largest branch arising from the lower border of the subscapularis muscle. In the lower part it is accompanied by the thoracodorsal nerve (C6, 7,8). The subscapular artery terminates into larger circumflex scapular and smaller thoracodorsal arteries. The circumflex scapular artery during its course interrupts the origin of teres minor muscle and appears into the upper triangular space, which is bounded above by subscapularis muscle, below by teres major muscle and laterally by long head of triceps brachii muscle. The circumflex scapular artery gives two important cutaneous branches, the upper (scapular) and the lower (parascapular). The scapular flap (upper cutaneous or scapular branch) and the parascapular flap (lower cutaneous or parascapular branch) are used for reconstructions in the areas of missing tissues. The thoracodorsal artery runs along the lateral (axillary) border of scapula and enters the deep surface of the latissimus dorsi muscle along with the nerve to latissimus dorsi. The anterior

circumflex humeral artery originates at the lower border of sub scapularis muscle from the lateral side of the third part of the axillary artery as a smaller branch. It runs around the surgical neck of the humerus anteriorly and anastomoses with the posterior circumflex humeral artery. It gives an ascending branch which supplies the head of the humerus and the shoulder joint. The posterior circumflex humeral artery is the larger branch originating at the same level of the anterior circumflex humeral artery. It runs along with axillary nerve (C5, 6) in the quadrangular space. The quadrangular space is bounded above by teres minor muscle, below by the teres major muscle, medially by the long head of triceps brachii muscle and laterally by the surgical neck of the humerus. It runs round the neck of the humerus and supplies the shoulder joint. It anastomoses with anterior circumflex humeral artery. It gives a descending branch which anastomoses with the ascending branch of the profunda brachii artery (1). The branches of subclavian and axillary arteries show extensive collateral circulation around the scapula so that the sound knowledge of neuromuscular variation is important for surgeons who remove the axillary lymph nodes, to anaesthesiologist and orthopaedic surgeons considering the frequency of procedures done in this region. Sometimes many of the branches may originate from a common stem or arise separately (2). These variations, are well documented in literature. The second part of axillary artery may give rise to a third branch i.e. alar thoracic artery. The second part of the axillary artery may give only one branch i.e. the thoraco-acromial artery and the second branch i.e. the lateral thoracic artery may be absent. Variations are common in the branching pattern of the third part of the axillary artery. A common arterial trunk may give rise to the scapular artery and the posterior circumflex humeral artery or it may give rise to subscapular, anterior and posterior circumflex humeral and profunda brachii arteries. The profunda brachii artery rarely gives the posterior

circumflex humeral artery which will pass below the teres major muscle and not through the quadrangular space. The axillary artery may give rise to high origin of radial and ulnar arteries and rarely the anterior interosseous artery may arise from axillary artery.

Case Report:

During routine dissection for the undergraduate medical students, we observed the variations in the course and distribution of axillary artery in the right upper limb of a 80 years old donated embalmed male cadaver in the Department of Anatomy, K. J. Somaiya Medical College, Sion, Mumbai, INDIA. In the present case the axillary artery, 1cm distal to the outer border of first rib divided into superficial and deep brachial arteries. The superficial brachial artery continued as brachial artery proper and divided at the level of neck of radius into radial and ulnar arteries. The deep brachial artery performed the role of axillary artery in the axilla. It gave rise to all branches which are usually given by the axillary artery. The deep brachial artery first gave superior thoracic, thoracoacromial, lateral thoracic artery & articular branch to the shoulder joint. It then divided into anterior & posterior divisions. The anterior division gave anterior circumflex humeral, posterior circumflex humeral and profunda brachii artery. The posterior division continued as the subscapular artery and it gave rise to the circumflex scapular and thoracodorsal arteries. The deep brachial artery giving rise to all branches which are normally given by first, second and third part of axillary artery is very rare and not found in literature. The profunda brachii artery arising from anterior division of deep brachial artery is also very rare and not found in literature. The axillary vein was on medial side of superficial brachial artery in the arm. The cords of brachial plexus were around the superficial and deep brachial artery. The origin, course and distribution of axillary artery was normal on the left side of the same male cadaver. The photographs of the

variations of axillary artery were taken for proper documentation and for ready reference.

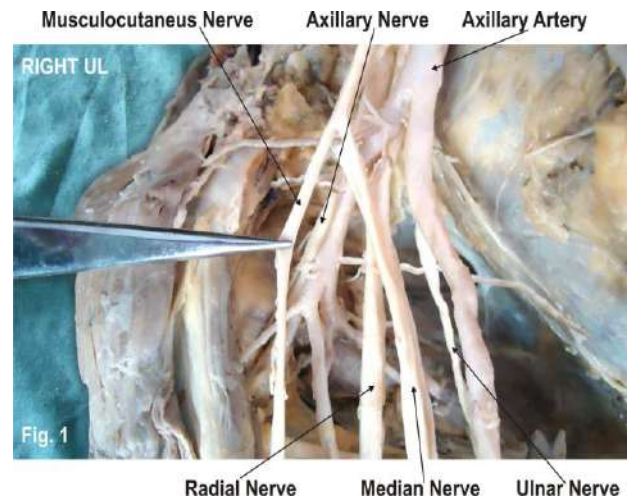


Figure 1: Photograph representation of the axillary artery of right upper limb divided into superficial brachial and deep brachial arteries.

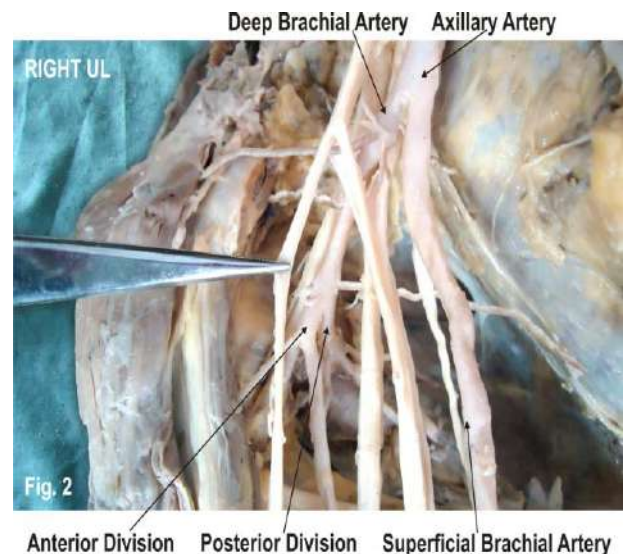


Figure 2: Photograph representation of the superficial brachial artery continued in the arm without giving any branches. The deep brachial artery divided into anterior & posterior division.

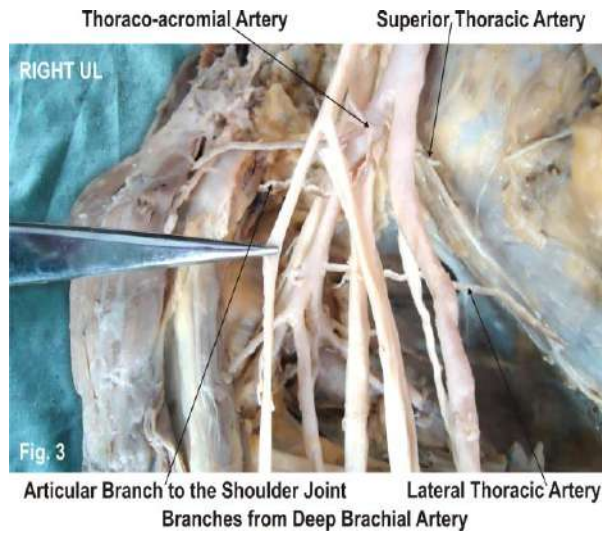


Figure 3: Photograph representation of the deep brachial artery first gave superior thoracic, thoracoacromial, lateral thoracic artery & articular branch to the shoulder joint.

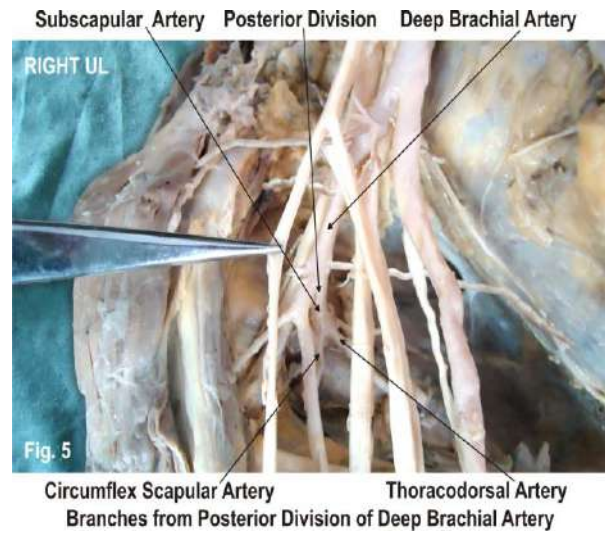


Figure 5: Photograph representation of the posterior division of deep brachial artery continued as subscapular artery gave rise to circumflex scapular and thoracodorsal artery.

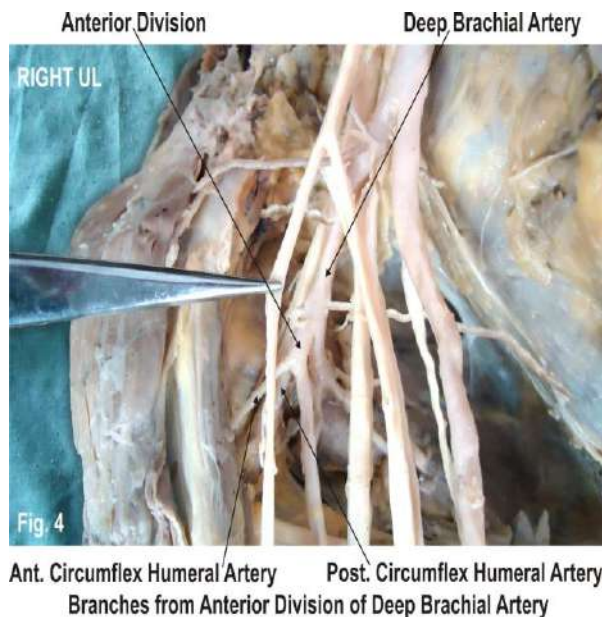


Figure 4: Photograph representation of the anterior division of deep brachial artery gave rise to anterior circumflex humeral, posterior circumflex humeral and profunda brachii artery.

DISCUSSION

Variations in the arterial pattern of the upper limb are commonly found in literature. Bergman R.A. et al, Rodriguez - Baeza A. et al and Tountas C.H.P. et al have reported variations in the branching pattern of the axillary artery (3, 4, 5). According to Jurjus A. et al the variations and anomalies of the arterial system of the upper limb can be best explained on the basis of embryologic development of the vascular plexuses of the limb buds (6). Senior H. D. and Singer E. have proposed the model of development of the arteries of upper limb. According to them arterial development begins with the appearance of an axial artery followed by other branches. The axial artery forms axillary artery, brachial artery and anterior interosseous artery. The median artery branches from the anterior interosseous artery. The ulnar artery arises from the brachial artery. The axillary artery gives a superficial brachial artery which continues as the radial artery (7, 8). According to Tan C.B. et al the variations in the origin, course and distribution of the axillary artery are not common (9). Jurjus A. R. et al stated that the axillary artery is the axial artery of upper

limb derived from the the lateral branch of the seventh cervical intersegmental artery (10). Hamilton W. J. et al documented that the arterial variations in the upper limb are due to the defects in the embryonic development of the vascular plexus of the upper limb bud. This may be due to arrest at any stage of development, showing regression, retention, or reappearance and may lead to variations in the arterial origins and courses of the major upper limb vessels (11). According to Cavdor et al the axillary artery is having two distinct variations one is the high origin of the superficial brachial artery which emerges from the axillary or brachial artery and continues in the forearm as the radial artery. Second is the superficial brachial artery may or may not be a brachial artery terminating in to radial and ulnar arteries. The incidence of such superficial brachial artery is around 0.1- 3.2% as available in the literature (12). De Garis C.F. has observed the division of the axillary artery into superficial and deep brachial arteries more frequent in black persons (13.4%) than in white persons (4.6%) (13). In the present case the axillary artery divides in to superficial brachial artery and deep brachial artery. The superficial brachial artery has not given any branches during its course in the arm. It terminated in to the radial and ulnar arteries and the arterial arches of the hand were normal. The deep brachial artery giving rise to all branches which are normally given by the axillary artery is very rare and no such case report is available in literature. The deep brachial artery first gave superior thoracic, thoracoacromial, lateral thoracic artery & articular branch to the shoulder joint. It then divided into anterior & posterior division. The anterior division gave rise to anterior circumflex humeral, posterior circumflex humeral and profunda brachii artery. The posterior division i.e. subscapular artery gave rise to circumflex scapular and thoracodorsal artery. According to Charles et al there are 7 types of origins for profunda brachii artery. In Type I the profunda brachii artery is the branch of brachial

artery, Type Ia the profunda brachii artery originates by 2 separate branches, Type Ib the profunda brachii artery originates by 3 separate branches, In Type II the profunda brachii artery arises as a common trunk with superior ulnar collateral artery, In Type III the profunda brachii artery arises at lower border of teres major so can be considered to be arising from axillary or brachial, In Type IV profunda brachii artery is the branch of 3rd part of axillary artery. In Type V profunda brachii artery arises as a common trunk with posterior circumflex humeral. In Type VI profunda brachii artery arises as a common trunk with subscapular and both circumflex humerals from axillary artery and in Type VII profunda brachii artery is absent (14). In the present case the profunda brachii artery arises from the anterior division of the deep brachial artery along with anterior circumflex humeral and posterior circumflex humeral arteries which is rare and not found in literature. The arterial variations documented in the present case are due to the defects in the embryonic development of the vascular plexus of the upper limb bud. This may be due to arrest at any stage of development, showing regression, retention, or reappearance and may lead to variations in the arterial origins and courses of the major upper limb vessels (11). The embryological correlation of the variations of the course and distribution of axillary artery seen in present case may be by the persistence, disappearance, incomplete development fusion and absorption of vessels and the selection of unusual path by primitive vascular plexuses (15). According to Decker G.A. G. the knowledge of such variations are important while operating on chronic dislocation of the shoulder joint. The orthopaedicians must take precautions while taking transverse incision in order to avoid injury to the deep brachial artery and its branches (16). Yoshinaga K. et al in his study on “A rare variation in the branching pattern of the axillary artery.” concluded that an accurate knowledge of the normal and variant arterial pattern of the

human upper extremities is important both for reparative surgery and for angiography (17). According to Samuel L. the presence of deep brachial artery and its branches must be kept in mind during the surgical repair of brachial plexus injury in order to prevent bleeding (18).

CONCLUSION

The arterial variations of the upper limb have been implicated in different clinical situations. The variations in the origin and course of principal arteries are clinically important for surgeons, orthopaedicians and radiologists performing angiographic studies on the upper limb. These variations are compared with the earlier data & it is concluded that variations in branching pattern of axillary artery are a rule rather than exception. Therefore both the normal and abnormal anatomy of the region should be well known for accurate diagnostic interpretation and therapeutic intervention.

Competing Interests:

The authors declare that they have no competing interest.

Authors' contributions:

SPS wrote the case report, performed the literature review & obtained the photograph for the study. RMM performed the literature search and assisted with writing the paper. STS conceived the study and helped to draft the manuscript. All authors have read and approved the final version manuscript.

ACKNOWLEDGEMENT

Authors also acknowledge the immense help received from the scholars whose articles are cited and included in references of this manuscript. The authors are also grateful to authors / editors / publishers of all those articles, journals and books from where the literature for this article has been reviewed and discussed. All the authors are thankful to Dr. Arif A. Faruqui for his support.

Authors are also thankful to Mr. M. Murugan for his help in typing the manuscript.

REFERENCES

1. Standring S. Gray's Anatomy: The Anatomical Basis of Clinical Practice. 40th Ed. 2008. Churchill-Livingstone: Elsevier. ISBN 978-0-443-06684-89.
2. Hollinshead W.H. Anatomy for surgeons in general surgery of upper limb. The back and limbs. A Heber Harper Book, New York, 1958. pp- 290-300.
3. Bergman RA, Thomson SA, Afifi AK, Saadeh FA (1988). Compendium of human anatomic variations. Urban and Schwarzenberg. Baltimore Munich.
4. Rodriguez - Baeza A, Nebot J and Ferreira B et al (1995). An anatomical study and ontogenic explanation of 23 cases with variations in the main pattern of the human brachio-antebrachial arteries. J Anat 187;473-479.
5. Tountas CHP, Bergman RA (1993) Anatomic variations of the upper extremity . Churchill Livingstone, New York pp196-210.
6. Jurjus A, Sfeir R, Bezirdjian R (1986). Unusual variation of the arterial pattern of the human upper limb. Anat Rec 215;82-83.
7. Senior H. D. (1926) A note on the development of the radial artery .Anat Rec 32:220-221.
8. Singer E (1933) Embryological pattern persisting in the arteries of the arm. Anat Rec.55;403-409.
9. Tan C.B., Tan C.K. An unusual course and relations of the human axillary artery. Singapore Med J 1994; 35: 263-264.
10. Jurjus A.R., Correa-De-Aruaujo R., Bohn R.C. Bilateral double axillary artery: embryological basis and clinical implications. Clin Anat 1999; 12: 135-140.
11. Hamilton W.J., Mossman H.W. Cardiovascular system. In: Human

- embryology. 4th ed. Baltimore: Williams and Wilkins, 1972: 271-290.
12. Cavdar S., Zeybek A., Bayramicli M. Rare variation of the axillary artery. *Clin Anat* 2000; 13: 66-68.
 13. De Garis C.F., Swartley W.B. The axillary artery in white and Negro stocks. *Am J Anat* 1928; 41: 353.
 14. Charles, C.M.; Pen, L; Holden, H.F; Miller, R.A. & Elvis, E.B. (1931): The origin of the deep brachial artery in American White & American Negro males. *Anatomical Record*. 50: pp 299-302.
 15. Arey L. B. *Development Anatomy in : Development of the arteries* , 6th edition. Philadelphia: W.B. Saunders Co; 1957. pg. 375-77.
 16. Shoulder joint. In: Decker G.A.G., du plessis D.J. Lee Mc Gregor's *Synopsis of Surgical Anatomy*. 12th ed. Mumbai: K.M. Varghese company, 1986: 451.
 17. Yoshinaga K., Kodama K., Kameta K., Karasawa N., Kanenaka N., Kohno S. & Sukanuma T. A rare variation in the branching pattern of the axillary artery. *Indian J. Plast. Surg.*, 39:222-223, 2006.
 18. Cervicobrachial region. In: Samuel L. Turek's *orthopaedics: Principles and their Applications: Vol 2*. 4th ed. New Delhi: Jaypee brothers, 1989:913.