



A CASE REPORT ON THE VARIANT BICEPS BRACHII SUPPLIED BY MEDIAN NERVE.

Dr. Sharadkumar Pralhad Sawant¹, Dr. Shaguphta T. Shaikh², Dr. Rakhi M. More³,
Dr. Shaheen Rizvi⁴, Dr.S.R.Menon⁵, Dr. R. Uma⁶

^{1,2,3}Department of Anatomy, K. J. Somaiya Medical College, Somaiya Ayurvihar, Eastern Express
Highway, Sion, Mumbai-400 022.

Corresponding author: E-mail : dr.sharadsawant@yahoo.com

ABSTRACT: During routine dissection for the undergraduate first MBBS students on 70 year old male donated embalmed cadaver in the department of Anatomy of K.J.Somaiya Medical College, Sion, Mumbai, INDIA, we observed the variant separate short and long heads of the biceps brachii in the right upper limb. The brachial artery and the median nerve ran in between the two heads throughout their course in the arm upto the cubital fossa. The musculocutaneous nerve was absent and all the muscles of the front of the arm were supplied by the median nerve. The variation was unilateral. The left upper limb of the cadaver was normal. The photographs of the variant separate short and long heads of the biceps brachii supplied by the median nerve in the right upper limb were taken for proper documentation and ready reference. Topographical anatomy and variations of the biceps brachii muscle is clinically important for surgeons, orthopaedicians, radiologists and anaesthetists performing pain management therapies.

Key words: Biceps Brachii Muscle, Two Separate Heads, Median Nerve, Brachial Artery, Surgeons, Orthopaedicians, Radiologists, Anaesthetist, Pain Management Therapy.

INTRODUCTION

Biceps brachii has been stated as one of the muscles that shows frequent anatomical variations [1, 2, 3, 4, 5]. The biceps brachii is the muscle of the anterior compartment of the arm having two heads of origin proximally, a long head originating from the supraglenoid tubercle and glenoid labrum and a short head from the coracoid process of the scapula. Distally these two heads unite to form a common tendon that inserts into the posterior rough part of the radial tuberosity and bicipital aponeurosis which merges with the deep fascia of the forearm [1]. This mode of insertion makes it an efficient and important supinator of the forearm. It is the only flexor of the arm that crosses the shoulder as well as the elbow joint thereby acting on both joints. It is innervated by the musculocutaneous nerve and vascularized by the brachial and the anterior circumflex humeral arteries and brachial vein [1]. Some of its reported anomalies have been manifested as supernumerary fascicles that originate from the coracoid process, tendon of pectoralis major, articular capsule and head of the humerus or from humerus itself [6]. Amongst these variations, the presence of a supernumerary fascicle arising from the shaft of the humerus, which is known as the humeral head of biceps brachii, is known to be the most common anomaly [3, 7, 8]. Multiple supernumerary heads, i.e four to seven heads have also been reported to a lesser extent [1, 3, 4, 5]. High median nerve compression around the elbow joint has been described as resulting from a number of clinical and anatomical entities. The existence of an anomalous muscle in and around the elbow region may cause high median nerve palsy and compression of the brachial artery (5). Further, knowledge of the incidence of humeral head of biceps brachii will facilitate preoperative diagnosis as well as the surgical procedures of the upper limb [5, 9]. The median nerve is normally formed by the union of lateral root of median nerve arising from the lateral cord C5, C6, C7 of brachial plexus and medial root of median nerve arising from the medial cord C8, T1 of brachial plexus anterior to the axillary artery. Some fibres from C7 often leave the lateral root to join the ulnar nerve.

Clinically they are believed to be mainly motor to the flexor carpi ulnaris. The median nerve enters the arm at first lateral to the brachial artery. Near the insertion of the coracobrachialis, it crosses in front of the artery, descending medial to it, upto the cubital fossa, where it is posterior to the bicipital aponeurosis and anterior to the brachialis. It usually enters the forearm between the heads of the pronator teres, crossing to the lateral side of the ulnar artery and separated from it by the deep head of pronator teres [1]. Knowledge of such variations is important for surgeons to perform surgical procedures in the axillary region and arm [10]. Considering the high percentage of anomalies in the formation of median nerve and its paramount clinical importance, the present variations are documented.

Case Report

During routine dissection for the undergraduate first MBBS students on 70 year old male donated embalmed cadaver in the department of Anatomy of K.J.Somaiya Medical College, Sion, Mumbai, INDIA, we observed the variant separate short and long heads of the biceps brachii in the right upper limb. The brachial artery and the median nerve ran in between the two heads throughout their course in the arm upto the cubital fossa. The musculocutaneous nerve was absent and all the muscles of the front of the arm were supplied by the median nerve. The variation was unilateral. The left upper limb of the cadaver was normal. The photographs of the variant separate short and long heads of the biceps brachii supplied by the median nerve in the right upper limb were taken for proper documentation and ready reference.

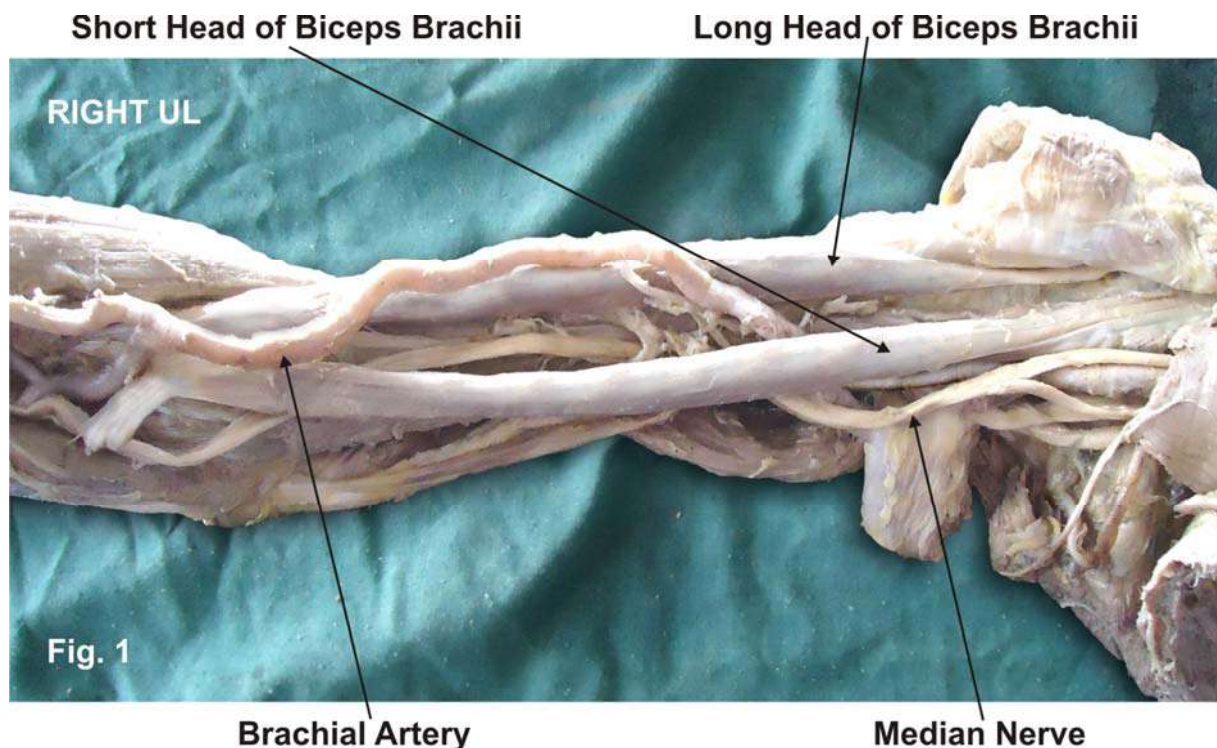


Figure - 1 : The photographic presentation of the two variant short and long heads of biceps brachii muscle supplied by the median nerve and absence of the musculocutaneous nerve.

DISCUSSION

In the present case the short head originated from the tip of the coracoid process and the long head from the supraglenoid tubercle of the scapula. The long head of the biceps brachii muscle got inserted into the radial tuberosity of the radius separately. The short head got inserted into the radial tuberosity and bicipital aponeurosis. The brachial artery and the median nerve ran in between the two heads throughout their course in the arm upto the cubital fossa. The musculocutaneous nerve was absent and all the muscles of the front of the arm were supplied by

the median nerve. Such type of variation is very rare and not found in literature. The communication between the musculocutaneous nerve and the median nerve have been classified in different types by Li Minor and Venieratos and Anagnostopoulou [11, 12]. Li Minor categorized these communications into following five types: In type I, there is no communication between the median nerve and the musculocutaneous nerve, in type II, the fibers of the lateral root of the median nerve pass through the musculocutaneous nerve and join the median nerve in the middle of the arm, whereas in type III, the lateral root fibers of the median nerve pass along the musculocutaneous nerve and after some distance, leave it to form the lateral root of the median nerve. In type IV, the musculocutaneous nerve fibers join the lateral root of the median nerve and after some distance the musculocutaneous nerve arises from the median nerve. In type V, the musculocutaneous nerve is absent and the entire fibers of the musculocutaneous nerve pass through the lateral root and fibers to the muscles supplied by the musculocutaneous nerve branch out directly from the median nerve [11]. In the present case all the muscles of the front of the arm were supplied by the median nerve and the musculocutaneous nerve was absent i.e. Type V of Li Minor's Classification. The knowledge of such variation is important during surgical corrections in the arm as well as in diagnosing the nerve impairments. Furthermore, it has been mentioned that any variant nerve with an abnormal origin, course and distribution is prone to accidental injuries [13]. The variant separate short and long heads of the biceps brachii which were observed in this case is very rare and not reported in literature. The biceps brachii is known for its powerful elbow flexion and supination of the forearm. It can be argued that the presence of two separate heads of biceps brachii muscle increases its kinematics. Therefore, from anatomical standpoint it can be presumed that the presence of two separate heads may increase the power of flexion and supination of the forearm [14]. The two separate heads of the biceps brachii muscle reported in this case may be explained on the basis of the embryogenesis of the muscles of the arm. During development, the limb bud mesenchyme of the lateral plate differentiates into intrinsic muscles of the upper limb. A single muscle mass is formed by fusion of the muscle primordia within the different layers of the arm at certain stages of development; thereafter, some muscle primordia disappears through cell death. The morphological variations of the biceps brachii muscle may be due to failure of muscle primordia to disappear during embryological development [15]. The absence of the musculocutaneous nerve and the median nerve taking over supply all the muscle of the front of arm documented in present case may be attributed to random factors influencing the mechanism of formation of limb muscles and the peripheral nerves during embryonic life. Significant variations in nerve patterns may be a result of altered signaling between mesenchymal cells and neuronal growth cones [16] or circulatory factors at the time of fusion of brachial plexus cords [17]. Iwata believed that the human brachial plexus appears as a single radicular cone in the upper limb bud, which divides longitudinally into ventral and the dorsal segments [18]. The ventral segments give roots to the median and the ulnar nerves with musculocutaneous nerve arising from the median nerve. There may be a possibility of failure of the differentiation as a cause for some of the fibers taking an aberrant course as a communicating branch. Chiarapattanakom et al. [19] are of the opinion that the limb muscles develop from the mesenchyme of local origin, while axons of spinal nerves grow distally to reach the muscles and the skin. They blamed the lack of coordination between the formation of the limb muscles and their innervation for appearance of a communicating branch. Studies of comparative anatomy have observed the existence of such connections in monkeys and in some apes; the connections may represent the primitive nerve supply of the anterior arm muscles (20). Chauhan et al strongly recommend the consideration of the phylogeny and the development of the nerves of the upper limb for the interpretation of the nerve anomalies of the arm [21]. Considering the communication between the musculocutaneous and the median nerve as a remnant from the phylogenetic or comparative anatomical point of view and that the ontogeny recapitulates the phylogeny, they feel that the variations seen are the result of the developmental anomaly.

CLINICAL SIGNIFICANCE

The anatomical variation described here has practical implications, since injury to the median nerve in the axilla or arm would, in this case, have caused unexpected paresis or paralysis of the flexor musculature of the elbow and hypoaesthesia of the lateral surface of the forearm, in addition to the classical signs that are already well known. Injury to the median nerve could occur in cases of open or closed trauma to the arm, such as bullet and blade wounds or during surgeries on the axilla or arm. The median nerve and its roots are close to the axillary vein, which is used as the most cranial limit for axillary lymph node dissection, a procedure used in treating certain tumors, such as breast carcinoma and melanoma. If the dissection

extends more cranially than normal, injury to the median nerve (or to its medial root) may occur, with consequent dysfunction of the flexor musculature of the elbow if the anatomical variation described here is present. It would not be unlikely for such accidents to occur even with the most eminent surgeons, considering that the classical concept is that the median nerve does not give rise to branches in the arm (22). As the brachial artery and median nerve runs in between the two separate heads of the biceps brachii muscle throughout their course in the arm, there is high risk of neurovascular entrapment.

CONCLUSION

The presence of such type of variations are clinically important for surgeons, orthopaedicians, radiologists and anaesthetists performing pain management therapies on the upper limb & it is concluded that variations in branching pattern of cords of brachial plexus are a rule rather than exception.

Competing interests

The authors declare that they have no competing interests.

Authors' contributions

SPS wrote the case report, performed the literature review & obtained the photograph for the study. RMM, UR performed the literature search, SR assisted with writing the paper. STS conceived the study and SRM helped to draft the manuscript. All authors have read and approved the final version of the manuscript.

Acknowledgement

All the authors are thankful to Dr. Arif A. Faruqui and Dr. S. D. Lele Prof. and HOD, Dept. of Anatomy, KJSMC for their support. We are also thankful to Mr. M. Murugan for his help. Authors also acknowledge the immense help received from the scholars whose articles are cited and included in references of this manuscript. The authors are also grateful to authors / editors / publishers of all those articles, journals and books from where the literature for this article has been reviewed and discussed.

REFERENCES

- [1] Williams P.L., Dyson M, Standring S, Ellis H, Healy JC, Johnson D - Gray's Anatomy. 39th ed. London ELBS with Churchill Livingstone, 2005: 614-615, 853-5, 803-4.
- [2] Testut, L. Tretado. De –Anatomica Humana. 1st ed. Barcelona: Salvat. 1902: 1022.
- [3] Asvat, R.; Candler, P. & Sarmiento, E. E. High incidence of the third head of biceps brachii in South African populations. *J. Anat.* 1993, 182:101-4.
- [4] Nakatani, T.; Tanaka, S. & Mizukami, S. Bilateral four headed biceps brachii muscles: the median nerve and brachial artery passing through a tunnel formed by a muscle slip from the accessory head. *Clin. Anat.*, 1998;11:209-12.
- [5] Nayak, S. R.; Ashwin, K.; Madhan, K. S. J.; Latha, V. P.; Vasudha, S. & Merin, M. T. Four-headed biceps and triceps brachii muscles with neurovascular variation. *Anat. Sci. Intl.*, 83:107-11, 2008.
- [6] Sargon, M. F.; Tuncali, D. & Celik, H. H. An unusual origin for the supernumerary head of biceps brachii muscle. *Clin. Anat.*, 9:160-2, 1996.
- [7] Khaledpour, C. Anomalies of the biceps muscle of the arm. *Anat. Anz.*, 158:79-85, 1985.
- [8] Kopuz, C.; Sancack, B. & Ozbenli, S. On the incidence of the third head of biceps brachii in Turkish neonates and adults. *Kaibogaku Zasshi.* 1999; 74:301-5.
- [9] Rai, R.; Ranade, A. V.; Prabhu, L. V. & Prakash, M. M. P. Third head of Biceps brachii: A study in Indian population. *Singapore Med. J.*, 48:929-31, 2007.
- [10] Uysal II, Seker M, Karabulut AK, Buyukmumcu M, Ziylan T. Brachial plexus variation in human fetuses. *Neurosurgery* 2003; 53: 676-84; discussion 684.
- [11] Le Minor JM. A rare variant of the median and musculocutaneous nerves in man. *Archives Anatomy Histology Embryology* 1992; 73: 33-42.
- [12] Venieratos D and Anagnastopoulou S classification of communication between the musculocutaneous and median nerves. *Clinical Anatomy.* 1998; 11: 327-331.

- [13] Roberts, W. H. Anomalous course of the median nerve medial to the trochlea and anterior to the medial epicondyle of the humans. *Anat. Anz.*, 174:309-11, 1992.
- [14] Kumar, H.; Das, S. & Rath, G. An anatomical insight into the third head of biceps brachii muscle. *Bratisl. Lek. Listy.*, 109:76-8, 2008.
- [15] Lewis WH. The development of the muscular system. In: Keibel F, Mall FP, ed. *Manual of Embryology*. Vol 2. Philadelphia: JB Lippincott, 1910: 455-522.
- [16] Abhaya, A., Bhardwaj, R., Prakash, R. Dual origin of musculocutaneous nerve. *Journal of Anatomical Society of India*, 2003, vol. 52, n. 1, p. 94.
- [17] Kosugi, K. Mortia, T., Yamashita, H. Branching pattern of the musculocutaneous nerve. 1. Cases possessing normal biceps brachii. *Jikeikai Medical Journal*, 1986, vol. 33, p. 63-71.
- [18] Iwata, H. Studies on the development of the brachial plexus in Japanese embryo. *Republic Department Anatomy Mie Prefect University School of Medicine*, 1960, vol. 13, p. 129-144.
- [19] Chiarapattanakom, P., Leechavengvons, S., Witoonchart, K., Uerpairojkit, C., Thuvasethakul, P. Anatomy and internal topography of the musculocutaneous nerve: The nerves to the biceps and brachials muscle. *Journal of Hand Surgery*, 1998, vol. 23A, p. 250-255.
- [20] Miller, RA. Comparative studies upon the morphology and distribution of the brachial plexus. *American Journal of Anatomy*, 1934, vol. 54, n. 1, p. 143-166.
- [21] Chauhan, R., Roy, TS. Communication between the median and musculocutaneous nerve: A case report. *Journal of Anatomical Society of India*, 2002, vol. 51, n. 1, p. 72-75.
- [22] Fregnani, JHTG., Macéa, MIM., Pereira, CSB., Barros, MD., Macéa, JR. Absence of the musculocutaneous nerve: a rare anatomical variation with possible clinical-surgical implications. *Sao Paulo Medical Journal*, 2008, vol. 126, n. 5, p. 288-90.