



THE AXILLARY NERVE GIVING MOTOR BRANCH TO THE LONG HEAD OF THE TRICEPS MUSCLE – A CASE REPORT

Dr. Sharadkumar Pralhad Sawant¹, Dr. Shaguphta T. Shaikh², Dr. Rakhi M. More³

^{1,2,3}Department of Anatomy, K. J. Somaiya Medical College, Somaiya Ayurvihar, Eastern Express Highway, Sion, Mumbai-400 022.

Corresponding author: E-mail : dr.sharadsawant@yahoo.com

ABSTRACT: During the routine dissection for the undergraduate first M.B.B.S. student, on the right upper limb of a 70 year old donated embalmed male cadaver in the department of Anatomy, K.J.Somaiya Medical College, Sion, Mumbai, India, we observed the axillary nerve giving the motor branch to the long head of the triceps muscle. The axillary nerve winds backward, in company with the posterior humeral circumflex artery, through a quadrilateral space bounded above by the teres minor, below by the teres major, medially by the long head of the triceps brachii, and laterally by the surgical neck of the humerus, and divides into an anterior and a posterior branch. The anterior branch (upper branch) winds around the surgical neck of the humerus, beneath the deltoid, with the posterior humeral circumflex vessels. It continues as far as the anterior border of the deltoid to provide motor innervations. The posterior branch (lower branch) supplies the teres minor, the posterior part of the deltoid and the long head of the triceps muscle. The finding was noted after thorough and meticulous dissection of the upper limbs of both sides. The left side of the cadaver was normal and the long head of the triceps muscle was supplied by the radial nerve. There were no associated variations documented in the arterial pattern in the same cadaver. Photographs of the variation in the nerve supply of the long head of the triceps brachii muscle were taken for proper documentation and ready reference. The variation in the nerve supply of the long head of the triceps brachii muscle is clinically important for surgeons, orthopaedicians and anaesthetist performing pain management therapies on the upper limb. In the present case the motor branch of the long head of the triceps brachii muscle may arise from the axillary nerve hence while examining patients with traumatic injury involving the axillary nerve, it is important to look for the paralysis of the long head of the triceps brachii muscle. The paralysis of the long head of the triceps brachii muscle is the sign of a severe axillary nerve lesion requiring early nerve repair.

Keywords: Axillary Nerve, Long Head of Triceps Brachii Muscle, Variations, Radial Nerve, Paralysis, Early Nerve Repair, Surgeons, Orthopaedicians, Anaesthetist, Pain Management Therapy.

INTRODUCTION

The axillary nerve or the circumflex nerve is a terminal terminal branch of the posterior cord of the brachial plexus at the level of the axilla and carries nerve fibers from C5 and C6. The axillary nerve travels through the quadrangular space with the posterior circumflex humeral artery and vein. The axillary nerve supplies three muscles; deltoid - a muscle of the shoulder, teres minor - one of the rotator cuff muscles and the long head of the triceps brachii - an elbow extensor [1]. The axillary nerve also carries sensory information from the shoulder joint, as well as the skin covering the inferior region of the deltoid muscle - the "regimental badge" area which is innervated by the superior lateral cutaneous branch of the axillary nerve. The posterior cord splits inferior to the glenohumeral joint giving rise to the axillary nerve which wraps around the anatomical neck of the humerus, and the radial nerve which wraps around the humerus anteriorly and descends along its lateral border. It lies at first behind the axillary artery, and in front of the subscapularis, and passes downward to the lower border of that muscle.

It then winds backward, in company with the posterior humeral circumflex artery, through a quadrilateral space bounded above by the teres minor, below by the teres major, medially by the long head of the triceps brachii, and laterally by the surgical neck of the humerus, and divides into an anterior, a posterior, and a collateral branch to the long head of the triceps brachii branch. The anterior branch (upper branch) winds around the surgical neck of the humerus, beneath the deltoid, with the posterior humeral circumflex vessels. It continues as far as the anterior border of the deltoid to provide motor innervation. The anterior branch also gives off a few small cutaneous branches, which pierce the muscle and supply in the overlying skin. The posterior branch (lower branch) supplies the teres minor and the posterior part of the deltoid. The posterior branch pierces the deep fascia and continues as the superior (or upper) lateral cutaneous nerve of arm, which sweeps around the posterior border of the deltoid and supplies the skin over the lower two-thirds of the posterior part of this muscle, as well as that covering the long head of the triceps brachii [1]. The trunk of the axillary nerve gives off an articular filament which enters the shoulder-joint below the subscapularis. The causes of injury to the axillary nerve are traumatic due to shoulder dislocation, proximal humeral fracture, brachial plexus injury, blunt trauma to deltoid, the iatrogenic due to surgery, Quadrangular Space Syndrome, Parsonage-Turner Syndrome, brachial neuritis, space occupying lesions [2].

Case report

During the routine dissection for the undergraduate first M.B.B.S. student, on the right upper limb of a 70 year old donated embalmed male cadaver in the department of Anatomy, K.J.Somaiya Medical College, Sion, Mumbai, India, we observed the axillary nerve giving the motor branch to the long head of the triceps muscle. The axillary nerve winds backward, in company with the posterior humeral circumflex artery, through a quadrilateral space bounded above by the teres minor, below by the teres major, medially by the long head of the triceps brachii, and laterally by the surgical neck of the humerus, and divides into an anterior and a posterior branch. The anterior branch (upper branch) winds around the surgical neck of the humerus, beneath the deltoid, with the posterior humeral circumflex vessels. It continues as far as the anterior border of the deltoid to provide motor innervations. The posterior branch (lower branch) supplies the teres minor, the posterior part of the deltoid and the long head of the triceps muscle. The finding was noted after thorough and meticulous dissection of the upper limbs of both sides. The left side of the cadaver was normal and the long head of the triceps muscle was supplied by the radial nerve. There were no associated variations documented in the arterial pattern in the same cadaver. Photographs of the variation in the nerve supply of the long head of the triceps brachii muscle were taken for proper documentation and ready reference.

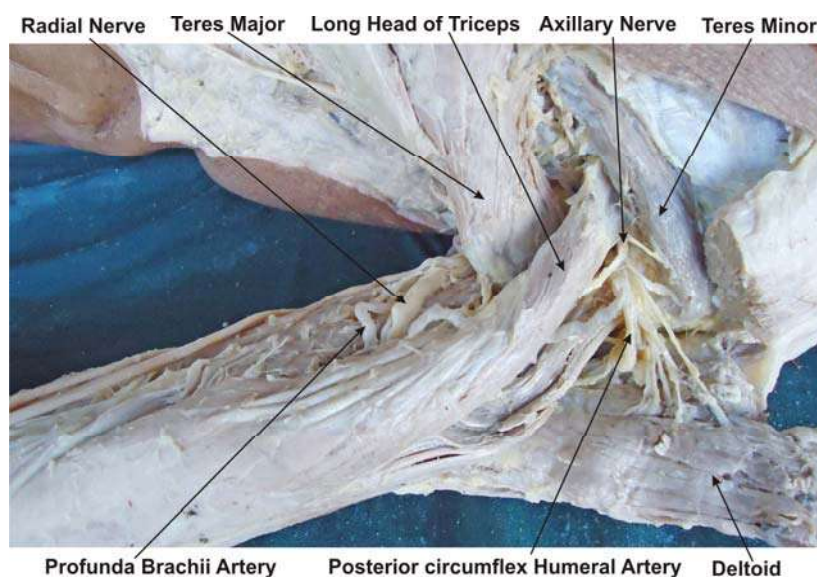


Figure : The photographic presentation of the axillary nerve giving the motor branch to the long head of the triceps muscle.

DISCUSSION

The axillary nerve giving branch to the long head of triceps muscle is rare. The posterior division of the axillary nerve is more variant in course and distribution than the anterior division [3]. In the present case the posterior branch of the axillary nerve gave the motor branch to the long head of the triceps muscle. The long head of the triceps brachii originates on the infraglenoid tubercle of the scapula and is inserted into the upper surface of the olecranon process of the ulna [1]. The actions of the long head of the triceps brachii include extension and adduction of the shoulder and extension of the elbow. Conditions that can afflict the long head of the triceps brachii include tears, strains, myopathy, atrophy, infectious myositis, neuromuscular diseases, lacerations and contusions [2]. The long head of triceps brachii muscle is used as a free functioning muscle graft [4]. In case of massive tear of the rotator cuff muscle the long head of triceps is used as interposition muscle flap for the surgical correction of the rotator cuff muscles [5]. The triceps muscle flap is commonly used to release the axillary contracture [6]. The triceps musculocutaneous flap is used for chest-wall defects [7]. The axillary nerve may be injured in anterior-inferior dislocations of the shoulder joint, compression of the axilla with a crutch or fracture of the surgical neck of the humerus. Injury to the nerve results in the paralysis of the teres minor muscle and the deltoid muscle, resulting in loss of 15° – 90° abduction of arm, weak flexion, extension, and rotation of shoulder. Paralysis of deltoid & teres minor results in flat shoulder deformity. Loss of sensation in the skin over a small part of the lateral upper arm [8]. The knowledge of the variations in the nerve supply of long head of the triceps muscle is important in surgery of restoring the motor function of the deltoid muscle in patients with complete C5 - C6 root injury (upper brachial plexus injury) by transferring the nerve to the long head of the triceps to the anterior branch of the axillary nerve through a posterior approach [9]. In the present case the motor branch of the long head of the triceps brachii muscle may arise from the axillary nerve hence while examining patients with traumatic injury involving the axillary nerve, it is important to look for the paralysis of the long head of the triceps brachii muscle. The paralysis of the long head of the triceps brachii muscle is the sign of a severe axillary nerve lesion requiring early nerve repair [10, 11, 12]. The recovery of muscle strength, range of movement and shoulder function were satisfactory when surgery was performed within four months of the injury. Early exploration and nerve grafting can lead to a good functional recovery, but thorough exploration and careful repair of the nerve is essential [13, 14, 15, 16, 17]. The axillary nerve is susceptible to injury at its origin from the posterior cord, in the quadrangular space and subfascial surface of the deltoid muscle. Injury to the axillary nerve can occur due to glenohumeral dislocation, blunt trauma on the anterolateral deltoid, quadrangular space syndrome and Iatrogenic. Electrophysiologic testing (EMG and nerve conduction studies) should be performed 3 weeks after injury as it usually takes several weeks for muscles to show electrical evidence of acute denervation after nerve damage. EMG and nerve conduction studies provide important information for diagnosis, prognosis and treatment indications. Electrophysiologic testing may help delineate pure axillary nerve injury from injury to the brachial plexus [18]. The injury to the axillary nerve is surgically corrected by nerve repair, neurolysis, nerve grafting, nerve transfer. The nerve transfer i.e. neurotisation is performed by transferring branch of radial nerve into motor branch of axillary nerve. The axillary nerve is primarily motor and travels only a short distance from its origin to its muscle insertion, thus has a good prognosis for recovery after surgical repair and grafting [19].

Physiotherapy in axillary nerve injury

Along with common points of management of any peripheral nerve injury the treatment of axillary nerve is the progressive strengthening programme for the affected muscle. The passive abduction of affected shoulder along with all other movements, lateral rotation is a very important movement to be restored during nerve injury and elevation can be restored if the shoulder joint and is mobile by teaching compensatory movements. In supine lying with elbow flexed and shoulder externally rotated, elevation can be achieved by using long head of biceps with that of clavicular head of pectoralis major and serratus anterior. As the patient's ability improves progression can be made by gradually performing the movement against gravity position using tilting table. As re- innervation occurs, the trick movements disappear since deltoid regains strength.

Developmental Basis

The myogenic cells develops into two muscle masses during the fifth week of intrauterine life. One is the precursor of the flexor muscles the other is the precursor of the extensor muscles. These common muscle masses then split into anatomically recognizable precursors of the definitive muscles of the limb [21]. The long head head of triceps muscle is derived from the dorsal muscle mass. The axillary nerve is the branch of the posterior cord of the brachial plexus. The branches of the posterior cord of the brachial plexus supplies the muscles derived from the dorsal muscle mass [22].

Clinical significance

The anatomical variation described here has practical implications, since injury to the axillary nerve in the axilla or arm would, in this case, have caused unexpected paresis or paralysis of the long head of the triceps muscle. The paralysis of the long head of triceps muscle can occur due to trauma to the axillary nerve because of dislocation of the shoulder joint and fracture of the surgical neck of the humerus and neuralgia amyotrophy.

CONCLUSION

The variations in the nerve supply of long head of the triceps muscle is clinically important for surgeons, orthopaedicians and anaesthetist performing pain management therapies on the upper limb. It is concluded that this unusual innervation of axillary nerve might complicate surgical repair.

Competing interests

The authors declare that they have no competing interests.

Authors' contributions

SPS wrote the case report, performed the literature review & obtained the photograph for the study. RMM performed the literature search and assisted with writing the paper. STS conceived the study and helped to draft the manuscript. All authors have read and approved the final version manuscript.

ACKNOWLEDGEMENT

All the authors wish to convey our sincere thanks to Dr. Arif A. Faruqi for his valuable help, support and inspiration. Authors also acknowledge the immense help received from the scholars whose articles are cited and included in references of this manuscript. The authors are also grateful to authors / editors / publishers of all those articles, journals and books from where the literature for this article has been reviewed and discussed.

REFERENCES

- [1] Standring S, Ellis H, Healy JC, Johnson D et al. Gray's Anatomy. In: General organisation and surface anatomy of the upper limb. 39th ed. Philadelphia Elsevier Churchill Livingstone, 2005: 847-848.
- [2] Narakas AO. Lesions of the axillary nerve and associated lesions of the suprascapular nerve. *Rev Med Suisse Romande* 1989;109:545-56.
- [3] Ball CM, Steger T, Galatz LM, Yamaguchi K, The posterior branch of the axillary nerve : an anatomic study. *J Bone Joint Surg.* 2003, 85; 1497- 1501.
- [4] Lim AYT, Pereira BP, Kumar VP. The long head of the triceps brachii as a free functioning muscle transfer. *Plast Reconstr Surg.* 2001;107:1746–1752.
- [5] Sundine MJ, Malkani AL. The use of the long head of triceps interposition muscle flap for treatment of massive rotator cuff tears. *Plast Reconstr Surg.* 2002;110:1266–1272.

- [6] Hallock GG. The triceps muscle flap for axillary contracture release. *Ann Plast Surg.* 1993;30:359–362.
- [7] Hartrampf CR, Elliot LF, Feldman S. A triceps musculocutaneous flap for chest-wall defects. *J Reconstr Microsurg.* 1990;86:502–509.
- [8] de Se`ze MP, Rezzouk J, de Se`ze M, Uzel M, Lavignolle B, Midy D, Durandea A. "Does the motor branch of the long head of the triceps brachii arise from the radial nerve?", 2004, *Surg Radiol Anat* 26 (6): 459–461.
- [9] Witoonchart K, Leechavengvongs S, Uerpairojkit C, Thuvasethakul P, Wongnopsuwan V. Nerve transfer to deltoid muscle using the nerve to the long head of the triceps, part I: an anatomic feasibility study. *Plastic surgery.* 2001; 6:123–133.
- [10] de Sèze MP, Rezzouk J, de Sèze M, Uzel M, Lavignolle B, Midy D, Durandea A. Does the motor branch of the long head of the triceps brachii arise from the radial nerve? An anatomic and electromyographic study. Source Laboratoire d'anatomie UFR2, Faculté de Médecine de Bordeaux 2, 146 rue Léo-Saignat, 33076 cedex Bordeaux, France. madeseze@club-internet.fr
- [11] Narakas AO. Neurotization in the treatment of brachial plexus injuries. In: Gelberman RH editors. *Operative nerve repair and reconstruction.* Philadelphia: JB Lippincott; 1991;p. 1329–1358.
- [12] Perlmutter, Gary S. MD. Axillary Nerve Injury. *Clinical Orthopaedics & Related Research.* (368):28-36, November 1999.
- [13] Yoji Mikami, Akira Nagano, Naoyuki Ochiai, Seizo Yamamoto, From The University Of Tokyo, Japan, Results Of Nerve Grafting For Injuries Of The axillary and suprascapular nerves , *J Bone Joint Surg [Br]* VOL. 79-B, NO. 4, 1997;79-B:527-31.
- [14] Ochiai N, Nagano A, Okinaga S, Murashima R, Tachibana S.Brachial plexus injuries: surgical treatment of combined injuries of the axillary and suprascapular nerves. *J Jpn Soc Surg Hand* 1988;5: 151-5.
- [15] Alnot JY. Traumatic brachial plexus palsy in the adult: retro- and infraclavicular lesions. *Clin Orthop* 1988;237:9-16.
- [16] Burge P, Rushworth G, Watson N. Patterns of injury to the terminal branches of the brachial plexus: the place for early exploration. *J Bone Joint Surg [Br]* 1985;67-B:630-4.
- [17] Coene LN, Narakas AO. Operative management of lesions of the axillary nerve, isolated or combined with other nerve lesions. *Clin Neurol Neurosurg* 1992;94:64-6.
- [18] Aszmann OC, Dellon AL. The internal topography of the axillary nerve (an anatomic and histologic study as it relates to microsurgery). *J Reconstr Microsurg.* 1996;12:359–363.
- [19] Samardžić M, Rasulić L, Grujičić D, Miličić B. Results of nerve transfers to the musculocutaneous and axillary nerves. *Neurosurgery.* 2000;46:93–103.
- [20] Zhao X, Hung LK, Zang GM, Lao J. Applied anatomy of the axillary nerve for selective neurotization of the deltoid muscle. *Clin Orthop.* 2001;390:244–251
- [21] Larsen WJ. *Human embryology.* 3rd ed. Churchill Livingstone; 2001. p. 324.
- [22] Carlson BM. *Human embryology and developmental biology.* 3rd ed. C.V. Mosby; 2004. p. 224.