

## **“The muscular variation on the dorsum of the foot observed during routine Dissection in Medical College in Mumbai , India.”**

Dr. Sharadkumar Pralhad Sawant<sup>1</sup>, Dr. Shaguphta T. Shaikh<sup>2</sup>, Dr. Rakhi M. More<sup>3</sup>

<sup>1,2,3</sup>Department of Anatomy, K. J. Somaiya Medical College,

Eastern Express Highway, Sion, Mumbai-400 022.

**Corresponding author :** Dr.Sharadkumar Sawant E-mail: dr.sharadsawant@yahoo.com

---

### **Abstract**

Peroneus tertius is often appears to be part of extensor digitorum longus, and might be described as its ‘fifth tendon’. The muscle fibres operating on this tendon arise from the distal third or more of the medial surface of the fibula, the adjoining anterior surface of the interosseous membrane, and the anterior crural intermuscular septum. During routine dissection for the first MBBS students, we observed that the peroneus tertius was absent on the dorsum of the left lower limb of a 70 years old, donated embalmed male cadaver in the Department of Anatomy, K.J.Somaiya Medical College,Sion,Mumbai,India. The photographs of the dorsum of the foot were taken for proper documentation and for ready reference. The absence of the peroneus tertius is very rare and not found in literature. The absent peroneus tertius is an interesting finding, which could be clinically important for Anatomists, Anthropologists, Surgeons and Orthopedic surgeons.

**Keywords:** Peroneus Tertius, Extensor Digitorum Longus, Dorsiflexion and Eversion of Foot .

---

### **Introduction:**

Peroneus tertius is often appears to be part of extensor digitorum longus, and might be described as its ‘fifth tendon’. The muscle fibres arise from the lower part of the medial surface of the shaft of the fibula, the adjoining anterior surface of the interosseous membrane, and the anterior crural intermuscular septum (1). During the swing phase of gait electromyographic studies show that peroneus tertius acts with extensor digitorum longus and tibialis anterior to produce dorsiflexion and eversion of the foot. This levels the foot and helps the toes to clear the ground, an action that improves the economy of bipedal walking. The peroneus tertius cannot be tested in isolation, but its tendon can sometimes be seen when the foot is dorsiflexed against resistance (1). This muscle is seldom found in other primates, a fact that has linked its function to efficient terrestrial bipedalism (1,2,3). Although closely associated with the extensor digitorum longus, the peroneus tertius has been considered the migrated part of the extensor digitorum brevis of the little

toe (4). The presence of peroneus tertius is important for dorsiflexion and extension of the foot in swing phase of the gait (1). The insertion of the peroneus tertius might play an important role in the causation of torsional stresses as observed in Jones fractures and stress fractures (5). Foot surgeons might use the peroneus tertius muscle flap for transposition and also for correcting any laxity in the ankle joint (6,7). Thus, the presence or absence of peroneus tertius may be important from the academic and clinical point of view.

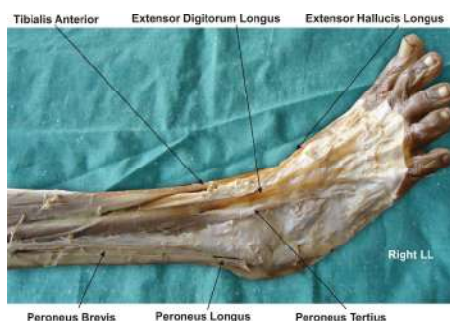
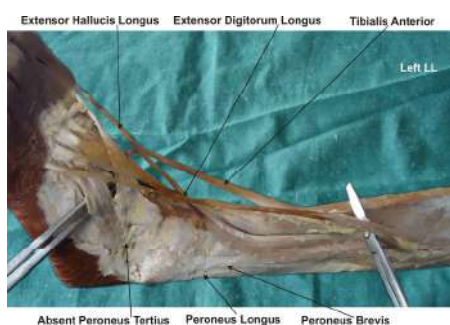### **Materials & Methods:**

Exposure of the dorsum of the foot was achieved following classical incisions and dissection procedures on a donated embalmed 70 years old male cadaver in the department of Anatomy at K.J. Somaiya Medical College, Sion, Mumbai. All the extensor tendons on the dorsum of the foot were dissected meticulously. The tendon of extensor digitorum longus going to the little toe was also observed carefully to note any thickening. The lower part of the medial surface of the fibula was also dissected properly. The photographs of

the dorsum of the foot were taken for proper documentation and for ready reference.

### Observations:

All the extensor tendons on the dorsum of the foot were observed. All the tendons of the extensor digitorum longus were observed. There was no thickening seen on the tendon of extensor digitorum longus going to the little toe. There was no signs of any muscle fibres arising from the lower part of the medial surface of the shaft of the fibula. There was no evidence of presence of peroneus tertius on the dorsum of the left foot.



### Discussion:

Recently the peroneus tertius is called as fibularis tertius (8). The peroneus tertius normally originates from the medial surface of the distal third of the fibula (1,3). In the present study, the peroneus tertius was absent and there was no thickening of the extensor digitorum longus muscle. The peroneus tertius muscle is absent in many primates with much variation in the humans. Interestingly, in the animal kingdom, the peroneus tertius muscle is found occasionally in the apes and the gorillas (9). The variability of the muscle suggests that the

absence of peroneus tertius muscle may be a primitive condition for anthropoids (10). The presence of peroneus tertius is an evident of evolution (9).

The peroneus tertius tendon can be used for transplant surgeries. In foot drop, the tibialis posterior tendon manipulation might be required. There are past reports of the tibialis posterior tendon being transferred to the anterior compartment and anastomosed to the peroneus tertius tendon (11). The peroneus tertius causes dorsiflexion and eversion of the foot during the swing phase of gait and it is important that the toes be lifted from the ground to assist in bipedal walking (4). The attachment of the peroneus tertius to the fifth metatarsal might define its role in providing proper support to the outer aspect of the sole of the foot. We, as anatomists believe that in the absence of the peroneus tertius as seen in the present study, the support along the lateral border would be weakened. It should not be forgotten that both Jones' fractures and stress fractures involve the proximal fifth metatarsal and the insertion of the peroneus tertius might play an important role in imposing torsional stress (5). The individuals with out peroneus tertius would be less vulnerable to such stress fractures. The peroneus tertius may be considered as an accessory muscle for eversion and dorsiflexion. Witvrouw et al have noted that eversion or dorsiflexion may not be affected in case of absent peroneus tertius (12). The absent peroneus tertius may misguide foot surgeons performing graft operations and transplant surgeries. Hence radiological imaging techniques must be performed to confirm the existence of the peroneus tertius muscle before planning any operations on the foot.

### Conclusion:

The peroneus tertius may be considered as an accessory muscle for eversion and dorsiflexion. The absent peroneus tertius may not affect the eversion or dorsiflexion. The absence of Peroneus tertius may be asymptomatic and hence radiological imaging techniques must be performed to confirm the

existence of the peroneus tertius muscle before planning graft operations and transplant surgeries on the foot.

### **Acknowledgement:**

All the authors wish to convey our sincere thanks to Dr. Arif A. Faruqui for his valuable help, support and inspiration.

### **References:**

1. Williams P. L., Bannister L. H., Berry M. M., Collins P., Dyson M., Dussek J. E., Ferguson M. W. J. (eds), Gray's Anatomy. The anatomical basis of medicine and surgery, 39<sup>th</sup> edition, Churchill Livingstone, Edinburgh, 2005, 1497 – 1498.
2. Snell R. S., Clinical anatomy for medical students, 7th edition, Lippincott Williams & Wilkins, Baltimore, 2000, 561–562.
3. Sinnatamby C. S., Last's Anatomy. Regional and Applied, 10th edition, Churchill Livingstone, Edinburgh, 2000, 148.
4. Joshi S. D., Joshi S. S., Athavale S. A., Morphology of peroneus tertius muscle, Clin Anat, 2006, 19(7):611–614.
5. Vertullo C. J., Glisson R. R., Nunley J. A., Torsional strains in the proximal fifth metatarsal: implications for Jones and stress fracture management, Foot Ankle Int, 2004, 25(9):650–656.
6. Arnold P. G., Yugueros P., Hanssen A. D., Muscle flaps in osteomyelitis of the lower extremity: a 20-year account, Plast Reconstr Surg, 1999, 104(1):107–110.
7. Karlsson J., Wiger P., Longitudinal split of the peroneus brevis tendon and lateral ankle instability: treatment of concomitant lesions, J Athl Train, 2002, 37(4):463–466.
8. Rourke K., Dafydd H., Parkin I. G., Fibularis tertius: revisiting the anatomy, Clin Anat, 2007, 20(8):946–949.
9. Kimura K., Takashashi Y., The peroneus tertius muscle in the crab-eating monkey (*Macaca fascicularis*), Okajimas Folia Anat Jpn, 1985, 62(3–4):173–185.
10. Jungers W. L., Meldrum D. J., Stern J. T. Jr., The functional and evolutionary significance of the human peroneus tertius muscle, J Hum Evol, 1993, 25:377–386.
11. Ozkan T., Tuncer S., Ozturk K., Aydin A., Ozkan S., Tibialis posterior tendon transfer for persistent drop foot after peroneal nerve repair, J Reconstr Microsurg, 2009, 25(3):157–164.
12. Witvrouw E., Borre K. V., Willems T. M., Huysmans J., Broos E., De Clercq D., The significance of peroneus tertius muscle in ankle injuries: a prospective study, Am J Sports Med, 2006, 34(7):1159–1163.

**Source of support: Nil; Conflict of Interest: Nil**

**Date of submission: 19 September 2012**

**Date of Provisional Acceptance: 4 October 2012**

**Date of Peer review approval: 28 October 2012**

**Date of final drafting: 27 November 2012**

**Date of Publication: 2 December 2012**