



Case Report

Variant Nerve Supply of the Third Head of Biceps Brachii Muscle

Sharadkumar Pralhad Sawant ^{**@}, Shaguphta T. Shaikh ^{*}, Rakhi M. More ^{*}

^{**} Associate Professor, ^{*} Assistant Professor

Department of Anatomy, K. J. Somaiya Medical College, Somaiya Ayurvihar, Sion, Mumbai-400 022

[@]Correspondence Email: dr.sharadsawant@yahoo.com

Received: 03/10/2012

Revised: 15/11/2012

Accepted: 17/11/2012

ABSTRACT

During routine dissection of undergraduate First MBBS students a variation was found in the right upper limb of a 70 year old male donated embalmed cadaver in the department of Anatomy of K.J.Somaiya Medical College, Sion, Mumbai, India. The third head of biceps brachii was supplied by the median nerve. The third head was taking origin from the anterolateral surface of the shaft of the humerus. The third head joined with the other two heads and form a common tendon which got inserted into the radial tuberosity of the radius and bicipital aponeurosis. The musculocutaneous nerve was absent and all the muscles of the front of the arm were supplied by median nerve. The third head was also supplied by the median nerve. There was no associated arterial variation seen in the specimen. The variation was unilateral and the left upper limb of the cadaver was normal. The photographs of the variations were taken for proper documentation and ready reference. Topographical Anatomy and variations of the biceps brachii muscle is clinically important for surgeon, Orthopaedician, Radiologist and Anaesthetist performing pain management therapies.

Key Words: Biceps Brachii Muscle, Third Head, Median Nerve, Surgeons, Orthopaedicians, Radiologists, Anaesthetist, Pain Management Therapy.

INTRODUCTION

The biceps brachii is the muscle of the anterior compartment of the arm having two heads of origin proximally, a long head originating from the supraglenoid tubercle and glenoid labrum and a short head from the coracoid process of the scapula. Distally these two heads unite to form a common tendon that inserts into the posterior rough part of the radial tuberosity and bicipital aponeurosis which merges with the deep fascia of the forearm. ⁽¹⁾ This mode of insertion makes it an efficient and important supinator of the forearm. It is the only flexor

of the arm that crosses the shoulder as well as the elbow joint thereby acting on both joints. It is innervated by the musculocutaneous nerve and vascularized by brachial and anterior circumflex humeral arteries and brachial vein. ⁽¹⁾ Biceps brachii has been stated as one of the muscles that shows frequent anatomical variations. ⁽²⁻⁵⁾ Some of its reported anomalies have been manifested as supernumerary fascicles that originate from the coracoid process, tendon of pectoralis major, articular capsule and head of the humerus or from humerus itself. ⁽⁶⁾ Among those variations, the presence of a

supernumerary fascicle arising from the shaft of the humerus, which is known as the humeral head of biceps brachii, is known to be the most common anomaly. (3, 7, 8) Multiple supernumerary heads of four to seven have also been reported to a lesser extent. (1, 3, 4, 5) A large body of evidence suggests a wide range of racial variations in the occurrence of humeral head of biceps brachii muscle. It was shown to have an incidence of 7.1% in Indians, 8% in Chinese, 10% in European whites, 10% in Sri Lankans, 12% in African Blacks, 15% in Turkish, 18% in Japanese, 21.5% in South African Blacks and 8.3% in South African Whites, and 37.5% in Colombians. (3, 8-16) From a clinical standpoint of view, muscle anomalies are difficult to differentiate from soft tissue tumors. (5) High median nerve compression around the elbow joint has been described as resulting from a number of clinical and anatomical entities. The existence of an anomalous muscle in and around the elbow region may cause high median nerve palsy and compression of the brachial artery. (5) Further, knowledge of the incidence of humeral head of biceps brachii will facilitate preoperative diagnosis as well as the surgical procedures of the upper limb. (5, 9) The median nerve is normally formed by the union of lateral root of median nerve arising from the lateral cord C5, C6, C7 of brachial plexus and medial root of median nerve arising from the medial cord C8, T1 of brachial plexus anterior to the axillary artery. Some fibres from C7 often leave the lateral root to join the ulnar nerve. Clinically they are believed to be mainly motor to the flexor carpi ulnaris. The median nerve enters the arm at first lateral to the brachial artery. Near the insertion of the coracobrachialis, it crosses in front of the artery, descending medial to it, to the cubital fossa, where it is posterior to the bicipital aponeurosis and anterior to the brachialis. It usually enters the forearm between the heads of the

pronator teres, crossing to the lateral side of the ulnar artery and separated from it by the deep head of pronator teres. (4) Anomalous pattern of the median nerve can be explained on the basis of embryological development. The upper limb buds lie opposite the lower five cervical and upper two thoracic segments. As soon as the buds form, the ventral primary rami of the spinal nerves penetrate into the mesenchyme of limb bud. Immediately the nerves enter the limb bud, they establish intimate contact with the differentiating mesodermal condensations and the early contact between nerve and muscle cells is a prerequisite for their complete functional differentiation. (17) The growth as well as the path finding of nerve fibres towards the target is dependent upon concentration gradient of a group of cell surface receptors in the environment. (4) Several signalling molecules and transcription factors have been identified which induce the differentiation of the dorsal and ventral motor horn cells. The high percentage of anomalies as mentioned above emphasizes the complexities and irregularities of this anatomic region with regard to surgical approaches. (18) Knowledge of such variations is important for surgeons to perform surgical procedures in the axillary region and arm. (19) Considering the high percentage of anomalies in the formation of median nerve and its paramount clinical importance, the present variations are documented. Variations in the formation and branching pattern of the brachial plexus constitute an important anatomical and clinical entity and have been reported by several investigators. (20-22) The median, musculocutaneous and ulnar nerves after their origin from the brachial plexus, pass through the anterior compartment of the arm without receiving any branch from any nerve in the neighbourhood. (23) Although the communications between the different

nerves in the arm are rare, those between the median nerve and musculocutaneous nerve have been described from nineteenth century. ⁽²⁴⁾ Knowledge of anatomical variation of these nerves at the level of upper arm is essential in light of the frequency with which surgery is performed in the axilla and the surgical neck of the humerus. ⁽²⁵⁾

CASE REPORT

During routine dissection of undergraduate First MBBS students a variation was found in the right upper limb of a 70 year old male donated embalmed cadaver in the department of Anatomy of K.J.Somaiya Medical College, Sion, Mumbai, India. The third head of biceps brachii was supplied by the median nerve. The third head was taking origin from the anterolateral surface of the shaft of the humerus. The third head joined with the other two heads and form a common tendon which got inserted into the radial tuberosity of the radius and bicipital aponeurosis. The musculocutaneous nerve was absent and all the muscles of the front of the arm were supplied by median nerve. The third head was also supplied by the median nerve. There was no associated arterial variation seen in the specimen. The variation was unilateral and the left upper limb of the cadaver was normal. The photographs of the variations were taken for proper documentation and ready reference.

DISCUSSION

Anatomy is a morphological science which cannot fail to interest the clinicians. The standard Anatomy text states the incidence of variation of supernumerary heads of biceps brachii as 10%. ⁽¹⁾ Although this is based on some European populations, ⁽¹⁰⁾ it ignores a large body of evidence with

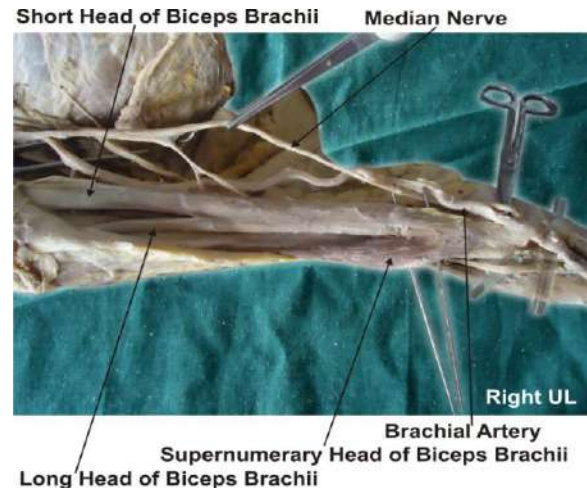


Figure 1: The photographic presentation of the third head of biceps brachii taking origin from the anterolateral surface of the shaft of the humerus. The third head joined with the other two heads and form a common tendon which got inserted into the radial tuberosity of the radius and bicipital aponeurosis.

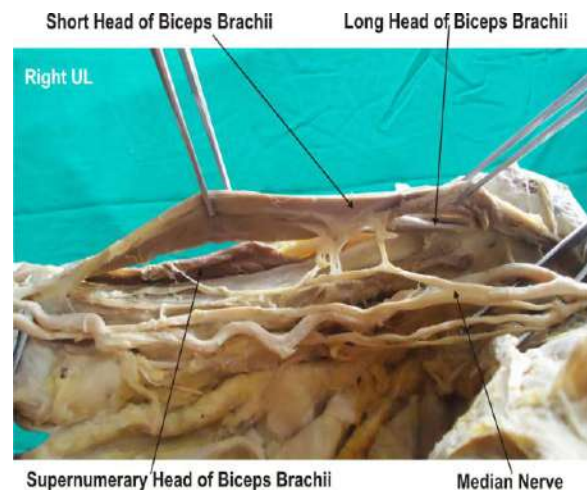


Figure 2: The photographic presentation of the median nerve supplying all the muscles of the front of the arm including the third head of biceps. The musculocutaneous nerve was absent.

reference to other populations. ^(3, 8-16) Furthermore, racial variation of the incidence of the supernumerary head of biceps brachii has been clearly demonstrated by comparative studies between Brazilian whites and black subjects. The incidence of supernumerary head of biceps brachii in blacks was found to be significantly lower

than in whites. (26) The variations of the incidence of the third head of biceps brachii were attributed to evolutionary or racial trends. (8) Rodriguez-Niedenfuhr classified the supernumerary heads of biceps brachii muscle into three types depending upon their origin i.e. superior, inferomedial and inferolateral. In the present case the supernumerary head of biceps brachii is of inferolateral type. (27) Embryologically it has been stated that the third head of biceps brachii arises from the brachialis muscle and in such instances its distal insertion has been translocated from ulna to the radius. (2) The innervation and vascularization of the third head of biceps brachii from musculocutaneous nerve and brachial artery is based on the normal embryologic development of the related dermatomes and myotomes. It is presumed that the development of the biceps brachii muscle is likely to influence the course and the branching pattern of musculocutaneous nerve. (13, 28) The median nerve supplying the supernumerary head was rare and not found in literature. The communication between the musculocutaneous nerve and the median nerve have been classified in different types by Li Minor and Venieratos and Anagnostopoulou. (29,30) Li Minor categorized these communications into following five types: In type I, there is no communication between the median nerve and the musculocutaneous nerve, in type II, the fibers of the lateral root of the median nerve pass through the musculocutaneous nerve and join the median nerve in the middle of the arm, whereas in type III, the lateral root fibers of the median nerve pass along the musculocutaneous nerve and after some distance, leave it to form the lateral root of the median nerve. In type IV, the musculocutaneous nerve fibers join the lateral root of the median nerve and after some distance the musculocutaneous nerve arises from the median nerve. In type V, the

musculocutaneous nerve is absent and the entire fibers of the musculocutaneous nerve pass through the lateral root and fibers to the muscles supplied by the musculocutaneous nerve branch out directly from the median nerve. (29) In the present case all the muscles of the front of the arm including supernumerary head of biceps brachii muscle were supplied by the median nerve. The musculocutaneous nerve was absent i.e. Type V of Li Minor's.

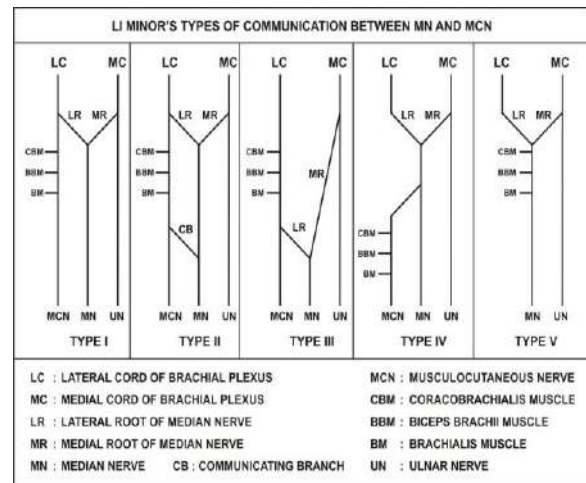


Figure 3: The schematic presentation of Li Minor's classification showing five types of communications between musculocutaneous and median nerves.

Venieratos and Anagnostopoulou (30) also described three different types of communication between musculocutaneous and median nerves in relation to coracobrachialis muscle. Type 1: communication between musculocutaneous and median nerve is proximal to the entrance of musculocutaneous into coracobrachialis. Type 2: communication between the two nerves is distal to the muscle. Type 3: neither the nerve nor its communicating branch pierced the muscle. In the present case the supernumerary head of biceps brachii muscle were supplied by median nerve which does not coincide with any of Venieratos's classification. (29, 30) The

knowledge of such variations is important during surgical corrections of the arm as well as in diagnosing the nerve impairments. Furthermore, it has been mentioned that any variant nerve with an abnormal origin, course and distribution is prone to accidental injuries and impairments. ⁽³¹⁾ This is further proved by the fact that supernumerary heads of the biceps brachii muscle have been reported to compress the surrounding neurovascular structures leading to erroneous interpretations during surgical procedures. ⁽²⁸⁾ The biceps brachii is known for its powerful elbow flexion and supination of the forearm. It can be argued that the presence of supernumerary heads of biceps brachii muscle increase its kinematics. Therefore, from anatomical standpoint of view it can be presumed that the presence of a third head may increase the power of flexion and supination of the forearm. ⁽¹³⁾ In addition to allowing the elbow flexion irrespective of the shoulder joint position, the supernumerary head of biceps brachii may enhance the strength of elbow flexion. ⁽¹⁶⁾ The absent of musculocutaneous nerve and the median nerve supplying all the muscle of the front of arm including supernumerary head of biceps brachii muscle documented in present case may be attributed to random factors influencing the mechanism of formation of limb muscles and the peripheral nerves during embryonic life. Significant variations in nerve patterns may be a result of altered signaling between mesenchymal cells and neuronal growth cones ⁽³²⁾ or circulatory factors at the time of fusion of brachial plexus cords. ⁽³³⁾ Iwata believed that the human brachial plexus appears as a single radicular cone in the upper limb bud, which divides longitudinally into ventral and the dorsal segments. ⁽³⁴⁾ The ventral segments give roots to the median and the ulnar nerves with musculocutaneous nerve arising from the median nerve. He further kept the

possibility of failure of the differentiation as a cause for some of the fibers taking an aberrant course as a communicating branch. Chiarapattanakom et al. ⁽³⁵⁾ are of the opinion that the limb muscles develop from the mesenchyme of local origin, while axons of spinal nerves grow distally to reach the muscles and the skin. They blamed the lack of coordination between the formation of the limb muscles and their innervation for appearance of a communicating branch. Studies of comparative anatomy have observed the existence of such connections in monkeys and in some apes; the connections may represent the primitive nerve supply of the anterior arm muscles. ⁽²¹⁾ Chauhan et al strongly recommend the consideration of the phylogeny and the development of the nerves of the upper limb for the interpretation of the nerve anomalies of the arm. ⁽³⁶⁾ Considering the communication between the musculocutaneous and the median nerve as a remnant from the phylogenetic or comparative anatomical point of view and that the ontogeny recapitulates the phylogeny, they feel that the variations seen are the result of the developmental anomaly.

Clinical significance:

The anatomical variation described here has practical implications, since injury to the median nerve in the axilla or arm would, in this case, have caused unexpected paresis or paralysis of the flexor musculature of the elbow and hypoesthesia of the lateral surface of the forearm, in addition to the classical signs that are already well known. Injury to the median nerve could occur in cases of open or closed trauma to the arm, such as bullet and blade wounds or during surgeries on the axilla or arm. The median nerve and its roots are close to the axillary vein, which is used as the most cranial limit for axillary lymph node dissection, a procedure used in treating certain tumors,

such as breast carcinoma and melanoma. If the dissection extends more cranially than normal, injury to the median nerve (or to its medial root) may occur, with consequent dysfunction of the flexor musculature of the elbow if the anatomical variation described here is present. It would not be unlikely for such accidents to occur even with the most eminent surgeons, considering that the classical concept is that the median nerve does not give rise to branches in the arm.⁽³⁷⁾ The clinical relevance of such variations might also be correlated to entrapment syndromes. Entrapment of musculocutaneous nerve is rare and has its origin either in physical activity⁽³⁸⁾ or in violent passive movements of arm and forearm.⁽³⁹⁾ This knowledge of anastomosis between the musculocutaneous nerve and the median nerve may prove useful for clinicians in order to avoid an unnecessary Carpal tunnel release.⁽³⁰⁾ The presence of such type of variations is clinically important for orthopaedicians operating on surgical neck of the humerus and anaesthetist performing pain management therapies on the upper limb.

CONCLUSION

The presence of such type of variations are clinically important for Surgeons, Orthopaedicians, Radiologist and Anaesthetist performing pain management therapies on the upper limb & it is concluded that variations in branching pattern of cords of brachial plexus are a rule rather than exception.

Competing interests:

The authors declare that they have no competing interests.

Authors' contributions:

SPS wrote the case report, performed the literature review & obtained the photograph for the study. RMM performed the literature search and assisted with writing the paper. STS conceived the study

and helped to draft the manuscript. All authors have read and approved the final version manuscript.

ACKNOWLEDGEMENT

All the authors wish to convey our sincere thanks to Dr. Arif A. Faruqui for his valuable help and inspiration. Authors are thankful to Dr. S. D. Lele, Prof. and H.O.D. Dept. of Anatomy for her support. Authors also acknowledge the immense help received from the scholars whose articles are cited and included in references of this manuscript. The authors are also grateful to authors / editors / publishers of all those articles, journals and books from where the literature for this article has been reviewed and discussed.

REFERENCES

1. Williams PL, Dyson M, Standring S, Ellis H, Healy JC, Johnson D - Gray's Anatomy. 39th ed. London ELBS with Churchill Livingstone, 2005: 614-615, 853-5, 803-4.
2. Testut L, Tretado. De –Anatomica Humana. 1st ed. Barcelona: Salvat. 1902: 1022.
3. Asvat R, Candler P & Sarmiento EE, High incidence of the third head of biceps brachii in South African populations. J. Anat. 1993, 182:101-4.
4. Nakatani T, Tanaka S & Mizukami S, Bilateral four headed biceps brachii muscles: the median nerve and brachial artery passing through a tunnel formed by a muscle slip from the accessory head. Clin. Anat., 1998;11:209-12.
5. Nayak SR, Ashwin K, Madhan KSJ, Latha VP, Vasudha S & Merin M T, Four-headed biceps and triceps brachii muscles with neurovascular variation. Anat. Sci. Intl. 2008, 83:107-11.
6. Sargon MF, Tuncali D & Celik HH, An unusual origin for the supernumerary head of biceps brachii muscle. Clin. Anat. 1996, 9:160-2.

7. Khaledpour C, Anomalies of the biceps muscle of the arm. *Anat. Anz.*, 1985, 158:79-85.
8. Kopuz C, Sancak B. & Ozbenli S, On the incidence of the third head of biceps brachii in Turkish neonates and adults. *Kaibogaku Zasshi*.1999; 74:301-5.
9. Rai R, Ranade AV, Prabhu LV & Prakash MMP, Third head of Biceps brachii: A study in Indian population. *Singapore Med. J.* 2007, 48:929-31.
10. Bergman RA, Thompson SA, Afifi AK & Saadeh FA, *Compendium of human anatomic variation*, 1st Ed. Baltimore, Urban and Schwarzenberg, 1988,11.
11. Torre FRL, Cegarra JN & Berruezo JP, Biceps brachii muscle attached to the extensor carpii radialis brevis muscle: an unreported anatomical variation in humans. *Anat. Anz.*, 1994, 176:319-21.
12. Kosugi K, Shibata S & Yamashita H, Supernumerary humeral heads of biceps brachii and branching pattern of the musculocutaneous nerve in Japanese. *Surg. Rad. Anat.*, 1992; 14:175-85.
13. Kumar H, Das S & Rath G, An anatomical insight into the third head of biceps brachii muscle. *Bratisl. Lek. Listy.*, 2008, 109:76-8.
14. Tountas CP & Bergman RA, *Anatomic variations of the upper extremity*, 1st ed. New York, Churchill Livingstone, 1993: 97-99.
15. Rincon F, Rodriguez IZ & Sanchez A, The anatomic characteristics of the third head of biceps brachii muscle in Colombian population. *Rev. Chil. Anat.* 2002, 20(2):197-200.
16. Swieter MG & Carmichael SW, Bilateral three-headed biceps brachii muscles, *Anat. Anz.*, 1980; 148:346-9.
17. Sandler TW, Langman's Medical Embryology, In: *Muscular system*. 10th ed. Philadelphia Lippincott Williams and Wilkins, 2006: 146-147.
18. Edglseder WA JR, Goldman M. Anatomic variations of the musculocutaneous nerve in the arm. *Amer J Orthop* 1997; 26: 777-80.
19. Uysal II, Seker M, Karabulut AK, Buyukmumcu M, Ziylan T, Brachial plexus variation in human fetuses. *Neurosurgery* 2003; 53: 676-84; discussion 684.
20. Kerr AT. The brachial plexus of nerves in man : the variations in its formation and branches, *American Journal of Anatomy*, 1918, vol. 23, n. 2, p. 285-395.
21. Miller RA. Comparative studies upon the morphology and distribution of the brachial plexus. *American Journal of Anatomy*, 1934, vol. 54, n. 1, p. 143-166.
22. Bergman RA, Afifi AK, Miyauchir RA. *Illustrated encyclopedia of human anatomic variation*, In: *Nervous system - plexuses*. 1988, 148-157.
23. Hollinshead WH, *Functional anatomy of the limbs and back*. 4th ed. Philadelphia: W.B. Saunders, 1976. p. 134-140.
24. Harris W. The true form of the brachial plexus, *Journal of Anatomy and Physiology*, 1904, vol. 38, p. 399-422.
25. Leffert, RD. *Anatomy of the brachial plexus*. New York: Churchill Livingstone, 1985, p 384.
26. Santo Neto H, Camilli JA, Andrade JC, Meciano FJ & Marques MJ, On the incidence of the biceps brachii third head in Brazilian white and blacks. *Anat. Anz.*, 1998, 180:69-71.
27. Rodriguez-Niedenfuhr M, Vazquez T, Choi D, Parkin I, Sanudo JR – Supernumerary humeral heads of the biceps brachii muscle revisited. *Clin Anat.* 2003; 16:197-203.
28. Warner, J. P.; Palleta, G. A. & Warren, R. F. Supernumerary Head of the Biceps brachii, Case report demonstrating clinical relevance. *Clin. Ortho. Res.* 1992, 280:179-81,.
29. Le Minor JM. A rare variant of the median and musculocutaneous nerves in man. *Archives Anatomy Histology Embryology* 1992; 73: 33-42.
30. Venierators D and Anagnastopoulou S classification of communication between the musculocutaneous and

- median nerves. *Clinical Anatomy*. 1998; 11: 327-331.
31. Roberts WH, Anomalous course of the median nerve medial to the trochlea and anterior to the medial epicondyle of the humans. *Anat. Anz.*, 1992, 174:309-11.
 32. Abhaya A, Bhardwaj R, Prakash R, Dual origin of musculocutaneous nerve, *Journal of Anatomical Society of India*, 2003, vol. 52, n. 1, p. 94.
 33. Kosugi K, Mortia T, Yamashita H. Branching pattern of the musculocutaneous nerve. 1. Cases possessing normal biceps brachii. *Jikeikai Medical Journal*, 1986, vol. 33, p. 63-71.
 34. Iwata, H. Studies on the development of the brachial plexus in Japanese embryo. *Republic Department Anatomy Mie Prefect University School of Medicine*, 1960, vol. 13, p. 129-144.
 35. Chiarapattanakom P, Leechavengvons S, Witoonchart K, Uerpairojkit C, Thuvasethakul P, Anatomy and internal topography of the musculocutaneous nerve: The nerves to the biceps and brachials muscle. *Journal of Hand Surgery*, 1998, vol. 23A, p. 250-255.
 36. Chauhan R, Roy TS. Communication between the median and musculocutaneous nerve: A case report. *Journal of Anatomical Society of India*, 2002, vol. 51, n. 1, p. 72-75.
 37. Fregnani JHTG., Macéa MIM, Pereira CSB, Barros MD, Macéa JR, Absence of the musculocutaneous nerve: a rare anatomical variation with possible clinical-surgical implications. *Sao Paulo Medical Journal*, 2008, vol. 126, n. 5, p. 288-90.
 38. Falsenthal G, Mondell DL, Reischer MA, Mack RH, Forearm pain secondary to compression syndrome of the lateral cutaneous nerve of the forearm. *Archaeological Physical Medical Rehabilitation*, 1984, vol. 65, p. 139-141.
 39. Kim SM, Goodrich JA. Isolated proximal musculocutaneous nerve palsy: Case report. *Archaeological Physical Medical Rehabilitation*, 1984, vol. 65, p. 735-736.

How to cite this article: Sawant SP, Shaikh ST, More RM. Variant nerve supply of the third head of biceps brachii muscle. *Int J Health Sci Res*. 2012;2(9):75-82.
