

A case Report on Bilateral Trifurcation of the Sciatic Nerve and Variant Formation of Sural Nerve



Medical Science

KEYWORDS : Sciatic Nerve, Trifurcation, Tibial Nerve, Superficial Peroneal Nerve, Deep Peroneal Nerve, Popliteal Fossa, Sural Nerve.

Dr. Sharadkumar Pralhad Sawant

Associate Professor, Department of Anatomy, K. J. Somaiya Medical College, Somaiya Ayurvihar, Eastern Express Highway, Sion, Mumbai-400 022.

ABSTRACT

The sciatic nerve is the thickest nerve in the body. It leaves the pelvis via the greater sciatic foramen below piriformis and descends between the greater trochanter and ischial tuberosity, along the back of the thigh, dividing into the tibial and common peroneal (fibular) nerves at a varying level proximal to the knee. The common peroneal (fibular) nerve divides at the level of the neck of the fibula into superficial and deep peroneal nerves. During routine dissection for the first MBBS students, we observed an unusual trifurcation of the sciatic nerve on the back of both the thighs in the middle of the popliteal fossa of a 70 years old, donated embalmed male cadaver in the Department of Anatomy, K.J.Somaiya Medical college, Sion, Mumbai, India. The sciatic nerve terminates in the middle of the popliteal fossa into the tibial, the superficial and the deep peroneal (fibular) nerves. The sural nerve was formed by the peroneal communicating branch of the deep peroneal nerve in the popliteal fossa, and descends on the posterior surface of the gastrocnemius to enter the superficial fascia about the middle of the back of the leg. It is then joined by the tibial communicating branch from the tibial nerve. The photographs of the trifurcation of the sciatic nerve were taken for proper documentation and for ready reference. The variation was bilateral. There were no associated arterial and muscular variations found in the same cadaver. Conclusion: The trifurcation of the sciatic nerve is very rare. The knowledge of trifurcation of sciatic nerve is important for clinicians and surgeons. Clinically, the sural nerve is widely used for both diagnostic (biopsy and nerve conduction velocity studies) and therapeutic purposes (nerve grafting). Thus, a detailed knowledge of the anatomy of the sural nerve and its contributing nerves are important in carrying out these and other procedures.

Introduction:

The sciatic nerve (also known as the ischiadic nerve and the ischiatic nerve) is 2 cm wide at its origin and is the thickest nerve in the body. It leaves the pelvis via the greater sciatic foramen below piriformis and descends between the greater trochanter and ischial tuberosity, along the back of the thigh, dividing into the tibial and common peroneal (fibular) nerves at a varying level proximal to the knee. Superiorly it lies deep to the gluteus maximus, resting first on the posterior ischial surface with the nerve to the quadratus femoris lying between them. It then crosses posterior to the obturator internus, the gemeli and quadratus femoris, separated by the latter from obturator externus and the hip joint. It is accompanied medially by the posterior femoral cutaneous nerve and the inferior gluteal artery. More distally it lies behind adductor magnus and is crossed posteriorly by the long head of biceps femoris. It corresponds to a line drawn from just medial to the midpoint between the ischial tuberosity and greater trochanter to the apex of the popliteal fossa. Articular branches arise proximally to supply the hip joint through its posterior capsule, these are sometimes derived directly from the sacral plexus. Muscular branches are distributed to biceps femoris, semitendinosus, semimembranosus and the ischial part of adductor magnus. The point of division of the sciatic nerve into the tibial and the common peroneal nerve is very variable. The common site is at the junction of the middle and lower thirds of the thigh, near the apex of the popliteal fossa. The division may occur at any level above this, through rarely below it. It is not uncommon for the major components to leave the sacral plexus separately, in which case the common peroneal component usually passes through piriformis at the greater sciatic notch while the tibial component passes below the muscle (1). The sciatic nerve supplies the knee flexors and all the muscles below the knee, so that a complete palsy of the sciatic nerve results in a flail foot and severe difficulty in walking. This is rare and usually related to trauma. The nerve is vulnerable in posterior dislocation of the hip. As it leaves the pelvis it passes either behind piriformis or sometimes through the muscle and at that point it may become entrapped (the piriformis syndrome; this is a common anatomical variant but an extremely rare entrapment neuropathy). External compression over the buttock (e.g. in patients who lie immobile on a hard surface for a considerable length of time) can injure the nerve. Sadly the most common cause of serious sciatic nerve injury (and consequent major medicolegal claims) is iatrogenic. It may be damaged in misplaced therapeutic injections into gluteus maximus. The safe zone for deep intramuscular injections here is the upper outer quadrant of the buttock. Perhaps safer still is to inject into the quadriceps, through this can produce problems of its own, e.g. haemorrhage, leading to contracture of the muscle, which limits

knee motion. Sciatic nerve palsy occurs after total hip replacement or similar surgery in 1% of cases. This can be due to sharp injury burning from bone cement, traction from instruments, manipulation of the hip, inadvertent lengthening of the femur, or haematoma surrounding the nerve or within its soft tissue coverings. Haematoma is characterised by the development of severe pain in the immediate post operative period. Early surgical exploration and evacuation of haematoma can reverse the nerve lesion. Unfortunately the other causes may not be influenced. The majority are temporary. Complete sciatic nerve palsy is very rare. For some reason, possibly anatomical, the common peroneal part is more usually affected alone. The patient has a foot drop and a high stepping gait (1). The sciatic nerve bifurcates into two major divisions (tibial and common peroneal), most commonly at the lower part of the posterior compartment of the thigh (1, 2, 3, 4, 5, 6). Several authors have reported variations on its division into the tibial and common peroneal nerve from the sacral plexus to the lower part of the popliteal space (3, 4, 5, 6, 7, 8, 9, 10). These anatomical variations may contribute to piriformis syndrome, sciatica, coccygodynia and muscle atrophy (11). This should be taken into account by clinicians who are planning interventions around the sciatic nerve and its division in the lower extremity. Higher level of the sciatic nerve division is a relatively frequent phenomenon. The sural nerve (short saphenous nerve), is a sensory nerve formed by the union of the medial sural cutaneous with the peroneal anastomotic branch of the lateral sural cutaneous nerve, passes downward near the lateral margin of the tendo calcaneus, lying close to the small saphenous vein, to the interval between the lateral malleolus and the calcaneus. It runs forward below the lateral malleolus, and is continued as the lateral dorsal cutaneous nerve along the lateral side of the foot and little toe (via a dorsal digital nerve), communicating on the dorsum of the foot with the intermediate dorsal cutaneous nerve, a branch of the superficial peroneal. In the leg, its branches communicate with those of the collateral branches of the common tibial, and common fibular nerve (1). The superficial peroneal nerve begins at the bifurcation of common peroneal nerve behind the head of the fibula. It is at first deep to peroneus longus, and then passes anteroinferiorly between the peroneus longus and peroneus brevis and finally between extensor digitorum longus and peronei to pierce the deep fascia in the distal third of leg, where it divides into medial and lateral branches. The medial branch passes anterior to the ankle and divides into two dorsal digital nerves: one supplies the medial side of the great toe, and the other supplies the adjacent sides of the second and third toes. The smaller lateral branch crosses the front of the ankle traverses the dorsum of the foot laterally. It divides into dorsal digital branches that supply the contiguous sides of the third to fifth toes and the skin of the lat-

eral aspect of the ankle. Both branches, especially the lateral, are at risk during the placement of portal incisions for arthroscopy. Superficial peroneal nerve supplies peroneus longus and brevis, and the skin of the lower part of the front of the leg, the greater part of the dorsum of the foot, and most of the dorsal surfaces of the toes (1).

Case Report:

During routine dissection for the first MBBS students, we observed an unusual trifurcation of the sciatic nerve on the back of both the thighs in the middle of the popliteal fossa of a 70 years old, donated embalmed male cadaver in the Department of Anatomy, K.J.Somaiya Medical college, Sion, Mumbai, India. The sciatic nerve terminated in the middle of the popliteal fossa by giving three branches. The three branches given were tibial, superficial and deep peroneal nerves (Fig. - 1). The superficial peroneal nerve was almost as thick as the deep peroneal nerve (Fig. - 2). There is high division of superficial peroneal nerve into medial and lateral branches. The medial branch arose from the superficial peroneal nerve at the proximal calf beneath the crural fascia and pierced the anterior intermuscular septum to enter the superficial fascia of anterior compartment. The lateral branch descended in the anterior intermuscular septum in a peroneal tunnel, pierced the deep fascia of lateral compartment and gave cutaneous branches to the adjacent skin of front of leg. Both medial and lateral branches were providing motor branches to peroneus longus and brevis before piercing the deep fascia. The sural nerve was formed by the peroneal communicating branch of the deep peroneal nerve in the popliteal fossa, and descends on the posterior surface of the gastrocnemius to enter the superficial fascia about the middle of the back of the leg. It is then joined by the tibial communicating branch from the tibial nerve and accompanies the small saphenous vein to the lateral side of the foot (Fig. - 2). The photographs of the trifurcation of the sciatic nerve were taken for proper documentation and for ready reference. The variation was bilateral. There were no associated arterial and muscular variations found in the same cadaver.

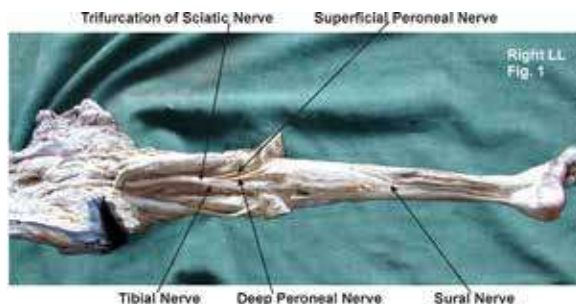


Figure - 1 : The photographic presentation showing the sciatic nerve trifurcated in the middle of the popliteal fossa in to tibial, superficial and deep peroneal nerves.

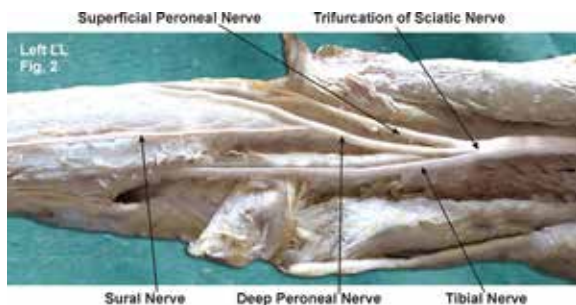


Figure - 2 : The photographic presentation showing the superficial peroneal nerve almost as thick as the deep peroneal nerve. The sural nerve was formed by the peroneal communicating branch of the deep peroneal nerve joined by the tibial communicating branch from the tibial nerve

Discussion

During embryological development at the base of the limb bud,

the nerves contributing to the lower limb forms two plexuses (lumbar and sacral) (12). Later, as the elements from each of these plexuses grow out into the limb, they are subdivided into dorsal and ventral components, for the dorsal and ventral musculatures (12). The sciatic nerve is formed when the large dorsal component of the sacral plexus (common fibular nerve) and the ventral component (tibial nerve) moves downward close together (12). A number of variations in the course and distribution of the sciatic nerve have been reported. Bifurcation into its two major divisions (common peroneal and tibial) may occur anywhere between the sacral plexus and the lower part of the thigh. The two terminal branches of the sciatic may arise directly from the sacral plexus (13). Pokorný et al, Ugrenović et al, Gabrielli et al, Saleh et al and Güvencer et al studied the different level of division of the sciatic nerve (14, 15, 16, 17, 18). When the sciatic nerve divides in the pelvis, the common peroneal nerve usually pierces the piriformis muscle. The common peroneal nerve passes either through the piriformis or above the piriformis (19). The entire sciatic nerve may pass through the piriformis causing the sciatica (20). The tibial nerve passing deep and common peroneal nerve passing superficial to the superior gemellus has been found in literature (21). The trifurcation of sciatic nerve into tibial, common peroneal and lateral cutaneous nerve of calf has been observed (22) but the trifurcation of sciatic nerve into tibial, superficial and deep peroneal nerves is not documented in literature. The anatomy of the superficial peroneal nerve is of critical importance to surgeons performing a variety of procedures in the middle third of the lateral leg. So, a good knowledge of the anatomical relationships and common variations of the superficial peroneal nerve is required to prevent injuries during surgical procedures. The variations about the superficial peroneal nerve are the absence of either the lateral cutaneous branch or the medial cutaneous branch, which are seen as 8.6% and 0.8%, respectively. It has been shown that in the absence of the medial cutaneous branch, the saphenous nerve innervates the medial part of the foot, while in the absence of the lateral cutaneous branch, the sural nerve supplies the lateral part of the dorsum of the foot (23). Sometimes, the superficial peroneal nerve pierces the intermuscular septum and passes from the lateral compartment into the anterior compartment, following a superficial course. In other cases, the medial and lateral branches divide before the superficial fascia is pierced (24). The medial branch may be absent and may be replaced by the deep peroneal nerve. The nerve has been described as arising from the nerve to peroneus brevis (25). The superficial peroneal nerve may bifurcate in the upper part of the leg and both the branches may remain in the lateral compartment (26). Very rarely the superficial peroneal nerve may be seen in the anterior intermuscular septum (27, 28). The sural nerve arises from the tibial nerve in the popliteal fossa, and descends on the posterior surface of the gastrocnemius to enter the superficial fascia about the middle of the back of the leg. It is then joined by the peroneal communicating nerve and accompanies the small saphenous vein to the lateral side of the foot. It supplies the skin of the lateral side of the dorsum of the foot and the lateral side of the little toe (29). In the present case the sural nerve was formed by the peroneal communicating branch of the deep peroneal nerve in the popliteal fossa, and descends on the posterior surface of the gastrocnemius to enter the superficial fascia about the middle of the back of the leg. It is then joined by the tibial communicating branch from the tibial nerve and accompanies the small saphenous vein to the lateral side of the foot. The close relationship of the sural nerve with the small saphenous vein may lead to sural nerve damage (nerve tear, neuroma and scar inclusion) after small saphenous vein stripping (30, 31). The rich sensory innervation of ankle and foot is manifested through numerous communicating branches linking deep peroneal and sural nerves on the anterolateral aspects of the foot. A study by Drizenko et al. (2004) in 55 dissections has showed 35 such communicating branches (32). Kosinski (1926) dissected 226 feet and described 12 patterns of termination of the dorsal nerves of the foot stressing the great variability of these nerves (33).

Clinical significance:

The variations of the superficial peroneal nerve are important in fasciotomy, fasciocutaneous flaps, traumatic and atraumatic

pain syndromes of the leg, regional anesthesia of the ankle, and in the determination of the surgical procedure to foot and ankle (23, 34). It has been known that the superficial peroneal nerve and its terminal branches may be iatrogenically damaged at around the knee joint, lower leg, and ankle joint, respectively (35, 36, 37). Superficial peroneal nerve is suggested as an important and appropriate graft, particularly when multiple and long nerve grafts are needed (38). Also, direct biopsy from the superficial peroneal nerve is used in the diagnosis of its diseases (39). Superficial peroneal nerve may divide into its terminal branches before or after piercing the crural fascia, and so the nerve itself or its terminal branches may be compressed when passing through the deep fascia (34). In such cases, several findings such as symptoms aggravated with exercise, sensory loss on the dorsum of the foot, and swelling and sensitivity on the anterolateral parts of the leg with dorsiflexion of the ankle were reported (40). In the present case also the superficial peroneal nerve divided into terminal branches before piercing the crural fascia. Both medial and lateral branches were passing through the anterior intermuscular septum where they can be compressed. Superficial peroneal nerve compressive syndromes have been described where the nerve pierces the superficial fascia of the leg, causing a clinical picture similar to an L5 root disease (dysesthesia on the dorsal surface of the foot and respective toes) (41). In all the above situations, precise identification of the course of the superficial peroneal nerve is extremely important. Superficial peroneal nerve is usually accompanied by a small artery and vein. So, it may be used as a vascularized graft in peripheral nerve surgery by orthopaedicians. Its motor branches to the peroneal muscles can be used for a neurotization of the anterior tibial muscle in patients with L4 root injuries (polio, spinal injuries, and others) (42). On the

other hand, in plastic surgery small arteries and veins accompanying the superficial peroneal nerve may be used in vascularized skin grafts (43). The sural nerve is often used as a donor in autogenous nerve grafting in the child as well as in the adult. Biopsy material taken from the sural nerve is of great importance in the diagnosis of neural diseases. Besides, the sural nerve is the most suitable one for use as a nerve graft in surgery. There may be some difficulties to access it surgically due to variations in the formation of the nerve (44, 45).

Conclusion

Knowledge of potential variant anatomy of the superficial peroneal nerve and sural nerve should aid surgeons in locating the nerves as well as avoiding potentially unnecessary complications. Awareness of the unusual variant location of lateral branch of superficial peroneal nerve in the anterior intermuscular septum in the present case will enable the surgeon to find and preserve the nerve during fasciotomy, neurolysis, neuroma resection, or bony and soft tissue reconstruction.

Competing interests:

The author declare that he has no competing interests.

Acknowledgement:

Author is also thankful to Dean Dr. Geeta Niyogi Madam for her support and encouragement. Author is also thankful to Dr. Arif A. Faruqui and Mr. M. Murugan for their help. Author also acknowledge the immense help received from the scholars whose articles are cited and included in references of this manuscript. The author is also grateful to authors / editors / publishers of all those articles, journals and books from where the literature for this article has been reviewed and discussed.

REFERENCE

1. Standring S: Gray's Anatomy. 39th edition. London: Elsevier Churchill Livingstone; 2005: 1456, 1504-1505.
2. Yuen EC, So YT. Sciatic neuropathy. *Neurol Clin* 1999; 17:617-31. | 3. Pavai J, Nayak S. A case of bilateral high division of sciatic nerve with a variant inferior gluteal nerve. *Neuroanatomy* 2006; 5:33-4. | 4. Standring S. Gray's Anatomy: the Anatomical Basis of Clinical Practice. 39th ed. London: Churchill Livingstone, 2005: 1364-458. | 5. Rosse C, Gaddum-Rosse P, Hollinshead WH. *Hollinshead's Textbook of Anatomy*. 5th ed. Philadelphia: Lippincott-Raven Publishers, 1997: 324-651. | 6. Moore KL, Dalley AF. *Clinically Oriented Anatomy*. 4th ed. Philadelphia: Lippincott Williams & Wilkins, 1999: 347-560. | 7. Ndiaye A, Sakho Y, Fall F, Dia A, Sow ML. [Sciatic nerve in gluteal portion: application of sciatic nerve post injection lesion.] *Morphologie* 2004; 88:135-8. French. | 8. Arifoglu Y, Sürücü HS, Sargon MF, Tanyeli E, Yazar F. Double superior gemellus together with double piriformis and high division of the sciatic nerve. *Surg Radiol Anat* 1997; 19:407-8. | 9. Valade N, Ripart J, Nouvellon E, et al. Does sciatic parasacral injection spread to the obturator nerve? An anatomic study. *Anesth Analg* 2008; 106:664-7. | 10. Benzon HT, Katz JA, Benzon HA, Iqbal MS. Piriformis syndrome: anatomic considerations, a new injection technique, and a review of the literature. *Anesthesiology* 2003; 98:1442-8. | 11. Babinski MA, Machado FA, Costa WS. A rare variation in the high division of the sciatic nerve surrounding the superior gemellus muscle. *Eur J Morphol* 2003; 41:41-2. | 12. Demiryurek D, Bayramoglu A, Erbil M, Aldur MM, Mustafa ES. Bilateral divided piriformis muscle together with the high division of the sciatic nerve. *Gazi Med J* 2002; 13:41-4. | 13. Bergman RA, Afifi AK, Miyauchi R. *Compendium of human anatomical variations*. Baltimore, Urban and Schwarzenberg. 1988; 146. | 14. Pokorný D, Jahoda D, Veigl D, Pinskerová V, Sosna A. Topographic variations of the relationship of the sciatic nerve and the piriformis muscle and its relevance to palsy after total hip arthroplasty. *Surg Radiol Anat* 2006; 28:88-91. | 15. Ugrenović S, Jovanović I, Krstić V, et al. [The level of the sciatic nerve division and its relations to the piriform muscle]. *Vojnosanit Pregl* 2005; 62:45-9. Serbian. | 16. Gabrielli C, Olave E, Mandiola E, et al. Inferior gluteal nerve course associated to the high division of the sciatic nerve. *Rev Chil Anat* 1997; 15:79-83. | 17. Saleh HA, El-fark MM, Abdel-Hamid GA. Anatomical variation of sciatic nerve division in the popliteal fossa and its implication in popliteal nerve block. *Folia Morphol (Warsz)* 2009; 68:256-9. | 18. Güvencer M, Iyem C, Akyer P, Tetik S, Naderi S. Variations in the high division of the sciatic nerve and relationship between the sciatic nerve and the piriformis. *Turk Neurosurg* 2009; 19:139-44. | 19. Ugrenovic S, Jovanovic I, Krstic V, Stojanovic V, Vasovic L, Antic S, Pavlovic S. The level of the sciatic nerve division and its relations to the piriform muscle. *Vojnosanit Pregl* 2005; 62: 45-49. | 20. Chen WS. Bipartite piriformis muscle: an unusual cause of sciatic nerve entrapment. *Pain*. 1994; 58: 269-272. | 21. Babinski MA, Machado FA, Costa WS. A rare variation in the high division of the sciatic nerve surrounding the superior gemellus muscle. *Eur. J. Morphol.* 2003; 41: 41-42 | 22. Nayak S. An unusual case of trifurcation of the sciatic nerve. *Neuroanatomy* 2008; 5:6-7. | 23. Blair JM, Botte MJ: Surgical anatomy of the superficial peroneal nerve in the ankle and foot. *Clin Orthop* 1994, 305:229-238. | 24. Pacha D, Carrera A, Llusa M, Permanyer E, Molona O, Morro R: Clinical anatomy of the superficial peroneal nerve in the distal leg. *Eur J Anat* 2003, 7(Suppl 1):15-20. | 25. Bergman RA, Thompson SA, Afifi AK: *Compendium of Human Anatomic Variations*. Munich: Urban and Schwarzenberg; 1988:146-147. | 26. Browne JA, Morris MJ: Variant superficial fibular (peroneal) nerve anatomy in the middle third of the lateral leg. *Clin Anat* 2007, 20:996-997. | 27. Ducic I, Dellon AL, Graw KS: The clinical importance of variations in the surgical anatomy of the superficial peroneal nerve in the midthird of the lateral leg. *Ann Plast Surg* 2006, 56:635-638. | 28. Williams E, Dellon L: Intraseptal superficial peroneal nerve. *Microsurgery* 2007, 27:477-480. | 29. Hollinshead WH: *Anatomy for surgeons*. Volume III. 2nd edition. New York: Harper & Row; 1969:761. | 30. Mondelli M, Reale F, Cavallaro T: Neuroma of the sural nerve as a complication of stripping of the small saphenous vein. *Surg Neurol* 1997, 48(4):330-332. | 31. Simonetti S, Bianchi S, Martinoli C: Neurophysiological and ultrasound findings in sural nerve lesions following stripping of the small saphenous vein. *Muscle Nerve* 1999, 22(12):1724-1726. | 32. Drizenko A, Demondion X, Luyckx F, Mestdagh H, Cassagnaud X: The Communicating branches between the sural and superficial peroneal nerves in the foot: a review of 55 cases. *Surg Radiol Anat* 2004, 26(6):447-452. | 33. Kosinski C: The Course, Mutual Relations and Distribution of the Cutaneous Nerves of the Metazonal Region of Leg and Foot. *J Anat* 1926, 60:274-297. | 34. Canovas F, Bonnel F, Kouloumdjian P: The superficial peroneal nerve at the foot. Organisation, surgical applications. *Surg Radiol Anat* 1996, 18:241-244. | 35. Deutsch A, Wzykowski RJ, Victoroff BN: Evaluation of the anatomy of the common peroneal nerve. Defining nerve-at-risk in arthroscopically assisted lateral meniscus repair. *Am J Sports Med* 1999, 27:10-15. | 36. Takao M, Ochi M, Shu N, Uchio Y, Naito K, Tobita M, Matsusaki M, Kawasaki K: A case of superficial peroneal nerve injury during ankle arthroscopy. *Arthroscopy* 2001, 17:403-404. | 37. Solomon LB, Ferris L, Tedman R, Henneberg M: Surgical anatomy of the sural and superficial fibular nerves with an emphasis on the approach to the lateral malleolus. *J Anat* 2001, 199:717-723. | 38. Buntic RF, Buncke HJ, Kind GM, Chin BT, Ruebeck D, Buncke GM: The harvest and clinical application of the superficial peroneal sensory nerve for grafting motor and sensory nerve defects. *Plast Reconstr Surg* 2002, 109:145-151. | 39. Vallat JM, Gil R, Leboutet MJ, Hugon J, Moulies D: Congenital hypoand hypermyelination neuropathy. Two cases. *Acta Neuropathol (Berl)* 1987, 74:197-201. | 40. Jones HR Jr, Felice KJ, Gross PT: Pediatric peroneal mononeuropathy: A clinical and electromyographic study. *Muscle Nerve* 1993, 16:1167-1173. | 41. Styf J: Entrapment of the superficial peroneal nerve. Diagnosis and results of decompression. *J Bone Joint Surg* 1989, 71:131-135. | 42. Buyukmumcu M, Ustun ME, Seker M, Kocaogullari Y, Sagmanligil A: The possibility of deep peroneal nerve neurotisation by the superficial peroneal nerve: an anatomical approach. *J Anat* 1999, 194:309-312. | 43. Masquelet AC, Romana MC, Wolf G: Skin island flaps supplied by the vascular axis of the sensitive superficial nerves: anatomic study and clinical experience in the leg. *Plastic & Reconstructive Surg* 1992, 89:1115-1121. | 44. Brooks D: The place of nerve grafting in orthopedic surgery. *J Bone Joint Surg* 1955, 37:299-304. | 45. Hankin FM, Jaeger SH, Beddings A: Autogenous sural nerve grafts. A harvesting technique. *Orthopedics* 1985, 8:1160-1164. |