



A case Report on Unusual Termination of Anterior Tibial Artery

KEYWORDS

Anterior Tibial Artery, Double Dorsalis Pedis Artery, Surgeons, Orthopaedicians, Peripheral Pulse, Musculocutaneous Flap

Dr. Sharadkumar Pralhad Sawant

Associate Professor, Department of Anatomy, K. J. Somaiya Medical College, Somaiya Ayurvihar, Eastern Express Highway, Sion, Mumbai-400 022.

ABSTRACT During routine dissection, of the left upper limb of a 70 years old donated embalmed male cadaver in the Department of Anatomy, K.J. Somaiya Medical College, Sion, Mumbai, India, we observed two dorsalis pedis arteries arising from the anterior tibial artery. The pattern of nerves in the leg was normal. The variation was unilateral and the left lower limb was normal. The photographs of the double dorsalis pedis arteries was taken for proper documentation. The awareness of the double dorsalis pedis arteries is clinically important for surgeons, plastic surgeons and orthopaedicians. The knowledge of any variation in the course and distribution of dorsalis pedis artery is clinically important because the dorsalis pedis artery is used to record peripheral arterial pulsation. Also the musculo-cutaneous flaps based on dorsalis pedis artery are commonly used for reconstructive surgeries. A lack of knowledge of such type of variations might complicate surgical repair. The non healing diabetic foot ulcers are challenging problems, for surgeons, which are commonly dealt with by musculocutaneous flaps based on the branches of dorsalis pedis artery.

Introduction:

The dorsalis pedis artery also called as arteria dorsalis pedis is the continuation of the anterior tibial artery, passes forward from the ankle-joint along the tibial side of the dorsum of the foot to the proximal part of the first intermetatarsal space, where it divides into two branches, the first dorsal metatarsal and the deep plantar arteries. The dorsal artery of the foot may be larger than usual, to compensate for a deficient plantar artery; or its terminal branches to the toes may be absent, the toes then being supplied by the medial plantar; or its place may be taken altogether by a large perforating branch of the peroneal artery. This artery frequently curves laterally, lying lateral to the line between the middle of the ankle and the back part of the first interosseous space. The branches of the dorsalis pedis artery are the lateral tarsal, arcuate, medial tarsal, first dorsal metatarsal and deep plantar arteries. The lateral tarsal artery arises from the dorsalis pedis, as that vessel crosses the navicular bone; it passes in an arched direction laterally, lying upon the tarsal bones, and covered by the extensor digitorum brevis; it supplies this muscle and the articulations of the tarsus, and anastomoses with branches of the arcuate, anterior lateral malleolar and lateral plantar arteries, and with the perforating branch of the peroneal artery. The medial tarsal arteries are two or three small branches which ramify on the medial border of the foot and join the medial malleolar network. The arcuate artery arises a little anterior to the lateral tarsal artery; it passes laterally, over the bases of the metatarsal bones, beneath the tendons of the extensor digitorum brevis, its direction being influenced by its point of origin; and its anastomoses with the lateral tarsal and lateral plantar arteries. This vessel gives off the second, third, and fourth dorsal metatarsal arteries, which run forward upon the corresponding dorsal interossei, in the clefts between the toes, each divides into two dorsal digital branches for the adjoining toes. At the proximal parts of the interosseous spaces these vessels receive the posterior perforating branches from the plantar arch, and at the distal parts of the spaces they are joined by the anterior perforating branches, from the plantar metatarsal arteries. The fourth dorsal metatarsal artery gives off a branch which supplies the lateral side of the fifth toe. The first dorsal metatarsal artery runs forward on the first dorsal interosseous muscle, and at the cleft between the first and second toes divides into two branches, one of which passes beneath the tendon of the extensor hallucis longus, and is distributed to the medial border of the great toe; the other bifurcates to supply the adjoining sides of the great and second toes. The deep plantar artery descends into the sole of

the foot, between the two heads of the first dorsal interosseous muscle, and unites with the termination of the lateral plantar artery, to complete the plantar arch. It sends a branch along the medial side of the great toe, and is continued forward along the first interosseous space as the first plantar metatarsal artery, which bifurcates for supplying the adjacent sides of the great and second toes.

Case Report:

During routine dissection, of the right upper limb of a 70 years old donated embalmed male cadaver in the Department of Anatomy, K.J. Somaiya Medical College, Sion, Mumbai, India, we observed two dorsalis pedis arteries arising from the anterior tibial artery. The anterior tibial artery was exposed through a longitudinal incision in lateral calf over the mid portion of anterior compartment. The dense fascia of the anterior compartment was incised and dissection deepened between the bellies of the long extensors. The tibialis anterior and extensor hallucis longus muscles were fused, and neurovascular bundle was exposed between these and the extensor digitorum muscle; The anterior tibial artery, its paired tibial veins, and the tibial nerve were dissected along the surface of the interosseous membrane and the two dorsalis pedis arteries were observed. The pattern of nerves in the leg was normal. The variation was unilateral and the left lower limb was normal. The photographs of the double dorsalis pedis arteries was taken for proper documentation.

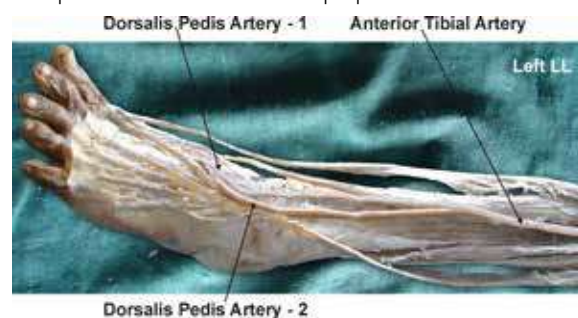


Figure showing photographic presentation of two dorsalis pedis arteries arising from the left anterior tibial artery.

Discussion:

In human anatomy, the dorsalis pedis artery (dorsal artery of foot), is a blood vessel of the lower limb that carries oxygen-

ated blood to the dorsal surface of the foot. It arises at the anterior aspect of the ankle joint and is a continuation of the anterior tibial artery. It terminates at the proximal part of the first intermetatarsal space, where it divides into two branches, the first dorsal metatarsal artery and the deep plantar artery. Along its course, it is accompanied by a deep vein, the dorsalis pedis vein. Dorsalis pedis artery of the dorsum of foot is the continuation of anterior tibial artery seen in 1st intermetatarsal space, where it dips into the sole, between the heads of 1st dorsal interosseous muscle to complete the plantar arch. In the foot it gives off medial and lateral tarsal arteries, arcuate artery and first dorsal metatarsal artery (1). Since ages interesting anomalies of the dorsalis pedis artery have been noted by the anatomists and surgeons. The dorsalis pedis artery was found to arise from the perforating branch of peroneal artery (2). The dorsalis pedis artery divided into two terminal branches 3cm distal to its origin (3). The arteriography to be taken prior to foot flap surgeries (3). The dorsalis pedis artery was the continuation of peroneal artery found in around 8% of the cases (4). In the present study two dorsalis pedis arteries were seen arising from the anterior tibial artery. Both the arteries ran together side by side to reach the first intermetatarsal space, The dorsalis pedis artery - 1 dipping in the proximal aspect of the space and the dorsalis pedis artery - 2 continued as 1st dorsal metatarsal artery. The aberrant arteries or anomalous course of the arteries of the lower limb can be attributed to their development. Since the dorsalis pedis artery serves as an important pedicle for most of the reconstructive surgeries of the foot, the knowledge about the aberration of the usual anatomic pattern of origin, branching and anastomosing patterns of the artery are of prime importance to the general surgeons, orthopaedic surgeons, plastic and reconstructive surgeons who deal with this area. The change in lifestyle in this 21st century has increased the number of diabetic patients. It has become a challenge to the health care providers to deal with the complications due to diabetes. Long standing and neglected cases have been seen to end up with diabetic neuropathy and diabetic foot ulcers. These non healing diabetic foot ulcers are challenging problems, for surgeons, which are commonly dealt with by musculocutaneous flaps based on the branches of dorsalis pedis artery.

Developmental Basis:

The axis artery of the lower limb develops from the 5th lumbar intersegmental artery. The embryonic blood vessels acquire a plexiform appearance in the foot. The dorsalis pedis artery is a constant embryonic vessel that plays an important role in the normal arterial morphogenesis of the lower limb. The tiny blood vessels derived from the blood

islands in the 3rd and 4th week of development merge with each other forming a continuous network of fine vessels. New vessels buds out from the walls grow out and get canalized to form newer vessels. These newer vessels of the neighbouring areas join to form a closed network. The adult arterial pattern of the lower limb develops from multiple and plexiform sources of vessels, and emergence of anastomoses between these vessels, which is followed by regression of some channels depending on the functional dominance. This explains why the anomalies of the blood vessels of the limbs not only present as divergence in the origin and course but also as supernumerary vessels in the region (5, 6).

Clinical significance:

The knowledge of any variation in the course and distribution of the dorsalis pedis artery is clinically important because the dorsalis pedis artery is used to record peripheral arterial pulsation. The dorsalis pedis artery pulse can be palpated readily lateral to the extensor hallucis longus tendon (or medially to the extensor digitorum longus tendon) on the dorsal surface of the foot, distal to the dorsal most prominence of the navicular bone which serves as a reliable landmark for palpation (7). It is often examined, by physicians, when assessing whether a given patient has peripheral vascular disease. It is absent, unilaterally or bilaterally, in 2-3 % of young healthy individuals (8).

Conclusion:

The knowledge of double dorsalis pedis artery is clinically important for surgeons operating on non healing diabetic foot ulcers using musculocutaneous flaps to improve blood supply and soft tissue coverage based on the branches of dorsalis pedis artery. A lack of knowledge of such type of variations might complicate surgical repair.

Competing interests:

The author declare that he has no competing interests.

Acknowledgement:

Author is also thankful to Dean Dr. Geeta Niyogi Madam for her support and encouragement. Author is also thankful to Dr. Arif A. Faruqui and Mr. M. Murugan for their help. Author also acknowledge the immense help received from the scholars whose articles are cited and included in references of this manuscript. The author is also grateful to authors / editors / publishers of all those articles, journals and books from where the literature for this article has been reviewed and discussed.

REFERENCE

1. William I, Walwick R, Dyson M, In: Gray's Anatomy 39th Edition, Edinburg: Churchill Livingstone, 2005, 1540.
2. Huber JF, The arterial network supplying the dorsum of foot. *Anat Res*, 1941, 80: 373. | 3. Bailleul.JP, Olivez. PR, Mestdag.H, Desgra-phical anatomy of the dorsalis pedis artery of the foot. *Bull Association of Anatomy (Nancy)*, 1984, 68: 15-25. | 4. Maral TM, Celik TC, Anomalous dorsalis pedis artery. *Surg Radiol Anat*, 1994, 6: 319-323. | 5. Sadler TW, In: *Langman's Medical Embryology*, 5th Edition, William and Wilkins. 1985, 68-69. | 6. Kesavi.D, Singh K, Melani RS, Anomalous course of dorsalis pedis artery. *Anatomical Adjuncts*, 2002, 3: 29-31. | 7. Mowlavi, A; Whiteman, J; Wilhelmi, BJ; Neumeister, MW; McLafferty, R. "Dorsalis pedis arterial pulse: palpation using a bony landmark". *Postgraduate Medical Journal* 78 (926): 2002, 746-7. | 8. Robertson, GS; Ristic, CD; Bullen, BR. "The incidence of congenitally absent foot pulses". *Annals of the Royal College of Surgeons of England* 1990, 72 (2): 99-100. |