



A case Report on Variant Arterial Pattern on Palm And its Clinical Significance

KEYWORDS

superficial palmar arch, ulnar artery, median artery, collateral circulation, hand surgery, plastic surgeon, vascular graft applications arterial repairs, free and pedicled flaps.

Dr. Sharadkumar Pralhad Sawant

Associate Professor, Department of Anatomy, K. J. Somaiya Medical College, Somaiya Ayurvihar, Eastern Express Highway, Sion, Mumbai-400 022.

ABSTRACT During routine dissection for the undergraduate first MBBS students on the right upper limb of a 70 years old donated embalmed male cadaver in the Department of Anatomy, K.J. Somaiya Medical College, Sion, Mumbai, India, we observed a variant complete superficial palmar arch. The superficial palmar arch was formed by the ulnar artery on medial side and completed by the median artery on the lateral side. The photographs of the variant complete superficial palmar arch were taken for proper documentation and ready reference. There was no associated neuromuscular variations in the same specimen. The formation of the deep palmar arch was normal. The variation was unilateral and the arterial pattern of the left upper limb of the same cadaver was normal. The knowledge of variation in the persistence of median artery helps in planning and performance of surgical procedures in the forearm. The median artery is the only arterial supply to the median nerve. Damage to this artery therefore has clinical significance. Association of a persistent median artery with the median nerve should be considered in the evaluation of all patients with carpal tunnel syndrome. The variations of the vascular pattern of the hand gained more importance in microsurgical techniques, reconstructive hand surgeries, preoperative screening of radial artery harvesting for myocardial revascularization and also in arterial interventions that include radial artery cannulation and radial artery forearm flap.

Introduction:

The general pattern of arterial supply of the hand consists of two systems for the volar aspect and a single system for the dorsal aspect. The volar supply is arranged into a superficial and a deep group i.e., superficial palmar arch and deep palmar arch. The superficial palmar arch is mainly fed by the ulnar artery, passing superficial to the flexor retinaculum, then curving laterally to form an arch, lying just deep to the palmar aponeurosis. About one third of the superficial palmar arch is formed by the ulnar artery alone; a further third is completed by the superficial palmar branch of the radial artery; and a third by the radial artery, often a branch of the princeps pollicis artery, or by the median artery (1). The superficial palmar arch is an arterial arcade and a dominant vascular structure of the palm. It is localized just deep to palmar aponeurosis and is superficial to digital branches of the median nerve, long flexor tendons of the forearm and lumbricals of the palm (2). The arch is formed by superficial terminal branch of the ulnar artery and can be completed on lateral side by superficial palmar branch of the radial artery or the princeps pollicis artery or the radial artery (1). From the convexity of superficial palmar arch three common palmar digital arteries will arise and each one divides into two proper palmar digital arteries. These run along the contiguous sides of all four medial fingers to supply them. The palmar digital artery for the medial side of the little finger leaves the arch under palmaris brevis. The radial side of the index finger is supplied by the radial artery (1). The anastomoses between the radial and the ulnar arteries through superficial and deep palmar arches in the palm play a significant role through collateral circulation in the diseases of the palm. Knowledge of the frequency of anatomical variations of the arterial pattern of the hand is crucial for safe and successful hand surgeries (4). The median artery is a transitory vessel that represents the arterial axis of the forearm during the early embryonic life and normally regresses in the 2nd embryonic month. However its incidence is reported as ranging between 1.5-27.1% (5). The persistent median artery in the human adult has been described in two different patterns: as a large, long vessel i.e. palmar type which reaches the hand or as a small and

short vessel which end before reaching the wrist joint i.e. antebrachial type.

Case Report:

During routine dissection for the undergraduate first MBBS students on the right upper limb of a 70 years old donated embalmed male cadaver in the Department of Anatomy, K.J. Somaiya Medical College, Sion, Mumbai, India, we observed a variant complete superficial palmar arch. In the present case superficial palmar arch was formed by the ulnar and median arteries without the contribution of radial artery or any of its branches. The median artery is a transitory vessel that represents the arterial axis of the forearm during the early embryonic life. It normally regresses before birth. The persistent median artery was the continuation of the common interosseous artery. It was running medial to the median nerve. It entered the hand deep to flexor retinaculum and terminated by completing superficial palmar arch. The ulnar artery entered the palm by coursing in front of the flexor retinaculum, just distal to the retinaculum it gave a deep branch and continued as the superficial palmar arch. But it was an incomplete arch, occupying almost normal position. It supplied palmar aspect of all the fingers including thumb and index finger. It gave a digital branch to the ulnar side of the little finger, three common palmar digital branches to supply adjacent sides of medial four fingers. The palmar digital artery for the medial side of the little finger leaves the arch under palmaris brevis. The radial side of the index finger is supplied by the radial artery and the thumb is supplied by the princeps pollicis artery both of these are branches of the radial artery. The superficial branch of radial artery was small and terminated by nourishing the thenar muscles. However the deep palmar arch was complete and normal. The deep palmar arch was formed by the direct continuation of the radial artery on lateral side and completed by the deep branch of the ulnar artery on medial side. The deep palmar arch is the only communication between the radial artery and the ulnar artery which formed the major channel for collateral circulation. The photographs of the incomplete superficial palmar arch were taken for proper documentation and ready reference. There was no associated neuromuscular variations in the same specimen. The formation of the deep palmar arch was normal. The variation was unilateral and the arterial pattern of the left upper limb of the same cadaver was normal.

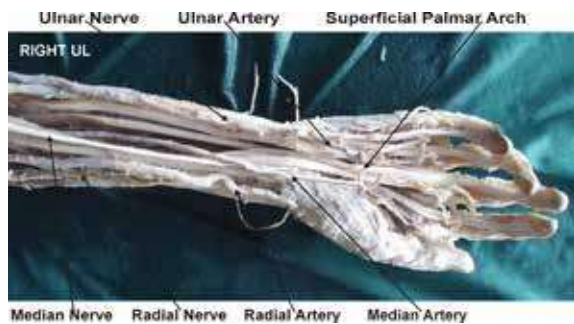


Figure showing the photographic presentation of a variant superficial palmar arch. The ulnar and the radial arteries are the terminal branches of the brachial artery while the persistent median artery is the continuation of common interosseous artery. The variant superficial palmar arch formed by the ulnar artery and the median artery without the contribution of radial artery or any of its branches on right side.

Discussion:

The superficial palmar arch is the anastomosis formed by the ulnar artery, entering the palm with the ulnar nerve, anterior to the flexor retinaculum and lateral to the pisiform, passing medial to the hamate's hook, then curving laterally to form an arch, convex distally across the middle 1/3rd of the palm, and in level with a transverse line through the distal border of the fully extended pollicial base (1, 6, 7). The superficial palmar arch is covered by the palmaris brevis and palmar aponeurosis and it is superficial to the flexor digiti minimi, branches of the median nerve and to the long flexor tendons and lumbrical muscles (8). The traditional definition of superficial palmar arch consists of linkage between the superficial palmar branch of the radial artery and ulnar artery (9). Although the radial and ulnar arteries provide most of the blood supply to the hand, additional circulation may come from the median artery or the interosseous arterial system (10). The superficial palmar arch is a direct continuation of the ulnar artery (11). It gives four palmar digital arteries, the medial most supplies the medial side of little finger and is termed as the proper palmar digital artery. The other three are common palmar digital arteries which pass to the medial three interdigital clefts (12). There is a report of superficial palmar branch of the radial artery terminating in the thenar muscles without any contribution to the superficial palmar arch (13). It is extremely difficult to establish a type, due to the large number of variations in the superficial palmar arch (14). Gellman et al. classified the superficial palmar arch into two categories as complete and incomplete. A complete arch will be an anastomosis between vessels constituting it. There will be an absence of a communication or anastomosis between the vessels constituting an incomplete arch. In the present case the ulnar artery anastomose with the median artery and hence the superficial palmar arch was Gellman's complete type. This classification is simple and understandable for many anatomists and researchers and is currently in use (15). Adachi has described 3 types of superficial palmar arch (16). Type A : Ulnar type - in which contribution by radial artery is absent or minimal, Type B : Radioulnar type - in which arch is formed by the superficial palmar branch of radial artery and the larger ulnar artery, Type C : Mediano ulnar type - in which arch is formed by the median artery and the larger ulnar artery. The superficial palmar arch observed in the present case is Adachi's Type C i.e. Mediano ulnar type. Huber (17) classified the superficial palmar arch into 2 types. Type 1 in which additional branches from the forearm participate in the formation of the arch or replace the radial in its composition. Type 2 in which there is no true arch, the arteries which should participate in its formation and in some cases the additional ones also, failing to anastomose and each giving rise independently to a certain number of digital branches in a somewhat fan like manner. The superficial palmar arch seen in the present case is Huber's Type 1. Coleman and Anson (18) elaborated more on superficial palmar arch and reclassified it as follows : Group I : Complete arch. It

can be further divided into five types :- Type A : The classical radio ulnar arch is formed by superficial palmar branch of radial artery and the larger ulnar artery. Type B : This arch is formed entirely by ulnar artery. Type C : Mediano ulnar arch is composed of ulnar artery and an enlarged median artery. Type D : Radio-mediano-ulnar arch in which 3 vessels enter into the formation of arch. Type E : It consists of a well formed arch initiated by ulnar artery and completed by a large sized vessel derived from deep arch. The latter vessel comes to superficial level at the base of the thenar eminence of join the ulnar artery. Group II : Incomplete arch : When the contributing arteries to the superficial arch do not anastomose or when the ulnar artery fails to reach the thumb and index finger, the arch is incomplete. It can be further divided into 4 types. Type A : Both superficial palmar branch of radial artery and ulnar artery take part in supplying palm and fingers but in doing so, fail to anastomose. Type B : Only the ulnar artery forms superficial palmar arch. The arch is incomplete in the sense that the ulnar artery does not take part in the supply of thumb and index finger. Type C : Superficial vessels receive contributions from both median and ulnar arteries but without anastomosis. Type D : Radial, median and ulnar artery all give origin to superficial vessels but do not anastomose. The superficial palmar arch seen in the present case is Coleman and Anson's Group I and Type C. The persistent median artery observed in the present case is palmar type. The median artery in its palmar pattern passes under the flexor retinaculum, running in the carpal tunnel together with the median nerve and flexor tendons. This relationship has been considered as an etiological factor in carpal tunnel syndrome which is a compressive neuropathy of median nerve and present with paraesthesia of fingers in the median nerve distribution, weakness or atrophy of thenar muscle and typical nocturnal burning and aching pain. The incidence in which persistent median artery was apparent cause of carpal tunnel syndrome has been reported as 1.8%-6% (19). Since the superficial palmar arch is the main source of arterial supply to the palm, the details about its possible variations is important for the hand surgeons. The knowledge is important while performing the superficial dissections and to the radiologists while performing the angiographic procedures. The morphology of arterial arches of hand is important for microvascular surgeons as well as orthopaedicians (20). The clamping of radial artery is contraindicated in cases of deficient collateral flow through the ulnar artery, as it can lead to ischemia and gangrene of the fingers (21). The patients should be screened before harvesting the radial artery to confirm the presence of a viable collateral circulation in the hand (9). It is mandatory to conduct the investigations like Allen test, angiography and colour doppler studies of the hand before starting any invasive procedures including the vascular surgeries. The knowledge about these variant arches is essential for the safe and successful outcome of the hand surgeries. The recent advances in microsurgical techniques for the reconstruction of hand and upper extremity after trauma and congenital deformities have necessitated better understanding of the vascular patterns of the vessels. The doppler and angiographic studies allow visualization of vessels of the hand, but do not accurately assess the small connecting vessels (22, 23, 24, 25). The hand surgeon needs to refer to the existence and healthy functioning of the arch before surgical procedures such as, arterial repairs, vascular graft applications. The radial artery contributes greatly to the circulation of the hand but in many cases it can be removed as a non-essential vessel, with adequate circulation being provided by the remaining ulnar and in some cases, persistent median artery (26).

Developmental Basis:

Initially, the limb bud has only capillary networks. The first axial vessel appears in stage 14 as a border (marginal) vein that follows the posterior (ulnar) side of the developing limb. Later, this marginal vein is retained as the subclavian-axillary-basilic axis. Lymphatic vessels follow the veins. The subclavian-axillary-brachial axis arteries appear during stages 15 and 16. The brachial artery gives rise to the interosseous and median arteries. The median arteries become the main blood supply to the hand. The ulnar artery

appears before the radial artery, during stages 17 and 18, respectively. Normally, the ulnar and radial arteries replace the median artery within the hand, and the median artery regresses to serve as the blood supply to the median nerve (27, 28, 29). Senior (1926) described the development of arteries of upper limb in five stages. Stage 1: The subclavian artery, the vessel of 7 intersegmental artery, extends to the wrist as axis artery and terminates by dividing into terminal branches for fingers. Distal portion of the artery becomes interosseous artery of adult. Stage 2: Median artery arises from the interosseous artery as a sprout and becomes larger. It fuses with the lower portion of interosseous artery to form principle artery of forearm. Interosseous artery subsequently undergoes retrogression. Stage 3: In embryos of 18mm, ulnar artery arises from brachial artery and unites distally with the median artery to form superficial carpal arch. Digital branches arise from this arch. Stage 4: The superficial brachial artery develops. Stage 5: In embryos of 23 mm, median artery undergoes retrogression becoming a small slender structure, now known as *arteria comitans nervi mediani*. The superficial brachial artery gives off distal branches which anastomose with the superficial palmar arch already present. Thus, the persistent of median artery in the human adult has been described as retention of the embryonic pattern, while the antebrachial pattern represents its partial regression. The ontogenic explanation of variations of superficial palmar arch was documented (30, 31). The comparative study of arteries of hands in primates confirmed that the variations noted in man represent a retention or reappearance of primitive patterns (32). In the embryological parallelism, ontogeny recapitulates phylogeny. By the stage 21 of the embryo, the radial artery acquires its final differentiated state (33). The arterial variations affecting the distal course of the radial artery must have established before the 21st week of gestational stage (21, 34). The anomalies of blood vessels may be due to the choice of unusual paths in the primitive vascular plexues, the persistence of vessels normally obliterated, the disappearance of vessels normally retained, incomplete development, fusion and absorption of the parts usually distinct (34).

Clinical significance:

Knowledge of variations of vascular patterns of hand gained more importance in microsurgical techniques, reconstructive hand surgeries, preoperative screening of radial artery harvesting for myocardial revascularization and also in arterial interventions that include radial artery cannulation and radial artery forearm flap. These variations are compared with the earlier data & it is concluded that variations in the vascular pattern of hand are a rule rather than an exception. A lack of knowledge of such type of variations with different patterns might complicate reconstruction hand surgeries (35).

Conclusion:

Scientific improvement can be achieved by thorough knowledge of anatomical variations. The detailed knowledge about the complex anatomical structures in the hand and upper extremity is essential for verifying the validity of various surgical procedures under practice and to define new. The knowledge of variation in the persistence of median artery helps in planning and performance of surgical procedures in the forearm. When a persistent median artery is patent and reaches the hand, it forms the only arterial supply to the median nerve. Damage to this artery could have serious effects and has clinical significance. Association of a persistent median artery with the median nerve should be considered in the evaluation of all patients with carpal tunnel syndrome.

Competing interests:

The author declare that he has no competing interests.

Acknowledgement:

Author is also thankful to Dean Dr. Geeta Niyogi Madam for her support and encouragement. Author is also thankful to Dr. Arif A. Faruqi and Mr. M. Murugan for their help. Author also acknowledge the immense help received from the scholars whose articles are cited and included in references of this manuscript. The author is also grateful to authors / editors / publishers of all those articles, journals and books from where the literature for this article has been reviewed and discussed.

REFERENCE

1. Johnson D, Ellis H, Collins P. Wrist and hand. In: Standing S, Ellis H, Healy JC, Johnson D, Williams A, eds. *Gray's Anatomy*. 39th Ed., Edinburgh, Churchill Livingstone. 2005, pp. 929-930. | 2. Gajisin S, Zbrodowski A. Local vascular contribution of the superficial palmar arch. *Acta Anat (Basel)*, 1993, Vol.147, pp. 248-251. | 3. Datta AK. *Essentials of human anatomy. Superior and inferior extremities*. 2nd Ed., Calcutta, Current Books International, 2000, pp. 99-100. | 4. Jelcic N, Gajisin S, Zbrodowski A. Arcus palmaris superficialis. *Acta Anat (Basel)*. 1988, Vol. 132, pp. 187-190. | 5. Sanudo JR, Chikwe J, Evans SE. Anamolous median nerve associated with persistent median artery. *J Anat*, 1994, Vol. 185, pp. 447-451. | 6. Massie, G.: *Surgical Anatomy In: The Upper Limb* 4th Edn. J. & A Churchill Ltd. London, 1944, pp. 177-8. | 7. Boyd, J.D.; Clark, W.E.; Hamilton, W.J.; Yoffey, J.M.; Zuckerman, S; Appleton, A.B.: *Textbook of Human Anatomy In: Cardiovascular system. Blood Vessels*. Mcmillan & Co. Ltd. New York, 1956, pp. 341-346. | 8. Anson, B.J. & Maddock, W.G.: *Callender's Surgical Anatomy In: The hand-palmar region*. 3rd Edn. W.B. Saunders Co. Philedelphia, 1952, pp. 831. | 9. Ruengsakulrach R, Eizenberg N, Fahrer, C, Fahrer M. and Buxton BF, Surgical implications of variations in hand collateral circulation: Anatomy revisited. *The Journal of Thoracic and Cardiovascular Surgery*, 2001, vol. 122, no. 4, pp. 682-686. | 10. Ruengsakulrach P, Eizenberg N, Fahrer C, Fahrer M, Buxton BF. Surgical implications of variations in hand collateral circulation: Anatomy revisited. *J Thorac Cardiovasc Surg* 2001, Vol. 122, pp. 682-686. | 11. Snell RS, *Clinical Anatomy*. 7th ed. Baltimore: Lippincott Williams and Wilkins, 2004, pp. 545. | 12. Romanes G.J: *Cunningham's Mannual of Practical Anatomy In: The Upper limb- The forearm & Hand*. Vol. I, 15th Edn. Oxford University Press, Oxford, 2012, pp. 74-104. | 13. Bataineh ZM, Moqattash ST. A complex variation in the superficial palmar arch. *Folia Morphol (Warsz)*, 2006, Vol. 65, pp. 406-409. | 14. Poirier, P: *Traite d' Anatomie Humaine* L. Battalle & Co. Paris, 1886, pp 833. | 15. Gellman H, Botte MJ, Shankwiler J, Gelberman RH. Arterial patterns of the deep and superficial palmar arches. *Clin Orthop Relat Res*. 2001, Vol. 383, pp. 41-46. | 16. Adachi, B: *Das arterien system des japaner*, Kyoto, 1928, pp. 365, 368, 389. | 17. Huber, G.C.: *Piersol's Human Anatomy. In: The Vascular System*. 9th Edn. Vol. I, J.B. Lippincot Co. Philadelphia, 1930, pp. 785-91. | 18. Coleman SS, Anson BJ. Arterial patterns in the hand based upon the study of 650 specimens. *Surg Gynecol Obstet*, 1961, Vol. 113, pp. 409-424. | 19. Fumiere E, Dugardeyn C, Roquet M E, Delcour C. U S demonstration of a thrombosed persistent median artery in carpal tunnel syndrome, *JBRBTR*, 2002; Vol. 85, pp. 1-3. | 20. Patnaik VVG, Kalsey G. and Singla RK, Palmar arterial arches- a morphological study. *Journal of Anatomical Society of India*, 2002, vol. 51, no. 2, pp. 187-193. | 21. Ottone NE, Prum N, Dominguez M, Blasi E, Medan C, Shinzato S, Finkelstein D. and Bertone VH. Analysis and clinical importance of superficial arterial palmar irrigation and its variants over 86 cases. *International Journal of Morphology*, 2010, vol. 28, no. 1, pp. 157-164. | 22. Ikeda A, Ugawa A, Kazihara Y, Hamada N. Arterial patterns in the hand based on a three-dimensional analysis of 220 cadaver hands. *J Hand Surg* 1988, Vol 13, pp. 501-509. | 23. Al-Turk M, Metcalf WK. A study of the superficial palmar arteries using the Doppler Ultrasonic Flowmeter. *S.D.Ü. Týp Fak. Derg*, 2007, Vol. 14, no.2, pp. 11-16 | 24. Taðýl, Superficial palmar arch *J Anat* 1984, Vol. 138, pp. 27-32. | 25. Starnes SL, Wolk SW, Lampman RM, Shanley C., Prager RL, Kong BK, Fowler JJ, Page JM, Babcock SL, Lange LA, Erlandson EE, Whitehouse WM. Noninvasive evaluation of hand circulation before radial artery harvest for coronary artery bypass grafting. *J Thorac Cardiovasc Surg*, 1999, Vol. 117, pp. 261-266. | 26. Starnes SL, Wolk SW, Lampman RM, Shanley C., Parger RL, Kong BK, Fowler JJ, Page JM, Babcock. Noninvasive evaluation of hand circulation before radial artery harvest for coronary artery bypass grafting. *Journal of Thoracic & Cardiovascular Surgery*, 1999, Vol. 117, pp. 261-266. | 27. Zaleske DJ. Development of the upper limb. *Hand Clin*, 1985, Vol. 1, pp. 383-390. | 28. Kimura S, Shiota K. Sequential changes of programmed cell death in developing fetal mouse limbs and its possible roles in limb morphogenesis. *J Morphol* 1996, Vol. 229, pp. 337-346. | 29. Mohammad M. Al-Qattan, Yingzi Yang, Scott H. Kozin, *Embryology of the Upper Limb*, *J Hand Surg* 2009, Vol. 34 A, pp. 1340-1350. | 30. Meyer, H. Con, *Der Grand typus des Rete, der Handnurzels und des Fusswurzels*. *Archives of Anatomy & Physiology*, 1881, Vol. 45, pp. 23-64. | 31. Singer E, *Embryological patterns persisting in the arteries of the arm*. *Anatomical Record*, 1933, Vol. 55, pp. 406-413. | 32. Manners Smith, T. (). *The Limb arteries of the primates*. *Journal of Anatomy & Physiology*, 1910, Vol. 45, pp. 23-64. | 33. Rodriguez-Niedenfuhr M, Burton GJ, Deu J. and Sanudo JR, Development of the arterial pattern in the upper limb of staged human embryos: normal development and anatomic variations. *Journal of Anatomy*, 2001, vol. 199, no. 4, p. 407-417. | 34. Arey, L.B. : *Developmental anatomy In: Development of the arteries*. 6th Edn W.B. Saunder's Co. Philadelphia, 1957, pp. 375-377. | 35. Treves, F.B. & Rogers, L.: *Surgical Applied Anatomy. In: The Upper Extremity*. 11th Edn. Cassell & Co. London, 1947, pp. 265- 266. |