



**Dr. Sharadkumar Pralhad Sawant<sup>1</sup>, Dr. Shaguphta T. Shaikh<sup>2</sup>, Dr. S.D. Lele<sup>3</sup>, Dr. Shaheen Rizvi<sup>4</sup>, Dr.S.R. Menon<sup>5</sup>, Dr. R. Uma<sup>6</sup>.**

<sup>1,2,3,4,5,6</sup>Department of Anatomy, K. J. Somaiya Medical College, Somaiya Ayurvihar, Eastern Express Highway, Sion, Mumbai

Email id -

[dr.sharadsawant@yahoo.com](mailto:dr.sharadsawant@yahoo.com)

## **A CASE REPORT ON VARIANT MUSCULOCUTANEOUS AND ULNAR NERVE OBSERVED IN THE RIGHT UPPER LIMB.**

### **ABSTRACT**

During routine dissection of a 70 years old embalmed male cadaver in the department of Anatomy at K. J. Somaiya Medical College, Sion, Mumbai, INDIA, the unusual origin of musculocutaneous and ulnar nerve from median nerve were observed in the right upper limb. The variant median nerve crossed the brachial artery from behind. The thorough and meticulous dissection of axilla, arm, forearm and palm of both the upper limbs were done to note the course of the median nerve. The variation was unilateral and the left upper limb was normal. The arterial pattern in the arm was also normal. The photographs of the variations were taken for proper documentation. The median nerve and its roots are close to the axillary vein, which is used as the most cranial limit for axillary lymph node dissection, a procedure used in treating certain tumours, such as breast carcinoma and melanoma. The variations in the formation, course & distribution of median nerve are clinically important for surgeons, orthopaedicians and anaesthetist performing pain management therapies on the upper limb. These variations are compared with the earlier data & it is concluded that variations in the median nerve are a rule rather than exception. A lack of awareness of variations with different patterns might complicate surgical repair and may cause ineffective nerve blockade.

**Key words:** Musculocutaneous Nerve, Ulnar Nerve, Median Nerve, Breast Carcinoma, Surgeons, Pain Management Therapy.

## INTRODUCTION

The median nerve is normally formed by the union of lateral root of median nerve arising from the lateral cord (C5, C6, C7) of brachial plexus and medial root of median nerve arising from the medial cord (C8, T1) of brachial plexus anterior to the axillary artery. Some fibres from C7 often leave the lateral root to join the ulnar nerve. Clinically they are believed to be mainly motor to the flexor carpi ulnaris. The median nerve enters the arm at first lateral to the brachial artery. Near the insertion of the coracobrachialis, it crosses in front of the artery, descending medial to it, to the cubital fossa, where it is posterior to the bicipital aponeurosis and anterior to the brachialis. It usually enters the forearm between the heads of the pronator teres, crossing to the lateral side of the ulnar artery and separated from it by the deep head of pronator teres (1). The ulnar nerve arises as a branch of the medial cord, but it often receives fibres from the lateral root of the median nerve. Like the median nerve, the ulnar nerve has no branches in the arm, but it also supplies articular branches to the elbow joint (2). It enters the forearm between the two heads of the flexor carpi ulnaris superficial to the posterior and oblique parts of the ulnar collateral ligament. The high percentage of anomalies as mentioned above emphasizes the complexities and irregularities of this anatomic region with regard to surgical approaches (3). Knowledge of such variations is important for surgeons to perform surgical procedures in the axillary region and arm (4). Considering the high percentage of anomalies in the formation of median nerve and its paramount clinical importance, the present variations are documented. Variations in the formation and branching pattern of the brachial plexus constitute an important anatomical and clinical entity and have been reported by several investigators (5, 6, 7). The median, musculocutaneous and ulnar nerves after their origin from the brachial plexus, pass through the anterior compartment of the arm without receiving any branch from any nerve in the neighbourhood (8). Although the communications between the different nerves in the arm are rare, those between the median nerve and musculocutaneous nerve have been described from nineteenth century (9). Knowledge of anatomical variation of these nerves at the level of upper arm is essential in light of the frequency with which surgery is performed in the axilla and the surgical neck of the humerus (10).

### Case Report:

During routine dissection of a 70 years old embalmed male cadaver in the department of Anatomy at K. J. Somaiya Medical College, Sion, Mumbai, INDIA, the unusual origin of musculocutaneous and ulnar nerve from median nerve were observed in the right upper limb. The variant median nerve crossed the brachial artery from behind. The thorough and meticulous dissection of axilla, arm, forearm and palm of both the upper limbs were done to note the course of the median nerve. The variation was unilateral and the left upper limb was normal. The arterial pattern in the arm was also normal. The photographs of the variations were taken for proper documentation.

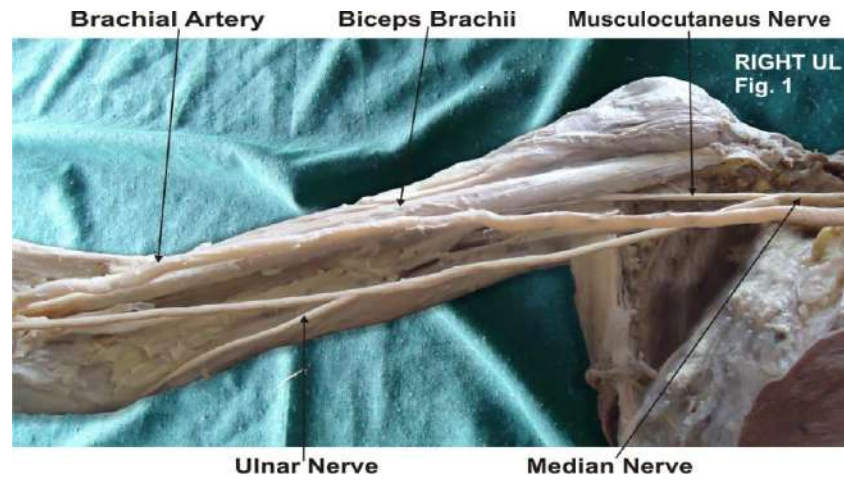


Figure – 1 : Photographic presentation of the unusual origin of the musculocutaneous and the ulnar nerve from the median nerve. The variant median nerve crossed the brachial artery from behind.

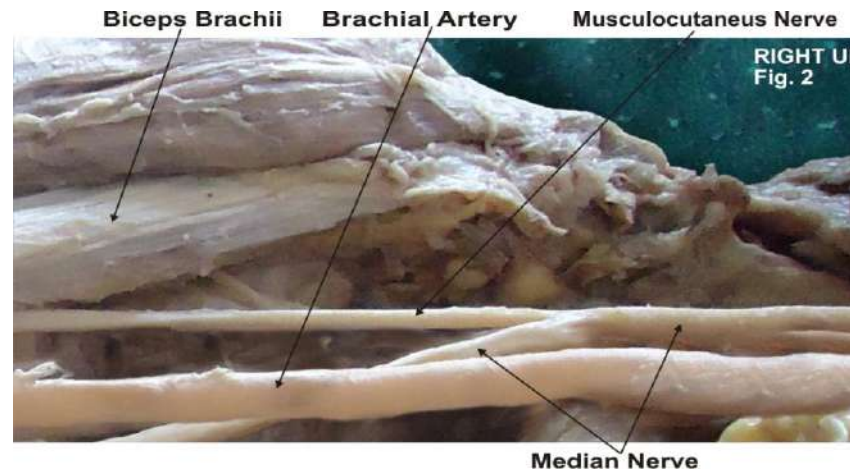


Figure – 2 : Photographic presentation of the formation of the median nerve by the medial and the lateral root. The musculocutaneous is originated from the median nerve.

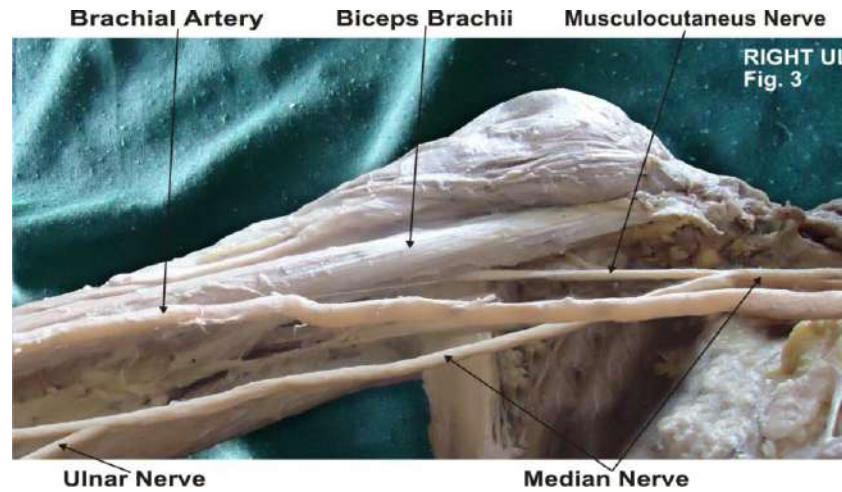


Figure – 3 : Photographic presentation of the variant formation and course of the median nerve in the right arm.

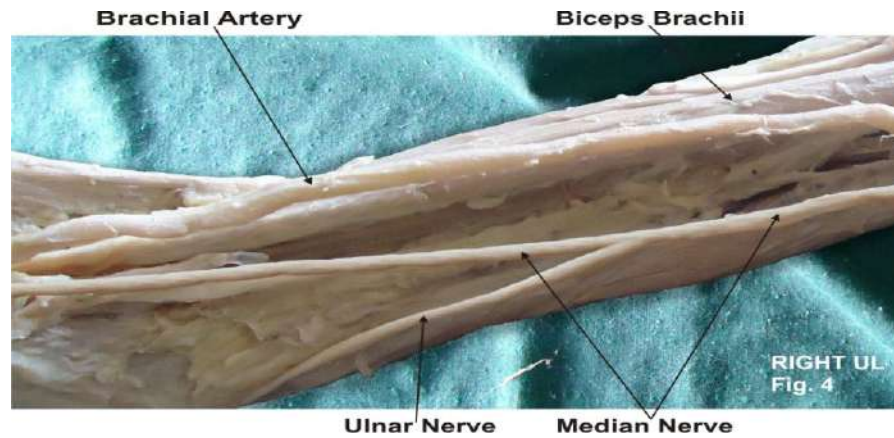
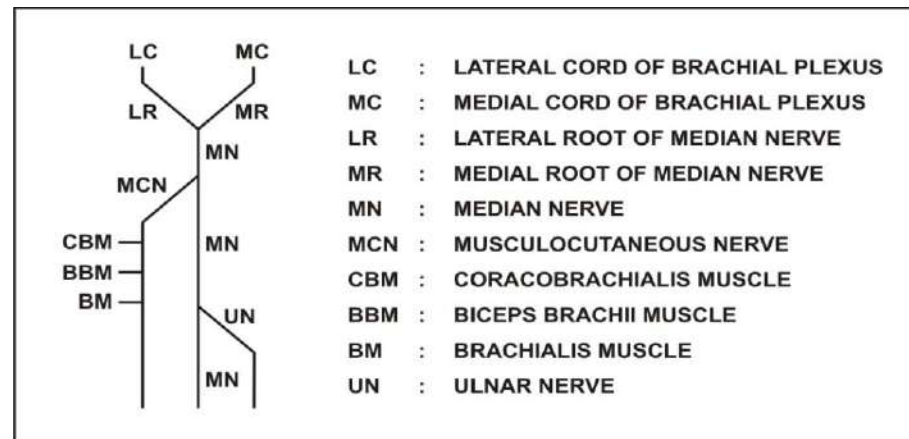


Figure – 4 : Photographic presentation of the origin of the ulnar nerve from the median nerve in the lower part of the arm.

**DISCUSSION:**

Neural variations of the brachium constitute an important anatomical and clinical entity. Although frequently reported, if accompanied by other anomalies, they deserve special mention in anatomical literature. The nerves of the extremities are especially vulnerable to injury because of their long course and superficial distribution. The variations related to the formation of median nerve were found in literature. The variations related to the formation of median nerve by more than two roots are relatively uncommon as compared to the other types of variations of median nerve. Most of the variations were related to anomalous relationship between median and musculocutaneous nerves. As found in literature, it was documented that the lateral root was small and the musculocutaneous nerve was connected with median nerve in the arm (1). Another study involving dissection of ten cadavers, mentioned failure of separation of musculocutaneous nerve from the median nerve and the latter therefore gave off the branches that should arise from musculocutaneous nerve, namely branches to coracobrachialis, biceps brachii and major part of brachialis (11). Anastomosis between the musculocutaneous nerve and the median nerve is by far the most common and frequent of all the variations that are observed among the branches of the brachial plexus (12). The communication between the musculocutaneous nerve and the median nerve have been classified in different types by Venieratos and Anagnostopoulou, Choi *et al* and Li Minor (12, 13, 14). Many variational patterns of the branches of the brachial plexus have been described earlier. These include the absence of the posterior cord, merging of all the cords to form a single cord (15), the ulnar nerve arising from the posterior cord (16) and the communication between the median and the ulnar nerves (17).



An anomalous median-to-ulnar nerve forearm communication, which is known as the Martin-Gruber anastomosis, has been well reported in the literature. The reverse of the Martin-Gruber anastomosis, with a ulnar-to-median nerve forearm communication, which is known as the Marinacci communication, has been also reported in the literature (18). However, none of the authors have commented upon a variation where the entire ulnar nerve originated from the median nerve. In the present case the musculocutaneous nerve and the ulnar nerve originated from the median nerve. Apart from the surgeons, the variations in the nerves which supply the upper limb are of interest, not only to the radiologists who interpret plain

computerized imagings and MRI and anesthesiologists who place needles in the neck to administer anaesthetic blocks, but also to the neurosurgeons, neurologists, vascular surgeons and orthopaedic surgeons (19).

#### **Ontogeny:**

Anomalous pattern of the median nerve can be explained on the basis of embryological development. The upper limb buds lie opposite the lower five cervical and upper two thoracic segments. As soon as the buds form, the ventral primary rami of the spinal nerves penetrate into the mesenchyme of limb bud. Immediately the nerves enter the limb bud, they establish intimate contact with the differentiating mesodermal condensations and the early contact between nerve and muscle cells is a prerequisite for their complete functional differentiation (2). The growth as well as the path finding of nerve fibres towards the target is dependent upon concentration gradient of a group of cell surface receptors in the environment (1). Several signalling molecules and transcription factors have been identified which induce the differentiation of the dorsal and ventral motor horn cells (20).

#### **Phylogeny:**

In amphibians, reptiles, birds, monotremes, dogs, primates in general and in anthropoid apes with poorly developed hand structures, the ulnar and the median nerves were undifferentiated and that a single nerve trunk supplied the region (21). This condition is especially marked in the wing of the bird. In reptiles, the two nerves are formed from the trunk, although at a distance, peripherally. The actual differentiation of the ulnar nerve is evident in the monotremes and marsupials, in which the forelimbs are better developed and have a greater range of action. Conversely, the nerves to the compressed forefeet of dogs are fused or anastomosed for a greater part of their extent. The differentiation of the separate ulnar and median nerves are more definite in higher animals with well developed forelimbs. The pattern which was observed in the present case was similar to the patterns which were usually observed in lower animals like reptiles and dogs. The anomalies at the high humeral level of the brachial plexus may present as a complicating factor during a surgical attempt to cause a nerve blockade. At high humeral levels, the median nerve descends from the axilla in close proximity to the brachial artery, frequently lying just lateral to the artery. Likewise, the ulnar nerve remains close to the artery to this point and is especially found just medial to the artery (22). But in a case like ours, when the ulnar nerve originates at a distal level from the median nerve; an attempted ulnar nerve block at a proximal level may fail or an attempted median nerve blockade may result in an associated ulnar nerve blockade. An effective brachial plexus blockade requires a thorough understanding of the anatomy of the plexus, as well as an appreciation of the anatomical variations that may occur. Variant nerve communications may cause ineffective nerve blockade and also, the blockade of unexpected areas. During a surgical procedure, such variations may lead to possible complications. Therefore, it is very important to know all the variants of the brachial plexus for a successful regional nerve blockade and operations.

#### **Clinical significance**

The anatomical variation described here has practical implications, since injury to the median nerve in the axilla or arm would, in this case, have caused unexpected paresis or paralysis of the flexor musculature of the elbow and hypoesthesia of the lateral surface of the forearm, in addition to the classical signs that are already well known. Injury to the median nerve could occur in cases of open or closed trauma to the arm, such as bullet and blade wounds or during surgeries on the axilla or arm. The median nerve and its roots are close to the axillary vein, which is used as the most cranial limit for axillary

lymph node dissection, a procedure used in treating certain tumours, such as breast carcinoma and melanoma. If the dissection extends more cranially than normal, injury to the median nerve (or to its medial root) may occur, with consequent dysfunction of the flexor musculature of the elbow if the anatomical variation described here is present. It would not be unlikely for such accidents to occur even with the most eminent surgeons, considering that the classical concept is that the median nerve does not give rise to branches in the arm (23). The clinical relevance of such variations might also be correlated to entrapment syndromes. Entrapment of musculocutaneous nerve is rare and has its origin either in physical activity (24) or in violent passive movements of arm and forearm (25).

**CONCLUSION :**

The presence of such type of variations are clinically important for surgeons, orthopaedicians and anaesthetist performing pain management therapies on the upper limb. These variations are compared with the earlier data & it is concluded that variations in branching pattern of cords of brachial plexus are a rule rather than exception.

**Competing interests:**

The authors declare that they have no competing interests.

**Authors' contributions:**

SPS wrote the case report, performed the literature review & obtained the photograph for the study. SDL, UR performed the literature search, SR assisted with writing the paper. STS conceived the study and SRM helped to draft the manuscript. All authors have read and approved the final version manuscript.

**ACKNOWLEDGEMENT:**

All the authors are thankful to Dr. Arif A. Faruqui for his support. We are also thankful to Mr. M. Murugan for his help. Authors also acknowledge the immense help received from the scholars whose articles are cited and included in references of this manuscript. The authors are also grateful to authors / editors / publishers of all those articles, journals and books from where the literature for this article has been reviewed and discussed.



## REFERENCES:

1. Williams P.L., Bannister L.H., Berry M.M. et al. Gray's Anatomy. 39th ed. London Churchill Livingstone, 2005: 231-232, 803-4, 877, 1270.
2. Moore KL, Dalley AF. Clinically oriented anatomy. 5 Ed., Baltimore, Lippincott Williams and Wilkins, 2006; p. 794, 819-822.
3. Edglseder WA JR, Goldman M. Anatomic variations of the musculocutaneous nerve in the arm. Amer J Orthop 1997; 26: 777-80.
4. Uysal II, Seker M, Karabulut AK, Buyukmumcu M, Ziylan T. Brachial plexus variation in human fetuses. Neurosurgery 2003; 53: 676-84; discussion 684.
5. Kerr, AT. The brachial plexus of nerves in man, the variations in its formation and branches. American Journal of Anatomy, 1918, vol. 23, n. 2, p. 285-395.
6. Miller, RA. Comparative studies upon the morphology and distribution of the brachial plexus. American Journal of Anatomy, 1934, vol. 54, n. 1, p. 143-166.
7. Bergman, RA., Afifi, AK., Miyauchir, RA. Illustrated encyclopedia of human anatomic variation. In: NERVOUS system - plexuses. 1988.
8. Hollinshead, WH. Functional anatomy of the limbs and back. 4th ed. Philadelphia: W.B. Saunders, 1976. p. 134-140.
9. Harris, W. The true form of the brachial plexus. Journal of Anatomy and Physiology, 1904, vol. 38, p. 399-422. PMID:17232613. PMCID:1287350.
10. Leffert, RD. Anatomy of the brachial plexus. New York: Churchill Livingstone, 1985. p 384.
11. Guha R, Palit S. A rare variation of anomalous median nerve with absent musculocutaneous nerve and high up division of brachial artery. J Interacad 2005; 9: 398-403.
12. Venieratos, D., Anagnostopoulou, S. Classification of communications between the musculocutaneous and median nerves. Clinical Anatomy, 1998, vol. 11, p. 327-331.
13. Choi, D., Rodriguez-Niedenfuhr, M., Vazquez, T., Parkin, I., Sanudo, JR. Patterns of connections between the musculocutaneous and median nerves in the axilla and arm. Clinical Anatomy, 2002, vol. 15, n. 1, p. 11-17.
14. Li Minor, JM. A rare variant of median and musculocutaneous nerves in man. Archives Anatomy Histology Embryology, 1992, vol. 73, p. 33-42.
15. Pandey SK and Kumar S. Anomalous formation of the brachial plexus cords and the median nerve. In: Jethani SL, editor. J Anat Soc Ind 2004. Proceedings of the 5th Annual Conference of the Anatomical Society of India; 2003 Dec; Ahmedabad, Gujarat. India; 2004.p.31.
16. Goncalves J, Duparc F, Auquit- Auckbur I, Milliez PY. Constitutional anomalies of the terminal branches of the brachial plexus in the axial and the brachial regions. Results of 42 cases and review of literature. Ann Chir Plast Esthet 2002; 47(1): 30-5.
17. Kazakos KJ, Smyrnis A, Xarchas KC, Dimitrakopoulou A, Verettas DA. Anastomosis between the median and the ulnar nerve in the forearm. An anatomical study and literature review. Acta Orthop Belg 2005; 71: 29- 35.
18. Meenakshi-Sundaram S, Sundar B, Arunkumar MJ. Marinacci communication: an electrophysiological study. Clin Neurophysiol 2003 Dec; 114(12): 2334- 37.
19. Collins JD, Shaver ML, Disher AC, Miller TQ. Compromising abnormalities of the brachial plexus as displayed by magnetic resonance imaging. Clin Anat 1995; 8: 1-16.
20. Saddle T.W. Langman's Medical Embryology. In: Muscular system. 10th ed. Philadelphia Lippincott Williams and Wilkins, 2006: 146-147.
21. Miller RA. Comparative studies on the morphology and the distribution of the brachial plexus. Am J Anat 1934; 54(1):143-66.



22. Stanescu S, Post J, Ebraheim NA, Bailey AS, Yeasting R. Surgical anatomy of the radial nerve in the arm: practical considerations of the branching patterns to the triceps brachii. *Orthopedics* 1996; 19: 311-15.
23. Fregnani, JHTG., Macéa, MIM., Pereira, CSB., Barros, MD., Macéa, JR. Absence of the musculocutaneous nerve: a rare anatomical variation with possible clinical-surgical implications. *Sao Paulo Medical Journal*, 2008, vol. 126, n. 5, p. 288-90.
24. Falsenthal, G., Mondell, DL., Reischer, MA., Mack, RH. Forearm pain secondary to compression syndrome of the lateral cutaneous nerve of the forearm. *Archaeological Physical Medical Rehabilitation*, 1984, vol. 65, p. 139-141.
25. Kim, SM., Goodrich, JA. Isolated proximal musculocutaneous nerve palsy: Case report. *Archaeological Physical Medical Rehabilitation*, 1984, vol. 65, p. 735-736.