



Dr. Sharadkumar Pralhad Sawant¹, Dr. Shaguphta T. Shaikh², Dr. S.D. Lele³, Dr. Shaheen Rizvi⁴, Dr.S.R. Menon⁵, Dr. R. Uma⁶.

^{1,2,3,4,5,6}Department of Anatomy, K. J. Somaiya Medical College, Somaiya Ayurvihar, Eastern Express Highway, Sion, Mumbai

Email id -

dr.sharadsawant@yahoo.com

A CASE REPORT ON THE VARIATION IN THE FORMATION OF THE MEDIAN NERVE.

ABSTRACT

During routine dissection of a 70 years old embalmed male cadaver in the department of Anatomy at K. J. Somaiya Medical College, Sion, Mumbai, INDIA, the formation of the median nerve by medial and lateral roots in the middle of the arm was observed in the right upper limb. The lateral root crossed the brachial artery anteriorly from lateral to medial side and joined with the medial root to form the median nerve in the middle of the arm. The thorough and meticulous dissection of axilla, arm, forearm and palm of both the upper limbs were done to note the course of the median nerve. The variation was unilateral and the left upper limb was normal. The arterial pattern in the arm was also normal. The photographs of the variations were taken for proper documentation.

Conclusion :

The median nerve and its roots are close to the axillary vein, which is used as the most cranial limit for axillary lymph node dissection, a procedure used in treating certain tumours, such as breast carcinoma and melanoma. The variations in the formation, course & distribution of median nerve are clinically important for surgeons, orthopaedicians and anaesthetist performing pain management therapies on the upper limb. These variations are compared with the earlier data & it is concluded that variations in the median nerve are a rule rather than exception. A lack of awareness of variations with different patterns might complicate surgical repair and may cause ineffective nerve blockade.

KEY WORDS : Axilla, Brachial plexus, Median Nerve, Brachial Artery, Musculocutaneous nerve, Mid arm position, Breast Carcinoma, Surgeons, Pain Management Therapy.

INTRODUCTION

The median nerve is normally formed by the union of lateral root of median nerve arising from the lateral cord (C5, C6, C7) of brachial plexus and medial root of median nerve arising from the medial cord (C8, T1) of brachial plexus anterior to the axillary artery. Some fibres from C7 often leave the lateral root to join the ulnar nerve. Clinically they are believed to be mainly motor to the flexor carpi ulnaris. The median nerve enters the arm at first lateral to the brachial artery. Near the insertion of the coracobrachialis, it crosses in front of the artery, descending medial to it, to the cubital fossa, where it is posterior to the bicipital aponeurosis and anterior to the brachialis. It usually enters the forearm between the heads of the pronator teres, crossing to the lateral side of the ulnar artery and separated from it by the deep head of pronator teres (1). Anomalous pattern of the median nerve can be explained on the basis of embryological development. The upper limb buds lie opposite the lower five cervical and upper two thoracic segments. As soon as the buds form, the ventral primary rami of the spinal nerves penetrate into the mesenchyme of limb bud. Immediately the nerves enter the limb bud, they establish intimate contact with the differentiating mesodermal condensations and the early contact between nerve and muscle cells is a prerequisite for their complete functional differentiation (2). The growth as well as the path finding of nerve fibres towards the target is dependent upon concentration gradient of a group of cell surface receptors in the environment (1). Several signalling molecules and transcription factors have been identified which induce the differentiation of the dorsal and ventral motor horn cells. The high percentage of anomalies as mentioned above emphasizes the complexities and irregularities of this anatomic region with regard to surgical approaches (3). Knowledge of such variations is important for surgeons to perform surgical procedures in the axillary region and arm (4). Considering the high percentage of anomalies in the formation of median nerve and its paramount clinical importance, the present variations are documented.

Variations in the formation and branching pattern of the brachial plexus constitute an important anatomical and clinical entity and have been reported by several investigators (5,6,7). The median, musculocutaneous and ulnar nerves after their origin from the brachial plexus, pass through the anterior compartment of the arm without receiving any branch from any nerve in the neighbourhood (8). Although the communications between the different nerves in the arm are rare, those between the median nerve and musculocutaneous nerve have been described from nineteenth century (9). Knowledge of anatomical variation of these nerves at the level of upper arm is essential in light of the frequency with which surgery is performed in the axilla and the surgical neck of the humerus (10).

Case Report:

During routine dissection of a 70 years old embalmed male cadaver in the department of Anatomy at K. J. Somaiya Medical College, Sion, Mumbai, INDIA, the formation of the median nerve by medial and lateral roots in the middle of the arm was observed in the right upper limb. The lateral root crossed the brachial artery anteriorly from lateral to medial side and joined with the medial root to form the median nerve in the middle of the arm. The thorough and meticulous dissection of axilla, arm, forearm and palm of both the upper limbs were done to note the course of the median nerve. The variation was unilateral and the left upper limb was normal. The arterial pattern in the arm was also normal. The photographs of the variations were taken for proper documentation.

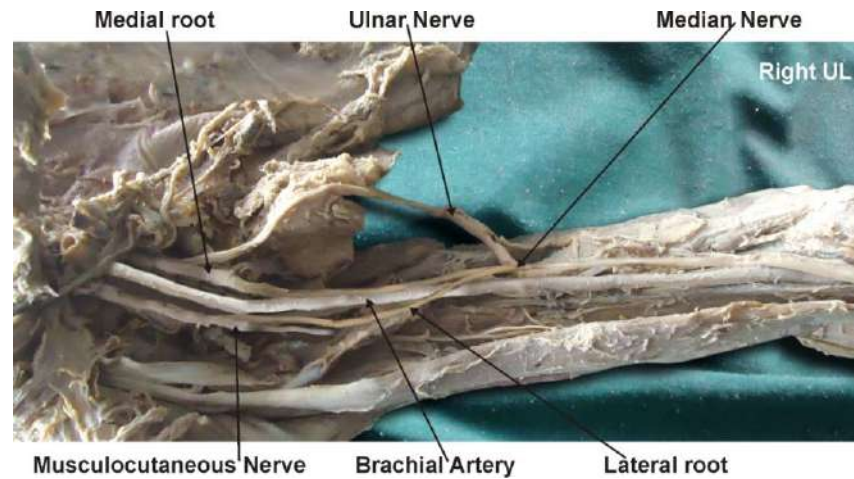
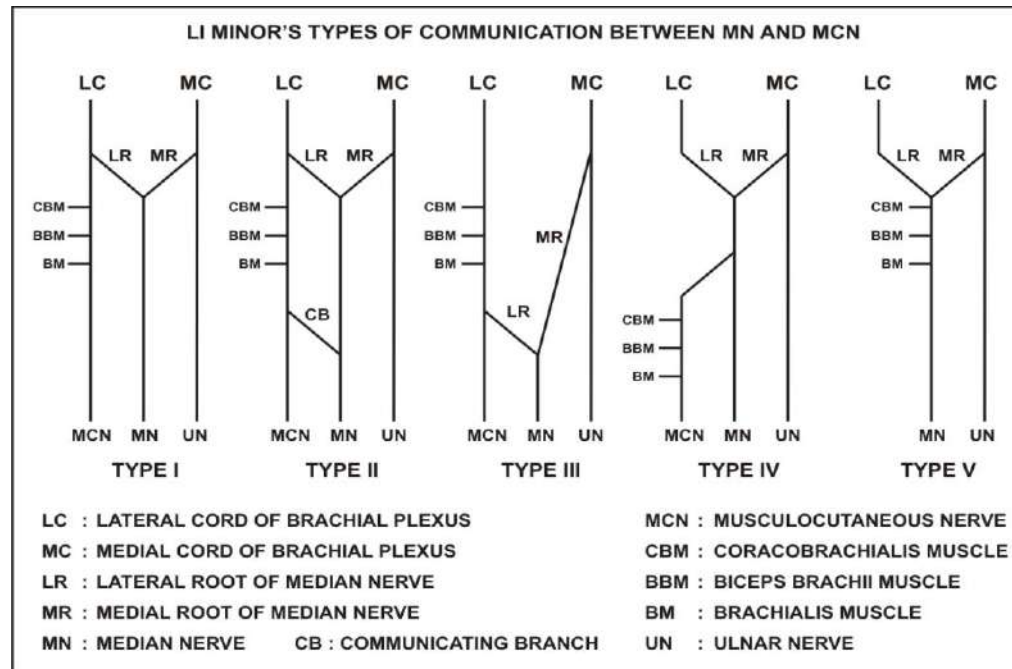


Fig. : Photographic presentation of the formation of the median nerve in the middle of the arm.

DISCUSSION :

Anastomosis between the musculocutaneous nerve and the median nerve is by far the most common and frequent of all the variations that are observed among the branches of the brachial plexus (11). The communication between the musculocutaneous nerve and the median nerve have been classified in different types by Venieratos and Anagnostopoulou, Choi et al and Li Minor (11,12,13). Li Minor categorized these communications into following five types: In type I, there is no communication between the median nerve and the musculocutaneous nerve, in type II, the fibers of the lateral root of the median nerve pass through the musculocutaneous nerve and join the median nerve in the middle of the arm, whereas in type III, the lateral root fibers of the median nerve pass along the musculocutaneous nerve and after some distance, leave it to form the lateral root of the median nerve. In type IV, the musculocutaneous nerve fibers join the lateral root of the median nerve and after some distance the musculocutaneous nerve arises from the median nerve. In type V, the musculocutaneous nerve is absent and the entire fibers of the musculocutaneous nerve pass through the lateral root and fibers to the muscles supplied by the musculocutaneous nerve branch out directly from the median nerve (14). In the present case the formation of the median nerve by medial and lateral roots in the middle of the arm i.e. "Type III" of Li Minor's classification.



Choi *et al.* (12) classified the communication between the musculocutaneous nerve and the median nerve into three types. In Type I there is fusion of both nerves. In Type II there is supplementary branch between both nerves. This type was further subdivided as Type II a, where a single root from musculocutaneous nerve, contributes to the connection while in Type II b there are two roots from musculocutaneous nerve. In Type III there are two branches between both nerves. The most frequent variation is the presence of a communicating branch that emerges from the musculocutaneous nerve and goes distally to join the median nerve, an anastomosis observed in the lower third of arm (7, 11). In the present case the lateral root fibers of the median nerve pass along the musculocutaneous nerve and after some distance, leave it to form the lateral root of the median nerve i.e. "Type II a" of Choi's classification. Venieratos and Anagnostopoulou (11) also described three different types of communication between musculocutaneous and median nerve in relation to coracobrachialis muscle. Type 1: communication between musculocutaneous and median nerve is proximal to the entrance of musculocutaneous into coracobrachialis. Type 2: communication between the two nerves is distal to the muscle. Type 3: neither the nerve nor its communicating branch pierced the muscle. In the present case the communication between musculocutaneous and median nerve is distal to the entrance of musculocutaneous nerve into coracobrachialis muscle i.e. Type 2 of Venieratos and Anagnostopoulou's classification.

Ontogeny :

The presence of anastomosis between the median nerve and the musculocutaneous nerve may be attributed to random factors influencing the mechanism of formation of limb muscles and the peripheral nerves during embryonic life. Significant variations in nerve patterns may be a result of altered signaling between mesenchymal cells and neuronal growth cones (15) or circulatory factors at the time of fusion of brachial plexus cords (16). Iwata believed that the human brachial plexus appears as a single radicular cone in the upper limb bud, which divides longitudinally into ventral and the dorsal segments (17). The ventral segments give roots to the median and the ulnar nerves with musculocutaneous nerve arising from the median nerve. He further kept the possibility of failure of the differentiation as a cause for some of the fibers taking an aberrant course as a communicating branch. Chiarapattanakom *et al.* (18) are of the opinion that the limb muscles develop from the mesenchyme of local origin, while axons of spinal nerves grow distally to reach the muscles and/or skin. They blamed the lack of coordination between the formation of the limb muscles and their innervation for appearance of a communicating branch.

Phylogeny :

Studies of comparative anatomy have observed the existence of such connections in monkeys and in some apes; the connections may represent the primitive nerve supply of the anterior arm muscles (6). Chauhan *et al* strongly recommend the consideration of the phylogeny and the development of the nerves of the upper limb for the interpretation of the nerve anomalies of the arm (19). Considering the communication between the musculocutaneous and the median nerve as a remnant from the phylogenetic or comparative anatomical point of view and that the ontogeny recapitulates the phylogeny, they feel that the variations seen are the result of the developmental anomaly.

Clinical significance

The anatomical variation described here has practical implications, since injury to the median nerve in the axilla or arm would, in this case, have caused unexpected paresis or paralysis of the flexor musculature of the elbow and hypoesthesia of the lateral surface of the forearm, in addition to the classical signs that are already well known. Injury to the median nerve could occur in cases of open or closed trauma to the arm, such as bullet and blade wounds or during surgeries on the axilla or arm. The median nerve and its roots are close to the axillary vein, which is used as the most cranial limit for axillary lymph node dissection, a procedure used in treating certain tumors, such as breast carcinoma and melanoma. If the dissection extends more cranially than normal, injury to the median nerve (or to its medial root) may occur, with consequent dysfunction of the flexor musculature of the elbow if the anatomical variation described here is present. It would not be unlikely for such accidents to occur even with the most eminent surgeons, considering that the classical concept is that the median nerve does not give rise to branches in the arm (20). The clinical relevance of such variations might also be correlated to entrapment syndromes. Entrapment of musculocutaneous nerve is rare and has its origin either in physical activity (21) or in violent passive movements of arm and forearm (22). This knowledge of anastomosis between the musculocutaneous nerve and the median nerve may prove useful for clinicians in order to avoid an unnecessary carpal tunnel release (23, 24, 25, 26, 27).

CONCLUSION :

The presence of such type of variations are clinically important for surgeons, orthopaedicians and anaesthetist performing pain management therapies on the upper limb. These variations are compared with the earlier data & it is concluded that variations in branching pattern of cords of brachial plexus are a rule rather than exception.

Competing interests:

The authors declare that they have no competing interests.

Authors' contributions:

SPS wrote the case report, performed the literature review & obtained the photograph for the study. SDL, UR performed the literature search, SR assisted with writing the paper. STS conceived the study and SRM helped to draft the manuscript. All authors have read and approved the final version manuscript.

ACKNOWLEDGEMENT:

All the authors are thankful to Dr. Arif A. Faruqui for his support. We are also thankful to Mr. M. Murugan for his help. Authors also acknowledge the immense help received from the scholars whose articles are cited and included in references of this manuscript. The authors are also grateful to authors / editors / publishers of all those articles, journals and books from where the literature for this article has been reviewed and discussed.

REFERENCES

1. Williams P.L., Bannister L.H., Berry M.M. et al. Gray's Anatomy. In: Nervous System. 38th ed. London Churchill Livingstone, 1999: 231-232,1270.
2. Sandler T.W. Langman's Medical Embryology. In: Muscular system. 10th ed. Philadelphia Lippincott Williams and Wilkins, 2006: 146-147.
3. Edgleder WA JR, Goldman M. Anatomic variations of the musculocutaneous nerve in the arm. *Amer J Orthop* 1997; 26: 777-80.
4. Uysal II, Seker M, Karabulut AK, Buyukmumcu M, Ziyilan T. Brachial plexus variation in human fetuses. *Neurosurgery* 2003; 53: 676-84; discussion 684.
5. Kerr, AT. The brachial plexus of nerves in man, the variations in its formation and branches. *American Journal of Anatomy*, 1918, vol. 23, n. 2, p. 285-395.
6. Miller, RA. Comparative studies upon the morphology and distribution of the brachial plexus. *American Journal of Anatomy*, 1934, vol. 54, n. 1, p. 143-166.
7. Bergman, RA., afifi, AK., Miyauchir, RA. Illustrated encyclopedia of human anatomic variation. In: *NERVOUS system - plexuses*. 1988.
8. Hollinshead, WH. Functional anatomy of the limbs and back. 4th ed. Philadelphia: W.B. Saunders, 1976. p. 134-140.
9. Harris, W. The true form of the brachial plexus. *Journal of Anatomy and Physiology*, 1904, vol. 38, p. 399-422. PMID:17232613. PMCID:1287350.
10. Leffert, RD. Anatomy of the brachial plexus. New York: Churchill Livingstone, 1985. 384 p.

11. Venieratos, D., Anagnostopoulou, S. Classification of communications between the musculocutaneous and median nerves. *Clinical Anatomy*, 1998, vol. 11, p. 327-331.
12. Choi, D., Rodriguez-Niedenfuhr, M., Vazquez, T., Parkin, I., Sanudo, JR. Patterns of connections between the musculocutaneous and median nerves in the axilla and arm. *Clinical Anatomy*, 2002, vol. 15, n. 1, p. 11-17.
13. Li Minor, JM. A rare variant of median and musculocutaneous nerves in man. *Archives Anatomy Histology Embryology*, 1992, vol. 73, p. 33-42.
14. Loukas, M., Aqueelah, H. Musculocutaneous and median nerve connections within, proximal and distal to the coracobrachialis muscle. *Folia Morphologica (Warsz)*, 2008, vol. 64, n. 2, p. 101-8.
15. Abhaya, A., Bhardwaj, R., Prakash, R. Dual origin of musculocutaneous nerve. *Journal of Anatomical Society of India*, 2003, vol. 52, n. 1, p. 94.
16. Kosugi, K. Mortia, T., Yamashita, H. Branching pattern of the musculocutaneous nerve. 1. Cases possessing normal biceps brachii. *Jikeikai Medical Journal*, 1986, vol. 33, p. 63-71.
17. Iwata, H. Studies on the development of the brachial plexus in Japanese embryo. *Republic Department Anatomy Mie Prefect University School of Medicine*, 1960, vol. 13, p. 129-144.
18. Chiarapattanakom, P., Leechavengvons, S., Witoonchart, K., Uerpairojkit, C., Thuvasethakul, P. Anatomy and internal topography of the musculocutaneous nerve: The nerves to the biceps and brachialis muscle. *Journal of Hand Surgery*, 1998, vol. 23A, p. 250-255.
19. Chauhan, R., Roy, TS. Communication between the median and musculocutaneous nerve: A case report. *Journal of Anatomical Society of India*, 2002, vol. 51, n. 1, p. 72-75.
20. Fregnani, JHTG., Macéa, MIM., Pereira, CSB., Barros, MD., Macéa, JR. Absence of the musculocutaneous nerve: a rare anatomical variation with possible clinical-surgical implications. *Sao Paulo Medical Journal*, 2008, vol. 126, n. 5, p. 288-90.
21. Falsenthal, G., Mondell, DL., Reischer, MA., Mack, RH. Forearm pain secondary to compression syndrome of the lateral cutaneous nerve of the forearm. *Archaeological Physical Medical Rehabilitation*, 1984, vol. 65, p. 139-141.
22. Kim, SM., Goodrich, JA. Isolated proximal musculocutaneous nerve palsy: Case report. *Archaeological Physical Medical Rehabilitation*, 1984, vol. 65, p. 735-736.
23. M Watanabe, M., Takatsuji, K., Sakamoto, N., Morit, Y., Ito, H. Two cases of fusion of the musculocutaneous and median nerves. *Kalbo gaki Zasshi*, 1985, vol. 60, p. 1-7.
24. Guerri- Guttenberg, RA., Ingolotti, M. Classifying musculocutaneous nerve variations. *Clinical Anatomy*, 2009, vol. 22, n. 6, p. 671-83.
25. Maeda, S., Kawai, K., Koizumi, M., Ide, J., Tokiyoshi, A., Mizuta, H., Kodama, K. Morphological study of the communication between the musculocutaneous and median nerves. *Anatomical Science International*, 2009, vol. 84, n. 1-2, p. 34-40.
26. Saritha, S. Variations in the median and musculocutaneous nerves-A surgical prospective. *Journal of Anatomical Society of India*, 2004, vol. 53, n. 1, p. 31-66.
27. Uzun, A., Seelig, LL. A variation in the formation of the median nerve: communicating branch between the musculocutaneous and median nerves in man. *Folia Morphologica (Warsz)*, 2001, vol. 60, n. 2, p. 99-101.

