

CASE REPORT

A Case Report on Variant Ulnar Artery

Sharadkumar P Sawant, Shaguphta T Shaikh, Rakhi M More

Department of Anatomy, KJ Somaiya Medical College, Sion, Mumbai

Correspondence to: Sharadkumar P Sawant (dr.sharadsawant@yahoo.com)

Received Date: 16.09.2012

Accepted Date: 26.09.2012

DOI: 10.5455/ijmsph.2012.1.143-146

ABSTRACT

During routine dissection for 1st MBBS students on 65 year old donated embalmed male cadaver in the Department of Anatomy, K.J.Somaiya Medical College, Sion, Mumbai, India, we observed an unusual branch of the brachial artery. The brachial artery terminated in the cubital fossa into radial and common interosseous arteries. The radial artery had normal course and branches. The common interosseous artery was deeper and gave anterior and posterior ulnar recurrent arteries, and terminated into anterior and posterior interosseous arteries. The unusual large branch from the brachial artery was a variant of ulnar artery, arose from the lateral side of the brachial artery, descended on the lateral side upto the cubital fossa and crossed the fossa from lateral to medial, superficial to median nerve. It then descended superficial to the muscles arising from medial epicondyle of the humerus and was covered by the deep fascia of the forearm, pierced the deep fascia proximal to the wrist, crossed the flexor retinaculum, and formed the superficial palmar arch. Throughout its course, this artery gave no branch. There was no associated altered anatomy of the nerves observed in the specimen. The left upper limb of the same cadaver was normal. The photographs of the variations were taken for proper documentation and for ready reference. The embryological basis of the variation is presented.

Key Words: Brachial Artery; Superficial Antebrachial Artery; Superficial Brachial Artery; Superficial Ulnar Artery; Ulnar Artery

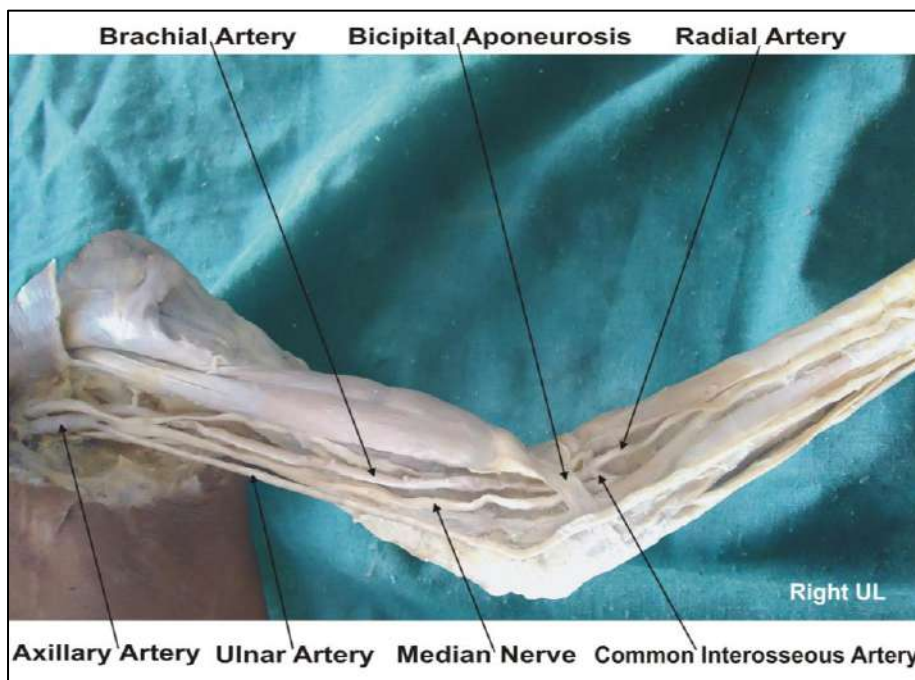
INTRODUCTION

The brachial artery ends in the cubital fossa by dividing into radial and ulnar arteries. At the elbow, the ulnar artery sinks deeply into the cubital fossa and reaches the medial side of the forearm midway between elbow and wrist. The common interosseous artery is a short branch of the ulnar, passes back to the proximal border of the interosseous membrane and divides into anterior and posterior interosseous arteries. Anterior interosseous artery descends on the anterior aspect of the interosseous membrane with the median nerve's anterior interosseous branch. Median artery, a slender branch from anterior interosseous artery, accompanies and supplies the median nerve.^[1]

CASE REPORT

During routine dissection for 1st MBBS students on 65 year old donated embalmed male cadaver in the Department of Anatomy, K.J.Somaiya Medical College, Sion, Mumbai, India, we observed an unusual branch of the right brachial artery. The brachial artery terminated in the cubital fossa into radial and common interosseous arteries. The radial artery had normal course and branches. The common interosseous artery was deeper and gave anterior and posterior ulnar recurrent arteries, and terminated into anterior and posterior interosseous arteries. The unusual large branch from the brachial artery was a variant of ulnar artery, arose from the lateral side of the brachial artery, descended on the lateral side upto the

Figure 1: The Photographic Presentation of the Unusual Origin of the Ulnar Artery from the Brachial Artery in the Axilla of Right Upper Limb



cubital fossa and crossed the fossa from lateral to medial, superficial to median nerve. It then descended superficial to the muscles arising from medial epicondyle of the humerus and was covered by the deep fascia of the forearm, pierced the deep fascia proximal to the wrist, crossed the flexor retinaculum, and formed the superficial palmar arch. Throughout its course, this artery gave no branch. There were no associated altered anatomies of the nerves observed in the specimen. The left upper limb of the same cadaver was normal. The photographs of the variations were taken for proper documentation and for ready reference. The photographs were taken for proper documentation.

Observations: The unusual large branch from the brachial artery was a variant of ulnar artery, arose from the lateral side of the brachial artery in the axilla of right upper limb.

DISCUSSION

The variations in branching pattern of axillary artery are a rule rather than exception.^[2-16] Variant branches may arise from the brachial artery.^[17] Ulnar artery was found to deviate from its usual mode of origin in one in thirteen

cases; frequently it sprang from the lower part of the brachial artery; the position of the ulnar artery in the forearm was more frequently altered; in cases of high origin, it invariably descended over the muscles arising from the medial epicondyle of the humerus and was covered by the deep fascia of the forearm.^[2] The present case of ulnar artery is somewhat similar to the variations presented in Quain's Anatomy.^[2] If the brachial artery is taken to terminate into radial and ulnar arteries, the embryological basis of the existing ulnar artery and the origin and course of the unusual branch of the brachial artery, replacing the ulnar artery in the present case, is as follows. Primitive axis artery and superficial brachial artery are implicated in the morphogenesis of the arteries of the upper limb.^[3,18] The seventh cervical intersegmental artery forms the axis artery of the upper limb and persists in the adult to form the axillary, brachial, and interosseous arteries. Transiently, the median artery arises as a branch of the interosseous artery, begins to regress and remains as a residual artery accompanying the median nerve.^[18] Radial and ulnar arteries are later additions to the axis artery.^[8] A superficial brachial artery is a consistent embryonic vessel, coexisting or not

with the brachial artery.^[19] It has two terminal branches, a lateral that continues as a part of the definitive radial artery.^[20] and a medial, superficial antebrachial artery, which divides into median and ulnar artery branches, which are the trunks of origin of the median and ulnar arteries. These trunks of deep origin predominate and the superficial arteries regress.^[8] In the present case, the axis artery had formed the interosseous artery and given the trunks of the median and ulnar arteries. The ulnar branch of the superficial antebrachial artery persists independently, without its usual anastomosis to the branch of the axis artery, as the large lateral branch of the brachial artery and the superficial ulnar artery, which is found in the distal part of the forearm and joins the superficial palmar arch. If the brachial artery is taken to terminate into radial and interosseous arteries, the simpler embryological basis of the interosseous artery and the origin and course of the unusual branch of the brachial artery, replacing the ulnar artery, is the following. It appears probable that the abnormal arrangement results from early obstruction of the ulnar artery below the origin of the interosseous, and the development of a superficial vas aberrans, which replaces the portion of vessel below the obstruction and unites with the brachial. The interosseous artery in such cases of abnormality thus comprises not only the interosseous artery but also the portion of ulnar artery above the obstruction. and, in accordance with this view, the recurrent branches are derived from it.^[2] The present anomaly is very rare and does not seem to have been reported. This case is of significance. Such an artery may present a superficial pulse and a hazard to venipuncture^[21] and lead to intra-arterial injections or ligature instead of the vein in the cubital fossa^[22,23] Variation in the branching pattern of the brachial artery is of significance in cardiac catheterization for angioplasty, pedicle flaps, arterial grafting or brachial pulse.

CONCLUSION

The knowledge of presence of the unusual origin of the ulnar artery from the brachial artery in

the axilla may be clinically important for clinicians, surgeons, orthopaedicians and radiologists performing angiographic studies. Undoubtedly, such variations are important for diagnostic evaluation and surgical management of vascular diseases and injuries. These variations are compared with the earlier data & it is concluded that variations in branching pattern of axillary artery are a rule rather than exception. Therefore both the normal and abnormal anatomy of the region should be well known for accurate diagnostic interpretation and therapeutic intervention.

ACKNOWLEDGEMENT

All the authors wish to convey thanks to Dr. Arif A. Faruqui for his valuable support. We are also thankful to Mr. M. Murugan. Authors also acknowledge the immense help received from the scholars whose articles are cited and included in references of this manuscript. The authors are also grateful to authors / editors / publishers of all those articles, journals and books from where the literature for this article has been reviewed and discussed.

REFERENCES

1. Williams, P.L.; Bannister, L.H. Berry M.M; Collins, P., Dyson, M. Dussek, J.E., Ferguson, M.W.J.: Gray's Anatomy, In : Cardiovascular system. Gabella, G. Edr. 39th Edn, 2000, Churchill Livingstone, London, Edinburgh pp: 1537-1540.
2. Thane, G. D. Quain's elements of Anatomy. In : Arthrology- Myology-Angiology. 10th Edn; 1892, Longman, Green, and Co. London : 445.
3. Schwyzer, A.G. and DeGaris, C.F : Three diverse patterns of the arteria brachialis superficialis in man, 1935, Anatomical Record 63 : 405- 416.
4. Mc Cormack, L.J. Caldwell, M.D. and Anson, B.J.: Brachial antebrachial arterial patterns, 1953 Surgery Gynecology and Obstetrics 96 : 43-54.
5. Coleman S.S. and Anson, B.J. : Arterial patterns in the hand based upon a study of 650 specimens Surgery Gynecology and Obstetrics, 196, 113 : 409-424.
6. Lippert, H. and Pabst, R: Arterial variations in Man. Bergmann, Munich; 1985, pp. 66-73.
7. Poteat, W.L. : Report of a rare human variation : Absence of the radial artery, 1986, Anatomical Record 214 : 89-95.

8. Rodriguez-Baeza, A. Nebot, J., Ferreira, B., Reina, F, Perez, J., Sanudo, J.R. and Rolg, M. : An anatomical study and ontogenic explanation of 23 cases with variations in the main pattern of the human brachio-antebrachial arteries, 1995, *Journal of Anatomy* 187 : 473-479.
9. Aharinejad S., Nourani F. and Hollensteiner H. : Rare case of high origin of ulnar artery from the brachial artery, 1997, *Clinical Anatomy* 10: 253-258.
10. Patnaik, V.V.G., Kalsey, G. and Singla, R.K. : Anomalous course of radial artery and a variant of deep palmar arch: A case report. *Journal of the Anatomical Society of India*, 2000, 49(1) : 54-57.
11. Patnaik, V.V.G., Kalsey, G. and Singla, R.K. : Superficial palmar arch duplication : A case report. *Journal of the Anatomical Society of India*, 2000, 49(1) : 63-66.
12. Patnaik, V.V.G., Kalsey, G. and Singla, R.K. : Trifurcation of brachial artery-A case report. *Journal of the Anatomical Society of India*, 2001, 50(2) : 163-165.
13. Patnaik V.V.G. Kalsey G. and Singla R.K. : Bifurcation of axillary artery in its 3rd part-A case report. *Journal of the Anatomical Society of India*, 2001, 50(2) : 166-169.
14. Celik, H.H., Germus, G., Aldur, M.M. and Ozcelik, M. : Origin of the radial and ulnar arteries : variation in 81 arteriograms, 2001, *Morphologie* 85 : 25-27.
15. Clerve, A., Kahn M., Pangilinan, A.J. and Dardik, H. : Absence of the brachial artery : report of a rare human variation and review of upper extremity arterial anomalies, 2001, *Journal of Vascular Surgery* 33 : 191-194.
16. Suganthy J., Koshy S., Indrasingh I. and Vettivel S. : A very rare absence of radial artery : A case report, 2002, *Journal of the Anatomical society of India* 51(1) : 61-64.
17. Huber G.C.: Piersol's Human Anatomy. In : The vascular system 9th Edn. 1930, Vol 1, J. B. Lippincott Co. Philadelphia. pp. 767-791.
18. Singer E. : Embryological pattern persisting in the arteries of the arm, 1933, *Anatomical Record* 55 : 403-409.
19. Tountas, CH.P. and Bergman, R.A. : Anatomic Variations of the upper extremity. Churchill Livingstone, 1993, New York. pp. 196-210.
20. Vancov V. : Une variete extremement complexe des arteres du member superieur chez un foetus humain, 1961, *Anatomischer anzeiger* 109 : 400-405.
21. Hazlett J.W. : Superficial ulnar artery with reference to accidental intra-arterial injection, 1949, *Canadian Medical Association Journal* 61 : 289-293.
22. Pabst R. and Lippert H. : Belderseitiges Vorkommen von A. brachialis superficialis, ulnaris superficialis and A. mediana, 1968, *Anatomischer Anzieger* 123 : 223-226.
23. Thoma, A. and Young, J.E.M. : The superficial ulnar artery "trap" and the free forearm flap, 1992, *Annals of Plastic Surgery* 28 : 370-372.

Cite this article as: Sawant SP, Shaikh ST, More RM. A case report on variant ulnar artery. *Int J Med Sci Public Health* 2012; 1:143-146.

Source of Support: Nil

Conflict of interest: None declared