



A CASE REPORT ON AN ADDITIONAL MUSCLE SLIP OF FLEXOR CARPI ULNARIS WITH VARIANT ULNAR ARTERY AND ULNAR NERVE IN THE FOREARM.

Sharadkumar Pralhad Sawant

Department of Anatomy, K. J. Somaiya Medical College, Somaiya Ayurvihar, Eastern Express Highway, Sion, Mumbai-400 022

ABSTRACT: During routine dissection, of the right upper limb of a 70 years old donated embalmed male cadaver in the Department of Anatomy, K.J. Somaiya Medical College, Sion, Mumbai, India, we observed an additional muscle slip of flexor carpi ulnaris associated with variant ulnar artery and ulnar nerve in the forearm. The additional belly originated from the lower part of the flexor carpi ulnaris muscle and crossed the ulnar nerve, the ulnar vessels and the median nerve. The additional belly merged with the flexor retinaculum and the tendon of palmaris longus muscle. The ulnar nerve divided into the terminal branches in the upper part of the forearm. However, the distribution of the terminal branches of ulnar nerve was normal in the palm. The ulnar artery runs superficial to the superficial flexor muscles of the forearm. The variations were unilateral and the left upper limb was normal. The photographs of the triple variations were taken for proper documentation.

Clinical significance: The awareness of additional muscle slip of the flexor carpi ulnaris associated with variant ulnar artery and ulnar nerve in the forearm is clinically important for surgeons dealing with entrapment or compressive neuropathies, orthopaedicians operating on the fractures of the radius or ulna or both and anaesthetist performing pain management therapies on the upper limb. A lack of knowledge of such type of variations with different patterns might complicate surgical repair and may cause ineffective nerve blockade.

Keywords: Flexor Carpi Ulnaris, Additional Muscle Slip, Ulnar Nerve, Ulnar Artery, Median Nerve, High Division of Dorsal Branch of Ulnar Nerve, Surgeons, Entrapment, Orthopaedicians, Fractures of Radius or Ulna, Anaesthetist, Pain Management Therapy.

INTRODUCTION

Flexor carpi ulnaris muscle is the most medial superficial flexor muscle of forearm. It arises by two heads, humeral and ulnar, connected by a tendinous arch. The small humeral head arises from the medial epicondyle via the common superficial flexor origin. The ulnar head has an extensive origin from the medial margin of the olecranon process and proximal two-thirds of the posterior border of the ulna, an aponeurosis which it shares with the extensor carpi ulnaris and flexor digitorum profundus and from the intermuscular septum between it and flexor digitorum superficialis. A thick tendon forms along its anterolateral border in its distal half. The tendon is attached to the pisiform, and thence prolonged to the hamate and fifth metacarpal bone by pisohamate and pisometacarpal ligaments. The blood is supplied to the flexor carpi ulnaris muscle by the ulnar collateral arteries, the anterior and posterior ulnar recurrent arteries, and small branches from the ulnar artery. Acting with the flexor carpi radialis, it flexes the wrist and acting with the extensor carpi ulnaris it adducts the wrist (1). The flexor carpi ulnaris muscle is innervated by the ulnar nerve having root value C₇, C₈, T₁. The line between the medial humeral epicondyle and the pisiform, along the anterior palmar margin of the muscle, is used as a reference point for locating the ulnar neurovascular bundle. The ulnar artery reaches the muscle in its middle third, whereas the ulnar nerve is covered by the muscle throughout its entire course running under the tendon in the wrist region. The ulnar artery, the deeper and the larger of the two terminal branches of the brachial artery, begins a little below the bend of the elbow, and, passing obliquely downward, reaches the ulnar side of the forearm at a point about midway between the elbow and the wrist. It then runs along the ulnar border to the wrist, crosses the transverse carpal ligament on the radial side of the pisiform bone, and immediately beyond this bone divides into two branches, which enter into the formation of the superficial and deep palmar arches.

Like the median nerve, the ulnar nerve has no branches in the arm, but it also supplies articular branches to the elbow joint [3]. It enters the forearm between the two heads of the flexor carpi ulnaris superficial to the posterior and oblique parts of the ulnar collateral ligament [1]. The ulnar nerve, after descending in the forearm between the flexor digitorum profundus and the flexor carpi ulnaris muscles, pierces the deep fascia and enters the wrist through the Guyon’s canal. In the distal canal, the ulnar nerve bifurcates into a superficial sensory branch and a deep motor branch, which supplies the hypothenar muscles and then passes across the palm, distributing to other intrinsic hand muscles [2].

Case Report:

During routine dissection, of the right upper limb of a 70 years old donated embalmed male cadaver in the Department of Anatomy, K.J. Somaiya Medical College, Sion, Mumbai, India, we observed an additional muscle slip of flexor carpi ulnaris associated with anomalous high division of dorsal branch of the ulnar nerve. The additional belly originated from the lower part of the flexor carpi ulnaris muscle and crossed the ulnar nerve, the ulnar vessels and the median nerve. The additional belly merged with the flexor retinaculum. The ulnar nerve divided into the terminal branches in the upper part of the forearm. However, the distribution of the terminal branches of ulnar nerve was normal in the palm. The ulnar artery runs superficial to the superficial flexor muscles of the forearm. The variations were unilateral and the left upper limb was normal. The photographs of the triple variations were taken for proper documentation.

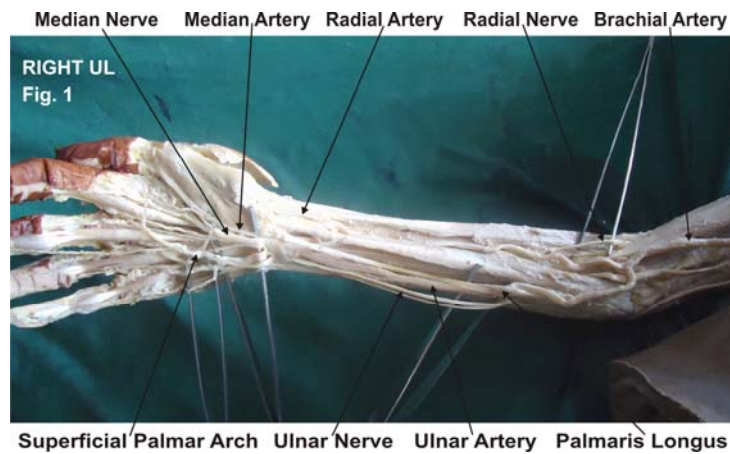


Figure 1 : The photographic presentation of an additional muscle slip from the flexor carpi ulnaris muscle in the lower part of the forearm associated with anomalous high division of dorsal branch of ulnar nerve.

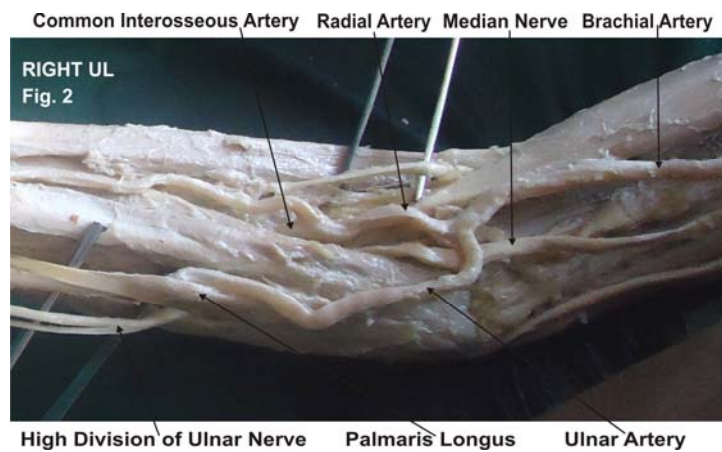


Figure 2 : The photographic presentation of the variant course of ulnar artery and the high division of the ulnar nerve in the forearm.

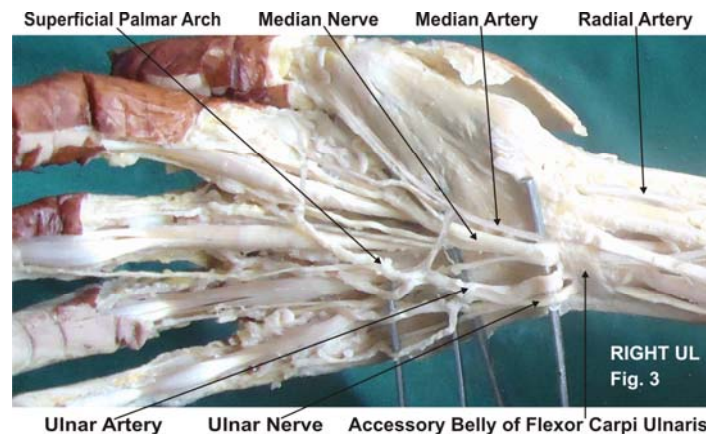


Figure 3 : The photographic presentation of the additional belly which originated from the lower part of the flexor carpi ulnaris muscle and crossed the ulnar nerve, the ulnar vessels and the median nerve and merged with the flexor retinaculum.

DISCUSSION

The flexor carpi ulnaris muscle acts as an anatomical guideline for finding the neurovascular bundle i.e. the ulnar nerve and artery and accompanying venae comitantes, it can be easily palpated in its distal course if the wrist is flexed and adducted. The line between the medial humeral epicondyle and the pisiform, along the anterior palmar margin of the flexor carpi ulnaris muscle, is used as a reference point [3]. Anatomical variations in musculotendinous junction of the flexor carpi ulnaris muscle were found in literature [4]. The variant flexor carpi ulnaris causing ulnar nerve compression was also documented [5]. An additional slip of flexor carpi ulnaris muscle was reported by previous research workers [6]. But the presence of an additional muscle slip of flexor carpi ulnaris muscle associated with anomalous high division of dorsal branch of the ulnar nerve was not yet reported in literature. The variations of the flexor carpi ulnaris muscle is important for the radiologist in interpreting the ultrasound and the magnetic resonance images and also for the surgeons operating on the ulnar neurovascular bundle by using flexor carpi ulnaris muscle as a guideline. The ulnar nerve entrapment may occur due to the aponeurosis of the two heads of the flexor carpi ulnaris muscle leading to compression or irritation of the ulnar nerve. The surgeons should have the knowledge of an additional slip of the flexor carpi ulnaris muscle while operating on the compression or irritation of the ulnar nerve and the cubital tunnel syndrome. A test called electromyography i.e. EMG and / or nerve conduction study i.e. NCS may be done to confirm the diagnosis of the ulnar nerve entrapment and its severity. During the surgical correction on cubital tunnel syndrome the ulnar nerve is moved from its place behind the medial epicondyle to a new place in front of it. This is called an anterior transposition of the ulnar nerve. The nerve can be moved to lie under the skin and fat but on top of the muscle (subcutaneous transposition), within the muscle (intermuscular transposition) or under the muscle (submuscular transposition). Therefore the knowledge of the variations of the flexor carpi ulnaris muscle is important in cubital tunnel release operation. This knowledge is also important for the plastic surgeons using a proximally based, pedicled flexor carpi ulnaris muscle turnover flap for the soft tissue reconstruction at the posterior elbow [7]. The whole and split flexor carpi ulnaris pedicle flaps provide predictable coverage of posterior elbow soft-tissue defects [8]. The flexor carpi ulnaris muscle is a useful local muscle flap in the forearm and elbow. The flexor carpi ulnaris muscle is an important palmar flexor and ulnar deviator of the wrist, and hence the action may be affected if the entire muscle is used as a local muscle flap. The flexor carpi ulnaris muscle is made up of two distinct neuromuscular compartments. This arrangement allows for splitting of the muscle and the potential use of the larger ulnar compartment as a local muscle flap while maintaining the humeral compartment to flex and adduct the hand [9]. The flexor carpi ulnaris muscle pedicle flap is used to improve blood supply and soft tissue coverage at the infected nonunion site of the proximal ulna for restoration of elbow function [10]. Entrapment or compressive neuropathies are important and wide spread debilitating clinical problems.

They are caused frequently as the nerve passes through a fibrous tunnel, or an opening in fibrous or muscular tissue. The most common is the entrapment of the median nerve in the wrist leading to the carpal tunnel syndrome. In the present case, the accessory belly of the flexor carpi ulnaris muscle crossed over the ulnar nerve and the median nerve. The accessory belly of the flexor carpi ulnaris muscle may compress the ulnar nerve and the median nerve which might lead to numbness and tingling in the hand. The knowledge of this variation may be clinically important because the symptoms are similar to those of the carpal tunnel syndrome [11]. The knowledge of course and distribution of ulnar nerve can assist the anaesthetist in pain management therapies. In the era of modern medicine due to the technical advances and interventional methods of diagnosis and treatment it is very important to record and discuss the anatomical anomalies [12]. The ulnar tunnel is located at the proximal part of the hand lateral to the pisiform bone and to the proximal part of the carpal tunnel. The ulnar tunnel contains the ulnar nerve and artery. Compression of the ulnar nerve in this tunnel is often reported due to cysts, occupational trauma, fractures and muscle variations [13, 14].

Clinical significance:

The anatomical variation described here has practical implications, since injury to the ulnar nerve in the upper part of forearm would, in this case, have caused unexpected loss of cutaneous sensation on the dorsum of the hand. The crossing of accessory belly of the flexor carpi ulnaris muscle over the ulnar nerve and the median nerve might compress them leading to numbness and tingling in the hand. The knowledge of this variation may be clinically important because the symptoms are similar to those of the carpal tunnel syndrome. The variation in the flexor carpi ulnaris muscle should be kept in mind by the plastic surgeons who are using the flexor carpi ulnaris muscle pedicle flap to improve blood supply and soft tissue coverage at the non union site of the proximal ulna for restoration of elbow function.

CONCLUSION

The awareness of additional muscle slip of flexor carpi ulnaris associated with variant ulnar artery and ulnar nerve in the forearm is clinically important for surgeons dealing with entrapment or compressive neuropathies, orthopaedicians operating on the fractures of radius or ulna and anaesthetist performing pain management therapies on the upper limb. A lack of knowledge of such type of variations might complicate surgical repair and may cause ineffective nerve blockade.

Competing interests:

The author declare that he has no competing interests.

ACKNOWLEDGEMENT

Author is also thankful to Dean Dr. Geeta Niyogi Madam for her support and encouragement. Author is also thankful to Dr. Arif A. Faruqui and Mr. M. Murugan for their help. Author also acknowledge the immense help received from the scholars whose articles are cited and included in references of this manuscript. The author is also grateful to authors / editors / publishers of all those articles, journals and books from where the literature for this article has been reviewed and discussed.

REFERENCES

- [1]. Williams P.L., Dyson M, Standring S, Ellis H, Healy JC, Johnson D - Gray's Anatomy. 39th ed. London ELBS with Churchill Livingstone, 2005, pp. 877.
- [2]. Hollinshead, WH. Functional anatomy of the limbs and back. 4th ed. Philadelphia: W.B. Saunders, 1976, pp. 184-185.
- [3]. Moore KL, Dalley AF. Clinically oriented anatomy. 5 Ed., Baltimore, Lippincott Williams and Wilkins, 2006, pp. 794, 819-822.
- [4]. Grechenig, W.; Clement, H.; Egner, S.; Tesch, N. P.; Weiglein, A. & Peicha, G. Musculo-tendinous junction of the flexor carpi ulnaris muscle : An anatomical study. Surg. Radiol. Anat, vol. 22, 2000, pp. 255-60.
- [5]. Al-Qattan, M. M. & Duerksen, F. A variant of flexor carpi ulnaris causing ulnar nerve compression. J. Anat., 180, 1992, pp. 189-190.

- [6]. Bergman, R. A.; Thomson, S. A.; Afifi, A. K. & Saadesh, F. A. Compendium of human anatomic variations. Urban & Schwarzenberg, Baltimore – Munich, 1988, pp. 13.
- [7]. Payne DE, Kaufman AM, Wysocki RW, Richard MJ, Ruch DS, Leversedge FJ, Vascular perfusion of a flexor carpi ulnaris muscle turnover pedicle flap for posterior elbow soft tissue reconstruction: a cadaveric study, *J Hand Surg Am.* Feb;36(2), 2011, pp. 246-51.
- [8]. Wysocki RW, Gray RL, Fernandez JJ, Cohen MS, Posterior elbow coverage using whole and split flexor carpi ulnaris flaps: a cadaveric study, *J Hand Surg Am.* 2008 Dec; 33(10), pp. 1807-12.
- [9]. Lingaraj, K.; Lim, A. Y.; Puhaindran, M. E. & Kumar, P. V. The split flexor carpi ulnaris as a local muscle flap. *Clin Orthop. Relat. Res.* Vol. 455, 2007, pp. 262-6,.
- [10]. Meals, R. A. The use of a flexor carpi ulnaris muscle flap in the treatment of an infected nonunion of the proximal ulna. A case report. *Clin. Orthop. Relat. Res.*, vol. 240, 1989, pp. 168- 72.
- [11]. Olave E, Del Sol M, Gabrielli C, Prates JC and Rodrigues CFS, The ulnar tunnel: a rare disposition of its contents. *Journal of Anatomy*, 1997, vol. 191, pp. 615-616.
- [12]. Hicks J. and Newell R, Supernumerary muscles in the pectoral and axillary region, and the nature of the axillary arches. *Clinical Anatomy*, 1997, vol. 10, pp. 211-212.
- [13]. Kleinert H. and Hayes J, The ulnar tunnel syndrome. *Plastic Reconstructive Surgery*, 1971, vol. 47, pp. 21-24.
- [14]. Schjelderup H, Aberrant muscle in the hand causing ulnar nerve compression. *Journal of Bone and Joint Surgery*, 1964, vol. 46B, pp. 361.