



## A CASE REPORT ON BILATERAL THREE SEPARATE HEADS OF SOLEUS MUSCLE AND ITS CLINICAL IMPORTANCE.

Sharadkumar Pralhad Sawant

Department of Anatomy, K. J. Somaiya Medical College, Somaiya Ayurvihar, Eastern Express Highway, Sion, Mumbai-400 022

**ABSTRACT:** During routine dissection, of a 70 years old donated embalmed male cadaver in the Department of Anatomy, K.J. Somaiya Medical College, Sion, Mumbai, India, the variant soleus muscle on both the lower limbs was observed. The back of thigh, popliteal region and back of leg of both the lower limbs were dissected meticulously to observe the variations in the soleus muscle. The soleus muscle showed the three separate heads. The tibial head from soleal line present on the posterior surface of the tibia, the fibular head from the back of the head of the fibula and the intermediate head from the tendinous arch placed between the tibial and the fibular origins of the muscle. The three heads of soleus muscle along with the medial and the lateral heads of gastrocnemius formed the tendo calcaneus which got inserted into the middle part of the posterior surface of the calcaneus bone. The pattern of vessels in the lower limb were normal. The variation was bilateral. The photographs of both the variant soleus muscles were taken for proper documentation.

**Conclusion:** The existence of such variation of the soleus muscle should be kept in mind by the surgeons, the orthopaedicians, the radiologists and also by the physiotherapists. The three heads of soleus may prove significant and lead to confusion during surgical procedures. A lack of awareness such variations might complicate surgical repair.

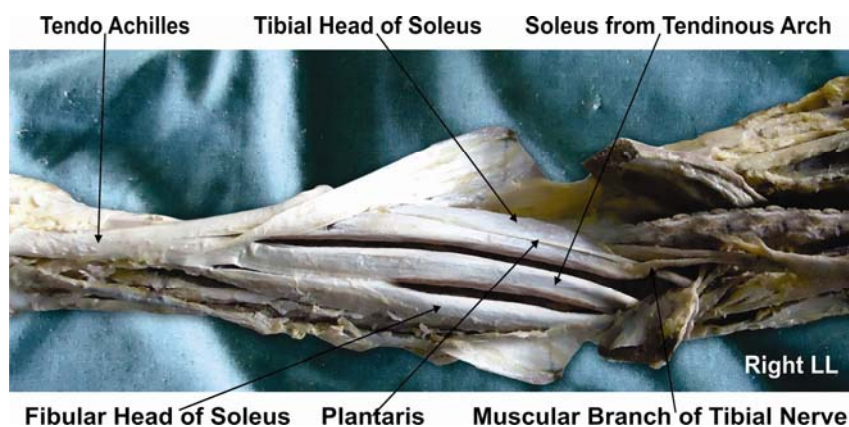
**Keywords:** Soleus Muscle, Three Heads, Surgeons, Orthopaedicians, Radiologists, Physiotherapists.

### INTRODUCTION

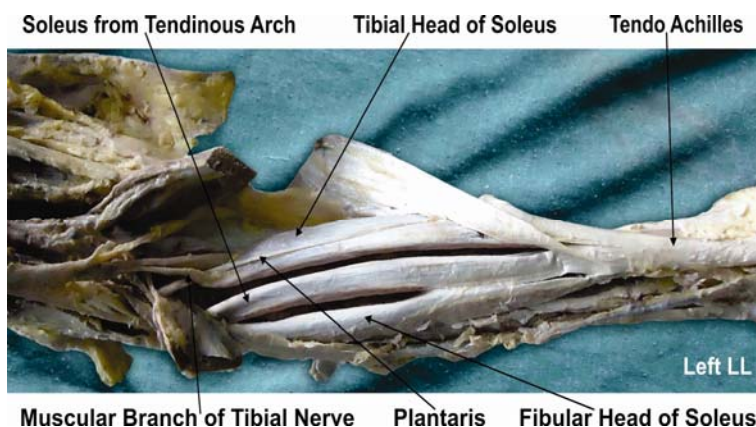
The soleus is a broad flat muscle situated immediately in front of the gastrocnemius. It arises by tendinous fibers from the back of the head of the fibula, and from the upper third of the posterior surface of the body of the bone; from the popliteal line, and the middle third of the medial border of the tibia; some fibers also arise from a tendinous arch placed between the tibial and fibular origins of the muscle, in front of which the popliteal vessels and tibial nerve run. The fibers end in an aponeurosis which covers the posterior surface of the muscle, and, gradually becoming thicker and narrower, joins with the tendon of the gastrocnemius, and forms with it the tendo calcaneus [1]. Accessory head to its lower and inner part usually ending in the tendocalcaneus, or the calcaneus, or the lacinate ligament [2]. The gastrocnemius and soleus together form a muscular mass which is occasionally described as the Triceps surae; its tendon of insertion is the tendo calcaneus (Tendo Achillis), the common tendon of the gastrocnemius and soleus, is the thickest and strongest in the body. It is about 15 cm. long, and begins near the middle of the leg, but receives fleshy fibers on its anterior surface, almost to its lower end. Gradually becoming contracted below, it is inserted into the middle part of the posterior surface of the calcaneus, a bursa being interposed between the tendon and the upper part of this surface. The tendon spreads out somewhat at its lower end, so that its narrowest part is about 4 cm. above its insertion. It is covered by the fascia and the integument, and is separated from the deep muscles and vessels by a considerable interval filled up with areolar and adipose tissue. Along its lateral side, but superficial to it, is the small saphenous vein [4].

### Case Report:

During routine dissection, of a 70 years old donated embalmed male cadaver in the Department of Anatomy, K.J. Somaiya Medical College, Sion, Mumbai, India, the variant soleus muscle on both the lower limbs was observed. The back of thigh, popliteal region and back of leg of both the lower limbs were dissected meticulously to observe the variations in the soleus muscle. The soleus muscle showed the three separate heads. The tibial head from soleal line present on the posterior surface of the tibia, the fibular head from the back of the head of the fibula and the intermediate head from the tendinous arch placed between the tibial and the fibular origins of the muscle. The three heads of soleus muscle along with the medial and the lateral heads of gastrocnemius formed the tendo calcaneus which got inserted into the middle part of the posterior surface of the calcaneus bone. The pattern of vessels in the lower limb were normal. The variation was bilateral. The photographs of both the variant soleus muscles were taken for proper documentation.



**Figure 1: Photographic presentation of the variant heads of right soleus muscle.**



**Figure 2: Photographic presentation of the variant heads of left soleus muscle.**

### DISCUSSION

The accessory soleus muscle was first described in literature by Fuc Cruvelhier in 1834. The variant soleus muscle is present in 0.7 to 5.5% of the population [5]. It is a rare anatomical variation that can present as a soft tissue tumor in this region. A congenital muscle anomaly is more frequent in the upper limbs and is rarely seen in the lower limbs. During embryogenesis the soleus muscle separates into two parts, and this supernumerary muscle has its own blood supply and innervations [6, 7]. This supernumerary muscle is located under the gastrocnemius muscle, in the posterior upper third of the fibula, in the oblique soleus line, between the fibular head and the posterior part of the tibia. From its origin, the accessory soleus muscle runs anteriorly and medially until it reaches the Achilles tendon.

Five accessory soleus muscle types were described based on their insertion characteristics, including the Achilles tendon, the muscle insertion in the upper calcaneus region, the tendon insertion in the upper calcaneus, the muscle insertion in the medial calcaneus region, and finally the tendon insertion in the medial part of the calcaneus [5]. The accessory soleus muscle is usually observed during the second or third decade of life and more often in males at 2:1 ratio [8, 9, 10]. This is a rare condition and its general prevalence has not been established yet [11]. Statistical analysis shows that accessory soleus muscle is more frequently a unilateral finding [12]. But in the present case the variation in the soleus muscle was bilateral. The reports in the literature stated a 0.7 to 5.5% presence of accessory soleus muscle in human beings [13, 14, 15, 16]. Some investigators reported a prevalence ranging from 1 to 6% in human beings [17]. Sometimes it is very difficult to identify the origin and insertion of the accessory soleus muscle on the MRI study [18, 19, 20]. The variations in the soleus muscle were common in males [21]. In the present case the variation was observed in male specimen. Thus our finding coincides with the literature.

### **Clinical significance:**

The knowledge of any variation in the soleus muscle is clinically important because the soleus muscle is called as peripheral heart. The presence of variant soleus muscle may appear as a soft tissue tumor on MRI study in this region.

### **CONCLUSION**

The existence of such variation of the soleus muscle should be kept in mind by the surgeons, the orthopaedicians, the radiologists and also by the physiotherapists. The three heads of soleus may prove significant and lead to confusion during surgical procedures. A lack of awareness such variations might complicate surgical repair.

### **Competing interests:**

The author declare that he has no competing interests.

### **ACKNOWLEDGEMENT**

Author is also thankful to Dean Dr. Geeta Niyogi Madam for her support and encouragement. Author is also thankful to Dr. Arif A. Faruqui and Mr. M. Murugan for their help. Author also acknowledge the immense help received from the scholars whose articles are cited and included in references of this manuscript. The author is also grateful to authors / editors / publishers of all those articles, journals and books from where the literature for this article has been reviewed and discussed.

### **REFERENCES**

- [1]. Williams PL, Bannister LH, Berry MM, Collins P, Dyson M, Dussek JE, et al. The Nervous system. In: Gray's Anatomy, 39th edn, Churchill Livingstone, New York; 2005; 879 - 880.
- [2]. Hamilton WJ. Textbook of the Human Anatomy, 2nd edn, Macmillan Press Ltd., London 1976; 651.
- [3]. Last RJ. Anatomy: Regional and Applied, 7th edn, Churchill Livingstone, Edinburgh 1984; 89.
- [4]. Snell RS. Clinical Anatomy for Medical Students, 5th edn, Little Brown and Company, USA; 1995; 434.
- [5]. Sookur PA, Naraghi AM, Bleakney RR, Jalan R, Chan O, White LM. Accessory muscles: anatomy, symptoms and radiology evaluation. Radiographics. 2008; 28 (2) : 481 - 99.
- [6]. Moore KL, Dalley AF. Clinically Oriented Anatomy. 4th ed. Philadelphia: Lippincott Williams & Wilkins, 1999: 347-560.
- [7]. Boyd, J.D.; Clark, W.E.; Hamilton, W.J.; Yoffey, J.M.; Zuckerman, S; Appleton, A.B.: Textbook of Human Anatomy In: Cardiovascular system. Blood Vessels. Mcmillan & Co. Ltd. New York. : 341-346 (1956).
- [8]. Romanus B, Lindahl S, Sterner B. Accessory soleus muscle. A clinical and radiographic presentation of eleven cases. J Bone Joint Surg Am. 1986; 68 (5) :731-4.
- [9]. Leswick DA, Chow V, Stoneham GW. Resident's corner. Can Assoc Radiol J. 2003; 54 (5) : 313 - 5.

- [10]. Kouvalchouk J.F, Lecocq J, Parier J, Fischer M. The accessory soleus muscle: a report of 21 cases and a review of the literature. *Rev Chir Orthop Reparatrice Appar Mot.* 2006; 91 (3) : 232 - 8. French.
- [11]. Kurtoglu Z, Uluutku H. Bilateral accessory soleus muscle. *Turk J Med Sci.* 2000; 30 : 393 - 5.
- [12]. Christodoulou A, Terzidis I, Natsis K, Gigis I, Pournaras J. Soleus accessorius, an anomalous muscle in a young athlete: case report and analysis of the literature. *Br J Sport Med.* 2004; 38 (6) : e 38.
- [13]. Toit MN, de Villiers RV, Derman EW. Persistent pain following ankle sprain: bilateral accessory soleus muscle. *S Afr Med J.* 2009; 99 (11) : 791 - 2.
- [14]. Mir NA, Kangoo KA. Accessory soleus muscle: a case report and review of the literature. *JK Sci.* 2002; 4 (1): 41 - 2.
- [15]. Reis FP, Aragão JA, Fernandes AC, Feitosa VL, Fakhouri R, Nunes MA. The accessory soleus muscle: case report and a review of the literature. *Int J Morphol.* 2007; 25 (4) : 881 - 4.
- [16]. Singh S, Suri RK Mehta V, Loh H, Arora J, Rath G. Bilateral additional bellies of the soleus muscle: anatomical and clinical insight. *Int J Anat Var.* 2009; 2 : 20 - 2.
- [17]. Luck MD, Gordon AG, Beblea JS, Dalinka MK. High association between accessory soleus muscle and Achilles tendonopathy. *Skeletal Radiol.* 2008; 37 (12) : 1129 - 33.
- [18]. Featherstone T. MRI diagnosis of accessory soleus muscle strain. *Br J Sports Med.* 1995; 29 (4) : 277 - 8.
- [19]. Doda N, Peh WC, Chawla A. Symptomatic accessory soleus muscle: diagnosis and follow-up on magnetic resonance imaging. *Br J Radiol.* 2006; 79 (946) :e129 - 32.
- [20]. Carroll JF. Accessory muscles of the ankle. MRI Web Clinic [Internet]. 2008 Nov [cited 2012 Jan 31]. Available from: <http://www.radsourc.us/clinic/0811>.
- [21]. Meherzi MH, Bouaziz M, Hamida FB, Ghannouchi M, Quertatani M, Nouri H, et al. The accessory soleus muscle: a report of the two cases with review of the literature. *Méd Chir Pied.* 2009; 25 (1) : 17 - 20.