



A CASE REPORT ON INCOMPLETE ULNAR TYPE OF SUPERFICIAL PALMAR ARCH WITH ITS DEVELOPMENTAL BASIS.

Sharadkumar Pralhad Sawant

Department of Anatomy, K. J. Somaiya Medical College, Somaiya Ayurvihar, Eastern Express Highway, Sion, Mumbai-400 022

ABSTRACT: During routine dissection for the undergraduate first MBBS students on the right upper limb of a 70 years old donated embalmed male cadaver in the Department of Anatomy, K.J. Somaiya Medical College, Sion, Mumbai, India, we observed an incomplete superficial palmar arch. The superficial palmar arch was formed alone by the ulnar artery on medial side and there was no contribution from the radial artery on the lateral side. The photographs of the incomplete superficial palmar arch were taken for proper documentation and ready reference. There was no associated neuromuscular variations seen in the same specimen. The formation of the deep palmar arch was normal. The arterial pattern of the left upper limb of the same cadaver was normal.

Conclusion: The knowledge of variations of vascular pattern of hand gained more importance in microsurgical techniques, reconstructive hand surgeries, preoperative screening of radial artery harvesting for myocardial revascularization and also in arterial interventions that include radial artery cannulation and radial artery forearm flap.

Key words: superficial palmar arch, ulnar artery, radial artery, collateral circulation, hand surgery, plastic surgeon, vascular graft applications arterial repairs, free and pedicled flaps.

INTRODUCTION

The general pattern of arterial supply of the hand consists of two systems for the volar aspect and a single system for the dorsal aspect. The volar supply is arranged into a superficial and a deep group i.e., superficial palmar arch and deep palmar arch. The superficial palmar arch is mainly fed by the ulnar artery, passing superficial to the flexor retinaculum, then curving laterally to form an arch, lying just deep to the palmar aponeurosis. About one third of the superficial palmar arch is formed by the ulnar artery alone; a further third is completed by the superficial palmar branch of the radial artery; and a third by the radialis indicis artery, often a branch of the princeps pollicis artery, or by the median artery [1]. The superficial palmar arch is an arterial arcade and a dominant vascular structure of the palm. It is localized just deep to palmar aponeurosis and is superficial to digital branches of the median nerve, long flexor tendons of the forearm and lumbricals of the palm [2]. The arch is formed by superficial terminal branch of the ulnar artery and can be completed on lateral side by superficial palmar branch of the radial artery or the princeps pollicis artery or the radialis indicis artery or the median artery which accompanies the median nerve [3]. From the convexity of superficial palmar arch three common palmar digital arteries will arise and each one divides into two proper palmar digital arteries. These run along the contiguous sides of all four medial fingers to supply them. The palmar digital artery for the medial side of the little finger leaves the arch under palmaris brevis. The radial side of the index finger is supplied by the radialis indicis artery and the thumb is supplied by the princeps pollicis artery both of these are branches of the radial artery (1). The anastomoses between the radial and the ulnar arteries through superficial and deep palmar arches in the palm play a significant role through collateral circulation in the diseases of the palm. Knowledge of the frequency of anatomical variations of the arterial pattern of the hand is crucial for safe and successful hand surgeries [4].

Case Report:

During routine dissection for the undergraduate first MBBS students on the right upper limb of a 70 years old donated embalmed male cadaver in the Department of Anatomy, K.J. Somaiya Medical College, Sion, Mumbai, India, we observed an incomplete superficial palmar arch. In the present case superficial palmar arch was formed alone by the ulnar artery, without the contribution of radial artery or any of its branches. Ulnar artery entered the palm by coursing in front of the flexor retinaculum, just distal to the retinaculum it gave a deep branch and continued as the superficial palmar arch. But it was an incomplete arch, occupying almost normal position. It supplied palmar aspect of all the fingers including thumb and index finger. It gave a digital branch to the ulnar side of the little finger, three common palmar digital branches to supply adjacent sides of medial four fingers. The palmar digital artery for the medial side of the little finger leaves the arch under palmaris brevis. The radial side of the index finger is supplied by the radialis indicis artery and the thumb is supplied by the princeps pollicis artery both of these are branches of the radial artery. The superficial branch of radial artery was small and terminated by nourishing the thenar muscles. However the deep palmar arch was complete and normal. The deep palmar arch was formed by the direct continuation of the radial artery on lateral side and completed by the deep branch of the ulnar artery on medial side. The deep palmar arch is the only communication between the radial artery and the ulnar artery which formed the major channel for collateral circulation. The photographs of the incomplete superficial palmar arch were taken for proper documentation and ready reference.

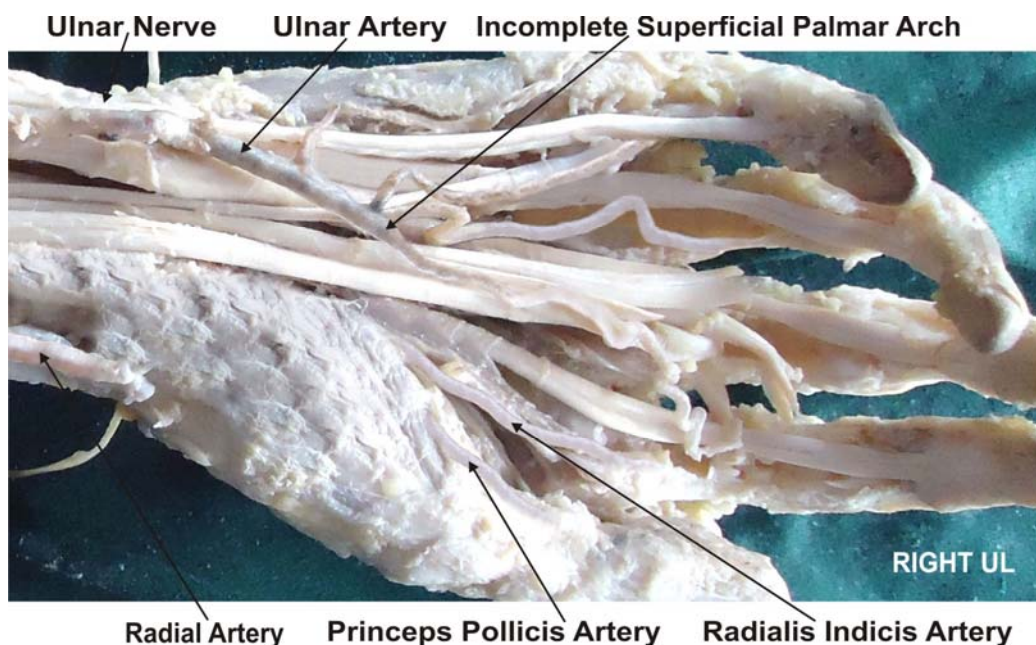


Figure : Photographic presentation of an incomplete superficial palmar arch formed alone by the ulnar artery without the contribution of radial artery or any of its branches.

DISCUSSION

The superficial palmar arch is the anastomosis formed by the ulnar artery, entering the palm with the ulnar nerve, anterior to the flexor retinaculum and lateral to the pisiform, passing medial to the hook of hamate, then curving laterally to form an arch, convex distally across the middle 1/3rd of the palm, and in level with a transverse line through the distal border of the fully extended pollicial base [1, 5, 6]. The superficial palmar arch is covered by the palmaris brevis and palmar aponeurosis and it is superficial to the flexor digiti minimi, branches of the median nerve and to the long flexor tendons and lumbrical muscles [7]. The traditional definition of superficial palmar arch consists of linkage between the superficial palmar branch of the radial artery and ulnar artery [8]. Although the radial and ulnar arteries provide most of the blood supply to the hand, additional circulation may come from the median artery or the interosseus arterial system (9). The superficial palmar arch is a direct continuation of the ulnar artery [10].

It gives four palmar digital arteries, the medial most supplies the medial side of little finger and is termed as the proper palmar digital artery. The other three are common palmar digital arteries which pass to the medial three interdigital clefts [11]. There is a report of superficial palmar branch of the radial artery terminating in the thenar muscles without any contribution to the superficial palmar arch [12]. It is extremely difficult to establish a type, due to the large number of variations in the superficial palmar arch [13]. Gellman et al. classified the superficial palmar arch into two categories as complete and incomplete. In complete arch there will be an anastomosis between vessels constituting it. There will be an absence of a communication or anastomosis between the vessels constituting an incomplete arch. In the present case the ulnar artery does not anastomose with the radial artery or the median artery and hence the superficial palmar arch was incomplete type. This classification is simple and understandable for many anatomists and researchers and is currently in use [14]. Adachi has described 3 types of superficial palmar arch [15]. Type A : Ulnar type - in which contribution by radial artery is absent or minimal, Type B : Radioulnar type - in which arch is formed by the superficial palmar branch of radial artery and the larger ulnar artery, Type C : Mediano ulnar type - in which arch is formed by the median artery and the larger ulnar artery. The superficial palmar arch observed in the present case is Adachi's Type A : Ulnar type. Huber [16] classified the superficial palmar arch into 2 types. Type 1 in which additional branches from the forearm participate in the formation of the arch or replace the radial in its composition. Type 2 in which there is no true arch, the arteries which should participate in its formation and in some cases the additional ones also, failing to anastomose and each giving rise independently to a certain number of digital branches in a somewhat fan like manner. The superficial palmar arch seen in the present case is Huber's Type 1. Coleman and Anson [17] elaborated more on superficial palmar arch and reclassified it as follows : Group I : Complete arch. It can be further divided into five types :- Type A : The classical radio ulnar arch is formed by superficial palmar branch of radial artery and the larger ulnar artery. Type B : This arch is formed entirely by ulnar artery. Type C : Mediano ulnar arch is composed of ulnar artery and an enlarged median artery. Type D: Radio-mediano-ulnar arch in which 3 vessels enter into the formation of arch. Type E : It consists of a well formed arch initiated by ulnar artery and completed by a large sized vessel derived from deep arch. The latter vessel comes to superficial level at the base of the thenar eminence of join the ulnar artery. Group II : Incomplete arch : When the contributing arteries to the superficial arch do not anastomose or when the ulnar artery fails to reach the thumb and index finger, the arch is incomplete. It can be further divided into 4 types. Type A : Both superficial palmar branch of radial artery and ulnar artery take part in supplying palm and fingers but in doing so, fail to anastomose. Type B : Only the ulnar artery forms superficial palmar arch. The arch is incomplete in the sense that the ulnar artery does not take part in the supply of thumb and index finger. Type C : Superficial vessels receive contributions from both median and ulnar arteries but without anastomosis. Type D : Radial, median and ulnar artery all give origin to superficial vessels but do not anastomose. The superficial palmar arch seen in the present case is Coleman and Anson's Type B. Since the superficial palmar arch is the main source of arterial supply to the palm, the details about its possible variations is important for the hand surgeons. The knowledge is important while performing the superficial dissections and to the radiologists while performing the angiographic procedures. The morphology of arterial arches of hand is important for microvascular surgeons as well as orthopaedicians [18]. The clamping of radial artery is contraindicated in cases of deficient collateral flow through the ulnar artery, as it can lead to ischemia and gangrene of the fingers [19]. The patients should be screened before harvesting the radial artery to confirm the presence of a viable collateral circulation in the hand [8]. It is mandatory to conduct the investigations like Allen test, angiography and colour doppler studies of the hand before starting any invasive procedures including the vascular surgeries. The knowledge about these variant arches is essential for the safe and successful outcome of the hand surgeries. The recent advances in microsurgical techniques for the reconstruction of hand and upper extremity after trauma and congenital deformities have necessitated better understanding of the vascular patterns of the vessels. The doppler and angiographic studies allow visualization of vessels of the hand, but do not accurately assess the small connecting vessels [20, 21, 22, 23]. The hand surgeon needs to refer to the existence and healthy functioning of the arch before surgical procedures such as, arterial repairs, vascular graft applications. The radial artery contributes greatly to the circulation of the hand but in many cases it can be removed as a non-essential vessel, with adequate circulation being provided by the remaining ulnar and in some cases, persistent median artery [24].

Developmental Basis:

The ontogenic explanation of variations of superficial palmar arch was documented [25, 26]. The comparative study of arteries of hands in primates confirmed that the variations noted in man represent a retention or reappearance of primitive patterns [27]. In the embryological parallelism, ontogeny recapitulates phylogeny. By the stage 21 of the embryo, the radial artery acquires its final differentiated state [28]. The arterial variations affecting the distal course of the radial artery must have established before the 21st week of gestational stage [19, 29].

Clinical significance:

Knowledge of variations of vascular patterns of hand gained more importance in microsurgical techniques, reconstructive hand surgeries, preoperative screening of radial artery harvesting for myocardial revascularization and also in arterial interventions that include radial artery cannulation and radial artery forearm flap. A lack of knowledge of such type of variations might complicate reconstruction hand surgeries [30].

CONCLUSION

Recent advances in the microsurgical techniques for reconstructive hand surgeries have necessitated the understanding of variant arterial arches, the comprehensive knowledge of which is important for the surgical interventions and successful outcome. Scientific improvement can be achieved by thorough knowledge of anatomical variations. The detailed knowledge about the complex anatomical structures in the hand and upper extremity is essential for verifying the validity of various surgical procedures under practice and to define new.

Competing interests:

The author declare that he has no competing interests.

ACKNOWLEDGEMENT

Author is also thankful to Dean Dr. Geeta Niyogi Madam for her support and encouragement. Author is also thankful to Dr. Arif A. Faruqi and Mr. M. Murugan for their help. Author also acknowledge the immense help received from the scholars whose articles are cited and included in references of this manuscript. The author is also grateful to authors / editors / publishers of all those articles, journals and books from where the literature for this article has been reviewed and discussed.

REFERENCES

- [1]. Johnson D, Ellis H, Collins P. Wrist and hand. In: Standring S, Ellis H, Healy JC, Johnson D, Williams A, eds. Gray's Anatomy. 39th Ed., Edinburgh, Churchill Livingstone. 2005; 929–930.
- [2]. Gajisin S, Zbrodowski A. Local vascular contribution of the superficial palmar arch. Acta. Anat (Basel). 1993; 147: 248–251.
- [3]. Datta AK. Essentials of human anatomy. Superior and inferior extremities. 2nd Ed., Calcutta, Current Books International. 2000; 99–100.
- [4]. Jellic N, Gajisin S, Zbrodowski A. Arcus palmaris superficialis. Acta Anat (Basel). 1988; 132: 187–190.
- [5]. Massie, G.: Surgical Anatomy In: The Upper Limb 4th Edn. J. & A Churchill Ltd. London. : pp 177-8. (1944)
- [6]. Boyd, J.D.; Clark, W.E.; Hamilton, W.J.; Yoffey, J.M.; Zuckerman, S; Appleton, A.B.: Textbook of Human Anatomy In: Cardiovascular system. Blood Vessels. Mcmillan & Co. Ltd. New York. : 341-346 (1956).
- [7]. Anson, B.J. & Maddock, W.G.: Callender's Surgical Anatomy In: The hand-palmar region. 3rd Edn. W.B. Saunders Co. Philedelphia,; p 831 (1952).
- [8]. Ruengsakulrach R, Eizenberg N, Fahrner, C, Fahrner M. and Buxton BF, Surgical implications of variations in hand collateral circulation: Anatomy revisited. The Journal of Thoracic and Cardiovascular Surgery, 2001, vol. 122, n. 4, p. 682-686. PMID:11581598. <http://dx.doi.org/10.1067/mtc.2001.116951>

- [9]. Ruengsakulrach P, Eizenberg N, Fahrer C, Fahrer M, Buxton BF. Surgical implications of variations in hand collateral circulation: Anatomy revisited. *J Thorac Cardiovasc Surg* 2001; 122: 682-686.
- [10]. Snell RS, *Clinical Anatomy*. 7th ed. Baltimore: Lippincott Williams and Wilkins, 2004. p. 545.
- [11]. Romanes G.J: *Cunningham's Manual of Practical Anatomy In: The Upper limb- The forearm & Hand*. Vol. I, 15th Edn. Oxford University Press, Oxford : 2012 p 74-104.
- [12]. Bataineh ZM, Moqattash ST. A complex variation in the superficial palmar arch. *Folia Morphol (Warsz)*.2006; 65: 406-409.
- [13]. Poirier, P: *Traite d' Anatomie Humaine* L. Battalle & Co. Paris : 1886. pp 833.
- [14]. Gellman H, Botte MJ, Shankwiler J, Gelberman RH. Arterial patterns of the deep and superficial palmar arches. *Clin Orthop Relat Res*. 2001; 383: 41-46.
- [15]. Adachi, B: *Das arterien system des japaner*, Kyoto Vol. `1928. pp. 365, 368, 389.
- [16]. Huber, G.C.: *Piersol's Human Anatomy*. In: *The Vascular System*. 9th Edn. Vol. I, J.B. Lippincot Co. Philadelphia.: 1930. pp. 785-91
- [17]. Coleman SS, Anson BJ. Arterial patterns in the hand based upon the study of 650 specimens. *Surg Gynecol Obstet*. 1961; 113: 409-424.
- [18]. Patnaik VVG, Kalsey G. and Singla RK, Palmar arterial arches- a morphological study. *Journal of Anatomical Society of India*, 2002, vol. 51, n. 2, p. 187-193.
- [19]. Ottone NE, Prum N, Dominguez M, Blasi E, Medan C, Shinzato S, Finkelstein D. and Bertone VH. Analysis and clinical importance of superficial arterial palmar irrigation and its variants over 86 cases. *International Journal of Morphology*, 2010, vol. 28, n. 1, p. 157-164.
- [20]. Ikeda A, Ugawa A, Kazihara Y, Hamada N. Arterial patterns in the hand based on a three-dimensional analysis of 220 cadaver hands. *J Hand Surg* 1988;13: 501-509.
- [21]. Al-Turk M, Metcalf WK. A study of the superficial palmar arteries using the Doppler Ultrasonic Flowmeter.S.D.Ü. *Týp Fak. Derg*. 2007;14(2)/ 11-16
- [22]. Tađyl, Superficial palmar arc *J Anat* 1984; 138: 27-32.
- [23]. Starnes SL, Wolk SW, Lampman RM, Shanley C., Prager RL, Kong BK, Fowler JJ, Page JM, Babcock SL, Lange LA, Erlandson EE, Whitehouse WM. Noninvasive evaluation of hand circulation before radial artery harvest for coronary artery bypass grafting. *J Thorac Cardiovasc Surg* 1999; 117: 261-266.
- [24]. Starnes SL, Wolk SW, Lampman RM, Shanley C., Parger RL, Kong BK, Fowler JJ, Page JM, Babcock. Noninvasive evaluation of hand circulation before radial artery harvest for coronary artery bypass grafting. *Journal of Thoracic & Cardiovascular Surgery* 1999; 117: 261-266.
- [25]. Meyer, H. Con (1881): *Der Grand typus des Rete, der Handnurzels und des Fusswurzels*. *Archives of Anatomy & Physiology* 45: 23-64.
- [26]. Singer, E.: Embryological patterns persisting in the arteries of the arm. *Anatomical Record*; 1933. 55: pp 406-413.
- [27]. Manners Smith, T. (1910): *The Limb arteries of the primates*. *Journal of Anatomy & Physiology*. 45: 23-64.
- [28]. Rodriguez-Niedenfuhr M, Burton GJ, Deu J. and Sanudo JR, Development of the arterial pattern in the upper limb of staged human embryos: normal development and anatomic variations. *Journal of Anatomy*, 2001, vol. 199, n. 4, p. 407-417.
- [29]. Arey, L.B. : *Developmental anatomy In: Development of the arteries*. 6th Edn W.B. Saunder's Co. Philadelphia. : 1957. 375-7
- [30]. Treves, F.B. & Rogers, L.: *Surgical Applied Anatomy*. In: *The Upper Extremity*. 11th Edn. Cassell & Co. London. 1947: pp 265- 66