



RESEARCH ARTICLE

The anatomical study of variant superficial palmar arch

Sharadkumar Pralhad Sawant

Department of Anatomy, K.J. Somaiya Medical College, Somaiya Ayurvihar

Eastern Express Highway, Sion, Mumbai-400 022, India

Corresponding author: E-mail: drspsawant@gmail.com; Phone: +91-9322061220

Abstract

The superficial palmar arch in 100 cadavers, was performed on 100 (200 specimens of hand) embalmed donated cadavers (90 males and 10 females) in the Department of Anatomy of K.J. Somaiya Medical College, Sion, Mumbai, India. The dissection of the palm was done meticulously to observe the arterial pattern on the palm. The nerves and muscles of the palm were also seen. The photographs of the variations were taken for proper documentation. Out of 200 specimens the variations were observed in 36 specimens. Out of 36 specimens in 10 specimens the incomplete superficial palmar arch was formed alone by the ulnar artery, in 15 specimens the superficial palmar arch was incomplete formed alone by the ulnar artery and it gave princeps pollicis and radialis indicis arteries, in remaining 15 specimens the superficial palmar arch was of mediano ulnar type i.e. the superficial palmar arch was formed by the ulnar artery on medial side and completed by the median artery on the lateral side. The formation of the deep palmar arch was normal. There were no associated neuro muscular variations seen. All the variations were unilateral. The knowledge of variations of vascular pattern of hand gained more importance in microsurgical techniques, reconstructive hand surgeries, preoperative screening of radial artery harvesting for myocardial revascularization and also in arterial interventions that include radial artery cannulation and radial artery forearm flap.

Keywords: superficial palmar arch, ulnar artery, radial artery, collateral circulation, hand surgery

Received: 28th January; Revised: 26th February; Accepted: 14th March; © IJCS New Liberty Group 2013

Introduction

The general pattern of arterial supply of the hand consists of two systems for the volar aspect and a single system for the dorsal aspect. The volar supply is arranged into a superficial and a deep group i.e., superficial palmar arch and deep palmar arch. The superficial palmar arch is mainly fed by the ulnar artery, passing superficial to the flexor retinaculum, then curving laterally to form an arch, lying just deep to the palmar aponeurosis. About one third of the superficial palmar arch is formed by the ulnar artery alone; a further third is completed by the superficial palmar branch of the radial artery; and a third by the radialis

indicus artery, often a branch of the princeps pollicis artery, or by the median artery (Johnson et al., 2005). The superficial palmar arch is an arterial arcade and a dominant vascular structure of the palm. It is localized just deep to palmar aponeurosis and is superficial to digital branches of the median nerve, long flexor tendons of the forearm and lumbricals of the palm (Gajisin et al., 1993). The arch is formed by superficial terminal branch of the ulnar artery and can be completed on lateral side by superficial palmar branch of the radial artery or the princeps pollicis artery or the radialis indicis artery or the median artery which accompanies the median nerve (Datta, 2000). From the

convexity of superficial palmar arch three common palmar digital arteries will arise and each one divides into two proper palmar digital arteries. These run along the contiguous sides of all four medial fingers to supply them. The palmar digital artery for the medial side of the little finger leaves the arch under palmaris brevis. The radial side of the index finger is supplied by the radialis indicis artery and the thumb is supplied by the princeps pollicis artery both of these are branches of the radial artery (Johnson et al., 2005). The anastomoses between the radial and the ulnar arteries through superficial and deep palmar arches in the palm play a significant role through collateral circulation in the diseases of the palm. Knowledge of the frequency of anatomical variations of the arterial pattern of the hand is crucial for safe and successful hand surgeries (Jelicic et al., 1988).

Materials and Methods

This study on superficial palmar arch was performed on 100 (200 specimens of hand) embalmed donated cadavers (90 males and 10 females) in the department of Anatomy of K.J. Somaiya Medical College, Sion, Mumbai, India. The dissection of the palm was done meticulously to observe the arterial pattern on the palm. The nerves and muscles of the palm were also seen. The photographs of the variations were taken for proper documentation.

Observations

Out of 200 specimens the variations were observed in 36 specimens. Out of 36 specimens in 10 specimens the incomplete superficial palmar arch was formed alone by the ulnar artery (Fig. 1), in 15 specimens the superficial palmar arch was incomplete formed alone by the ulnar artery and it gave princeps pollicis and radialis indicis arteries (Fig. 2), in remaining 15 specimens the superficial

palmar arch was of mediano ulnar type i. e. the superficial palmar arch was formed by the ulnar artery on medial side and completed by the median artery on the lateral side. The (Fig. 3) formation of the deep palmar arch was normal. There were no associated neuro muscular variations seen. All the variations were unilateral.

Fig. 1. An incomplete superficial palmar arch formed alone by the ulnar artery without the contribution of radial artery or any of its branches

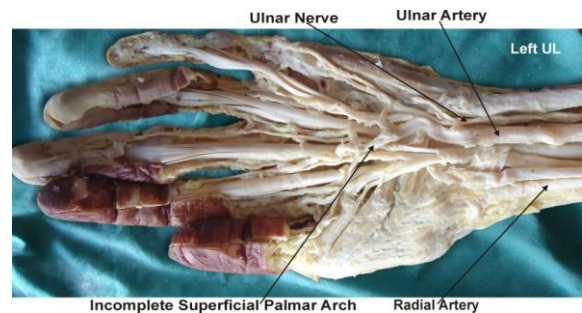


Fig. 2. An incomplete superficial palmar arch formed alone by the ulnar artery and it gave princeps pollicis and radialis indicis arteries

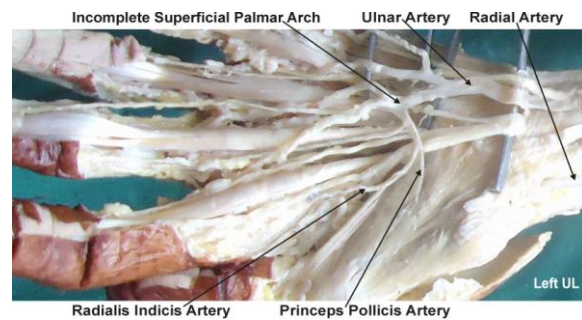
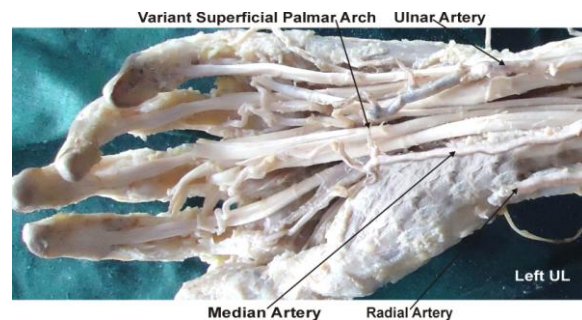


Fig. 3. The variant superficial palmar arch formed by the ulnar artery and the median artery without the contribution of radial artery or any of its branches



Discussion

The superficial palmar arch is the anastomosis formed by the ulnar artery, entering the palm with the ulnar nerve, anterior to the flexor retinaculum and lateral to the pisiform, passing medial to the hamate's hook, then curving laterally to form an arch, convex distally across the middle 1/3rd of the palm, and in level with a transverse line through the distal border of the fully extended pollicial base (Boyd et al., 1956; Johnson et al., 2005). The superficial palmar arch is covered by the palmaris brevis and palmar aponeurosis and it is superficial to the flexor digiti minimi, branches of the median nerve and to the long flexor tendons and lumbrical muscles (Anson et al., 1952). The traditional definition of superficial palmar arch consists of linkage between the superficial palmar branch of the radial artery and ulnar artery (Ruengsakulrach et al., 2001).

Although the radial and ulnar arteries provide most of the blood supply to the hand, additional circulation may come from the median artery or the interosseus arterial system (Ruengsakulrach et al., 2001). The superficial palmar arch is a direct continuation of the ulnar artery (Snell, 2004). It gives four palmar digital arteries, the medial most supplies the medial side of little finger and is termed as the proper palmar digital artery. The other three are common palmar digital arteries which pass to the medial three interdigital clefts (Romanes, 2012). There is a report of superficial palmar branch of the radial artery terminating in the thenar muscles without any contribution to the superficial palmar arch (Bataineh et al., 2006). It is extremely difficult to establish a type, due to the large number of variations in the superficial palmar arch (Poirier, 1886). Gellman et al. classified the superficial palmar arch into two categories as complete and incomplete. In complete arch there will be an anastomosis between vessels

constituting it. There will be an absence of a communication or anastomosis between the vessels constituting an incomplete arch. In the present case the ulnar artery does not anastomose with the radial artery or the median artery and hence the superficial palmar arch was incomplete type. This classification is simple and understandable for many anatomists and researchers and is currently in use (Gellman et al., 2001). Adachi has described 3 types of superficial palmar arch. Type A: Ulnar type - in which contribution by radial artery is absent or minimal, Type B: Radioulnar type - in which arch is formed by the superficial palmar branch of radial artery and the larger ulnar artery, Type C: Mediano ulnar type - in which arch is formed by the median artery and the larger ulnar artery. The superficial palmar arch observed in the present case is Adachi's Type A: Ulnar type (Adachi, 1928). Huber classified the superficial palmar arch into 2 types. Type 1 in which additional branches from the forearm participate in the formation of the arch or replace the radial in its composition. Type 2 in which there is no true arch, the arteries which should participate in its formation and in some cases the additional ones also, failing to anastomose and each giving rise independently to a certain number of digital branches in a somewhat fan like manner (Huber, 1930).

The superficial palmar arch seen in the present case is Huber's Type 1. Coleman and Anson elaborated more on superficial palmar arch and reclassified it as follows: Group I: Complete arch. It can be further divided into five types, they are: Type A: The classical radio ulnar arch is formed by superficial palmar branch of radial artery and the larger ulnar artery. Type B: This arch is formed entirely by ulnar artery. Type C: Mediano ulnar arch is composed of ulnar artery and an enlarged median artery. Type D: Radio-

mediano-ulnar arch in which 3 vessels enter into the formation of arch. Type E: It consists of a well formed arch initiated by ulnar artery and completed by a large sized vessel derived from deep arch. The latter vessel comes to superficial level at the base of the thenar eminence of join the ulnar artery. Group II: Incomplete arch: When the contributing arteries to the superficial arch do not anastomose or when the ulnar artery fails to reach the thumb and index finger, the arch is incomplete. It can be further divided into 4 types. Type A: Both superficial palmar branch of radial artery and ulnar artery take part in supplying palm and fingers but in doing so, fail to anastomose. Type B: Only the ulnar artery forms superficial palmar arch. The arch is incomplete in the sense that the ulnar artery does not take part in the supply of thumb and index finger. Type C: Superficial vessels receive contributions from both median and ulnar arteries but without anastomosis. Type D: Radial, median and ulnar artery all give origin to superficial vessels but do not anastomose (Coleman et al., 1961).

The superficial palmar arch seen in the present case is Coleman and Anson's Type B. Since the superficial palmar arch is the main source of arterial supply to the palm, the details about its possible variations is important for the hand surgeons. The knowledge is important while performing the superficial dissections and to the radiologists while performing the angiographic procedures. The morphology of arterial arches of hand is important for microvascular surgeons as well as orthopaedicians (Patnaik et al., 2002). The clamping of radial artery is contraindicated in cases of deficient collateral flow through the ulnar artery, as it can lead to ischemia and gangrene of the fingers (Ottone et al., 2010). The patients should be screened before harvesting the radial artery to confirm the

presence of a viable collateral circulation in the hand (Ruengsakulrach et al., 2001). It is mandatory to conduct the investigations like Allen test, angiography and colour doppler studies of the hand before starting any invasive procedures including the vascular surgeries.

The knowledge about these variant arches is essential for the safe and successful outcome of the hand surgeries. The recent advances in microsurgical techniques for the reconstruction of hand and upper extremity after trauma and congenital deformities have necessitated better understanding of the vascular patterns of the vessels. The doppler and angiographic studies allow visualization of vessels of the hand, but do not accurately assess the small connecting vessels (Ikeda et al., 1988; Starnes et al., 1999; Al-Turk et al., 2007). The hand surgeon needs to refer to the existence and healthy functioning of the arch before surgical procedures such as, arterial repairs, vascular graft applications. The radial artery contributes greatly to the circulation of the hand but in many cases it can be removed as a non-essential vessel, with adequate circulation being provided by the remaining ulnar and in some cases, persistent median artery (Starnes et al., 1999).

Developmental Basis

The ontogenic explanation of variations of superficial palmar arch was documented (Singer, 1933). The comparative study of arteries of hands in primates confirmed that the variations noted in man represent a retention or reappearance of primitive patterns. In the embryological parallelism, ontogeny recapitulates phylogeny. By the stage 21 of the embryo, the radial artery acquires its final differentiated state (Rodriguez-Niedenfuhr, 2001). The arterial variations affecting the distal course of the radial artery must have established before the 21st week of gestational stage (Ottone, 2010).

Clinical significance

Knowledge of variations of vascular patterns of hand gained more importance in microsurgical techniques, reconstructive hand surgeries, preoperative screening of radial artery harvesting for myocardial revascularization and also in arterial interventions that include radial artery cannulation and radial artery forearm flap. These variations are compared with the earlier data & it is concluded that variations in the vascular pattern of hand are a rule rather than an exception. A lack of knowledge of such type of variations with different patterns might complicate reconstruction hand surgeries (Treves, 1947).

Conclusion

The present study had provided details about some of the morphological variants of superficial palmar arch in humans which will be enlightening for the operating hand surgeons and orthopedicians. Recent advances in the microsurgical techniques for reconstructive hand surgeries have necessitated the understanding of variant arterial arches, the comprehensive knowledge of which is important for the surgical interventions and successful outcome. Scientific improvement can be achieved by thorough knowledge of anatomical variations. The detailed knowledge about the complex anatomical structures in the hand and upper extremity is essential for verifying the validity of various surgical procedures under practice and to define new.

Acknowledgement

Author is thankful to the Dean, Dr. Geeta Niyogi for her support and encouragement. I would like to thank Mr. M. Murugan, Mr. Sanjay, Mr. Pandu, Mr. Kishor, Mr. Nitin, Mr. Sankush and Mr. Raju for their help.

References

- Adachi B (1928). Das arterien system des japaner, Kyoto, Japan, Vol. I: 365, 368, 389.
- Al-Turk M, Metcalf WK (2007). A study of the superficial palmar arteries using the Doppler Ultrasonic Flow meter. S.D.Ü. Typ Fak. Derg., 14: 11-16.
- Anson BJ, Maddock WG (1952). Callender's Surgical Anatomy In: The hand-palmar region. 3rd Edn. W.B. Saunders Co. Philedelphia, USA, 831.
- Arey LB (1957). Developmental anatomy In: Development of the arteries. 6th Edn W.B. Saunder's Co. Philadelphia, USA, 375-357.
- Bataineh ZM, Moqattash ST (2006). A complex variation in the superficial palmar arch. Folia Morphol (Warsz), 65: 406-409.
- Boyd JD, Clark WE, Hamilton WJ, Yoffey JM, Zuckerman S, Appleton AB (1956). Textbook of Human Anatomy In: Cardiovascular system. Blood Vessels. Mcmillan & Co Ltd. New York., USA, 341-346.
- Coleman SS, Anson BJ (1961). Arterial patterns in the hand based upon the study of 650 specimens. Surg Gynecol Obstet., 113: 409-424.
- Datta AK (2000). Essentials of human anatomy. Superior and inferior extremities. 2nd Ed., Calcutta, Current Books International., 99-100.
- Gajisin S, Zbrodowski A (1993), Local vascular contribution of the superficial palmar arch. Acta. Anat (Basel), 147: 248-251.
- Gellman H, Botte MJ, Shankwiler J, Gelberman RH, (2001). Arterial patterns of the deep and superficial palmar arches, Clin Orthop Relat Res., 383: 41-46.
- Huber GC (1930). Piersol's Human Anatomy. In: The

- Vascular System. 9th Ed. Vol. I, J.B. Lippincot Co. Philadelphia, USA 785-791.
- Ikeda A, Ugawa A, Kazihara Y, Hamada N (1988). Arterial patterns in the hand based on a three-dimensional analysis of 220 cadaver hands. *J Hand Surg.*, 13: 501-509.
- Jelicic N, Gajisin S, Zbrodowski A (1988). Arcus palmaris superficialis, *Acta Anat (Basel)*, 132: 187-190.
- Johnson D, Ellis H, Collins P (2005). Wrist and hand. In: *Standring S, Ellis H, Healy JC, Johnson D, Williams A, Gray's Anatomy. 39th Ed.*, Edinburgh, Churchill Livingstone, 929-930.
- Manners Smith T (1910). The Limb arteries of the primates. *Journal of Anatomy and Physiology*, 45: 23-64.
- Massie G (1944). *Surgical Anatomy In: The Upper Limb 4th Edn.* J. and A Churchill Ltd. London, UK, 177-178.
- Meyer H Con (1881). Der Grand typus des Rete, der Handnurzeln und des Fusswurzel. *Archives of Anatomy and Physiology*, 45: 23-64.
- Ottone NE, Prum N, Dominguez M, Blasi E, Medan C, Shinzato S, Finkelstein D, Bertone VH (2010). Analysis and clinical importance of superficial arterial palmar irrigation and its variants over 86 cases. *International Journal of Morphology*, 28: 157-164.
- Patnaik VVG, Kalsey G, Singla RK (2002). Palmar arterial arches-a morphological study. *Journal of Anatomical Society of India*, 51: 187-193.
- Poirier P (1886). *Traite d' Anatomie Humaine* L. Battalle & Co., Paris, France, 833.
- Rodriguez-Niedenfuhr M, Burton GJ, Deu J, Sanudo JR (2001). Development of the arterial pattern in the upper limb of staged human embryos: normal development and anatomic variations. *Journal of Anatomy*, 199: 407-417.
- Romanes GJ (2012). *Cunningham's Manual of Practical Anatomy In: The Upper limb- The forearm & Hand. Vol I, 15th Ed.* Oxford University Press, Oxford, UK: 74-104.
- Ruengsakulrach R, Eizenberg N, Fahrer C, Fahrer M. Buxton BF (2001). Surgical implications of variations in hand collateral circulation: Anatomy revisited. *The Journal of Thoracic and Cardiovascular Surgery*, 122 (4): 682-686.
- Singer E (1933). Embryological patterns persisting in the arteries of the arm. *Anatomical Record*, 55: 406-413.
- Snell R. S., (2004), *Clinical Anatomy*, 7th ed. Baltimore, Lippincott Williams and Wilkins: 545.
- Starnes SL, Wolk SW, Lampman RM, Shanley C, Parger RL, Kong BK., Fowler JJ, Page JM, Babcock, (1999). Noninvasive evaluation of hand circulation before radial artery harvest for coronary artery bypass grafting. *Journal of Thoracic and Cardiovascular Surgery*, 117: 261-266.
- Taoyl (1984). Superficial palmar arch, *Journal of Anatomy*, 138: 27-32.
- Treves FB, Rogers L (1947). *Surgical Applied Anatomy. In: The Upper Extremity. 11th Edn.* Cassell & Co. London, UK, 265- 266.