



RESEARCH ARTICLE

A morphological study of termination of popliteal artery with its clinical significance

Sharadkumar Pralhad Sawant

Department of Anatomy, K. J. Somaiya Medical College, Somaiya Ayurvihar

Eastern Express Highway, Sion, Mumbai-400 022, India

Corresponding author: E-mail: drspsawant@gmail.com; Phone: +91-9322061220

Abstract

Out of 120 specimens of inferior extremities the normal termination of popliteal artery at the lower border of popliteal muscle into anterior tibial and posterior tibial arteries was observed in 52 specimens (43.33%) i.e. Group A. The trifurcation of popliteal artery was seen in 6 specimens (5%) i.e. Group B, In Group C, 4 specimens (3.33%) showed the origin of the peroneal artery from the low anterior tibial artery. In Group D, 2 specimens (3.33%) showed "Island" of popliteal artery. In 16 specimens (13.33%) the anterior tibial artery originated from popliteal artery proximal to the popliteus muscle and travelled downwards on the posterior surface of the popliteus muscle i.e. Group E. In Group F, 4 specimens (3.33%) showed the anterior tibial artery originated from popliteal artery proximal to the popliteus muscle. It travelled downwards on the posterior surface of the popliteus muscle and gave origin to the peroneal artery. In Group G, 10 specimens (8.33%) showed the anterior tibial artery originated from popliteal artery proximal to the popliteus muscle. It travelled downwards on the anterior surface of the popliteus muscle. In Group H, 6 specimens (5%) showed the anterior tibial artery originated from popliteal artery proximal to the popliteus muscle. It travelled downwards on the anterior surface of the popliteus muscle and gave origin to the peroneal artery. In 6 specimens (5%) the posterior tibial artery was absent i.e. Group I. In Group J, 8 specimens (6.67%) showed the small anterior tibial artery. The dorsalis pedis artery was given by the posterior tibial artery and in Group k, 6 specimens (5%) showed the small anterior and posterior tibial artery. The dorsalis pedis artery was given by the peroneal artery. There is a convenient and preferred surgical procedure. The knowledge of variant termination of popliteal artery is important during arthroscopic knee surgery in order to minimize the surgical complications. The variation in the termination of the popliteal artery should be kept in mind by the orthopaedicians doing knee joint surgery and total knee arthroplasty, by the surgeons operating on aneurysms of popliteal artery and by the radiologist performing angiographic study.

Keywords: popliteal artery, popliteus muscle, anterior tibial artery, peroneal artery, posterior tibial artery

Received: 28th January; Revised: 26th February; Accepted: 14th March; © IJCS New Liberty Group 2013

Introduction

The popliteal artery is the continuation of the femoral artery. It begins at the level of hiatus magnus and ends at the lower border of popliteal muscle by dividing into anterior tibial and posterior tibial arteries (Standring, 2008). The popliteus muscle is the 'key muscle' of the popliteal

region. The popliteal artery may divide proximal to the lower border of popliteal muscle. This is called as 'high division of the popliteal artery'. In high division, the anterior or posterior branch may arise at or above the articular surface of the tibial plateau (Adachi, 1928). When the popliteal artery divides any where proximal to the lower

border of the muscle, it is termed as, high division of the popliteal artery (Lippert et al., 1985). The anterior tibial artery runs downwards on the posterior surface of the popliteus muscle and then it enters in to the anterior compartment of the leg through the oval space located at the superior border of the interosseous membrane of the leg. There it travels on the anterior surface of the interosseous membrane along with the deep peroneal nerve (Standring, 2008). The popliteal artery may divide proximal to the popliteus muscle into anterior and posterior tibial arteries. The anterior tibial artery descends downward either anterior or posterior to the popliteus muscle (Standring, 2008). The popliteal artery may terminate distal to the lower border of popliteus muscle which may interfere with the reconstruction surgeries (Kim et al., 1989).

The variations in the branching pattern of the popliteal artery increase the risk of vascular trauma and unnecessary haemorrhage during arthroscopic surgery of knee joint. Preoperative diagnosis of variations in the branching pattern of the popliteal artery may help to avoid excessive unwanted haemorrhage and unnecessary complications during surgery (Klecker et al., 2008). The knowledge of variations in the branching pattern of the limb arteries is important for the success of the arthroscopic surgeries. It may have clinical implications regarding vascular grafting, direct surgical repair, transluminal angioplasty, embolectomy, or the diagnosis of arterial injury. In addition, knowledge of the embryology of the popliteal artery provides a better understanding of the development of atherosclerotic popliteal artery aneurysms and the popliteal artery entrapment syndrome (Senior, 1929).

Materials and Methods

The study was performed on 60 (120 specimens of Inferior Extremities) embalmed donated cadavers (55 males and 5 females) in the department of Anatomy of K.J. Somaiya Medical College, Sion, Mumbai, India. In order to study the variant termination of popliteal artery the 100 specimens were classified into ten groups depending on the termination of popliteal artery and the course of its terminal branches. The photographs of the variations were taken for proper documentation and ready reference. There were no associated neuromuscular variations found in specimens. All the variations were unilateral.

Observations

Out of 120 specimens of inferior extremities the normal termination of popliteal artery at the lower border of popliteal muscle into anterior tibial and posterior tibial arteries was observed in 52 specimens (43.33%) i.e. Group A. The trifurcation of popliteal artery was seen in 6 specimens (5%) i.e. Group B, In Group C, 4 specimens (3.33%) showed the origin of the peroneal artery from the low anterior tibial artery. In Group D, 2 specimens (3.33%) showed "Island" of popliteal artery. In 16 specimens (13.33%) the anterior tibial artery originated from popliteal artery proximal to the popliteus muscle and travelled downwards on the posterior surface of the popliteus muscle i.e. Group E. In Group F, 4 specimens (3.33%) showed the anterior tibial artery originated from popliteal artery proximal to the popliteus muscle. It travelled downwards on the posterior surface of the popliteus muscle and gave origin to the peroneal artery. In Group G, 10 specimens (8.33%) showed the anterior tibial artery originated from popliteal artery proximal to the popliteus muscle. It travelled downwards on the anterior surface of the

popliteus muscle. In Group H, 6 specimens (5%) showed the anterior tibial artery originated from popliteal artery proximal to the popliteus muscle. It travelled downwards on the anterior surface of the popliteus muscle and gave origin to the peroneal artery. In 6 specimens (5%) the posterior tibial artery was absent i.e. Group I. In Group J, 8 specimens (6.67%) showed the small anterior tibial artery. The dorsalis pedis artery was given by the posterior tibial artery and in Group k, 6 specimens (5%) showed the small anterior and posterior tibial artery. The dorsalis pedis artery was given by the peroneal artery.

Fig. 1. Normal termination of popliteal artery

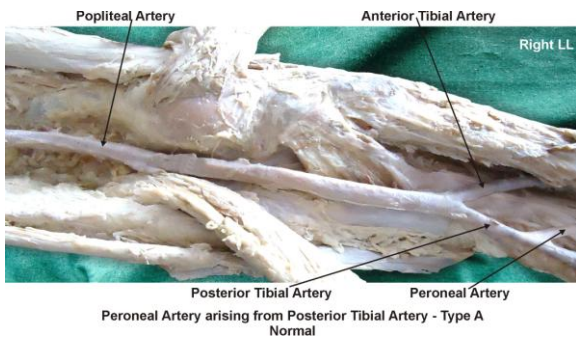


Fig. 2. Trifurcation of popliteal artery

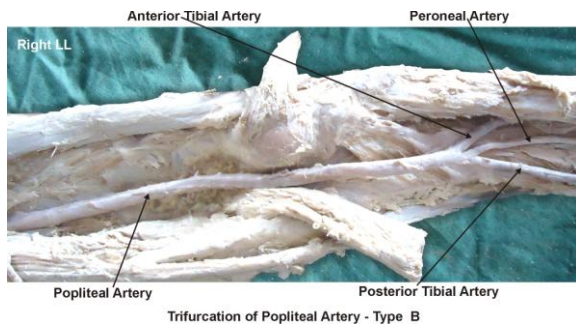


Fig. 3. Peroneal artery arising from low anterior tibial artery

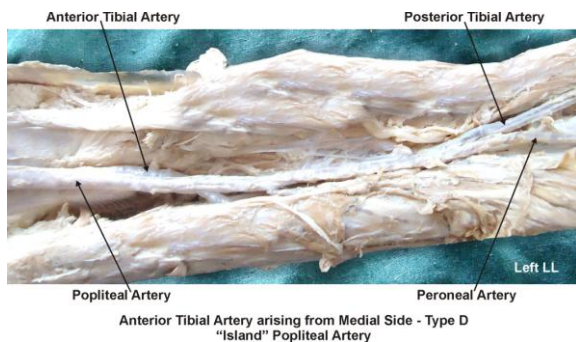


Fig. 4. Anterior tibial artery arising from medial side of the popliteal artery

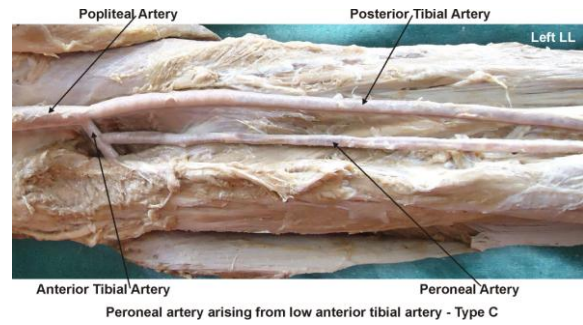


Fig. 5. High origin of anterior tibial artery from the popliteal artery and the anterior tibial artery passes superficial to the popliteus muscle

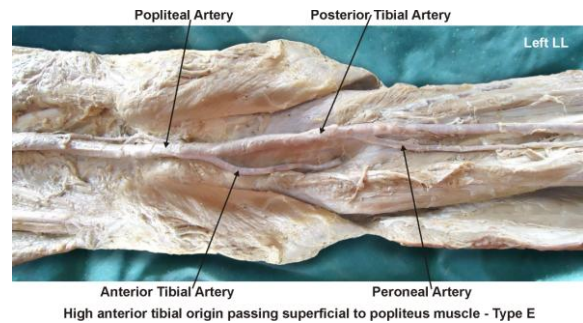


Fig. 6. High origin of anterior tibial artery from the popliteal artery passing superficial to the popliteus muscle and giving origin to the peroneal artery

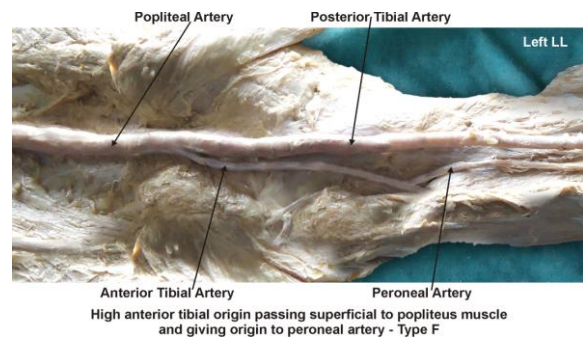


Fig. 7. High origin of anterior tibial artery (popliteal and anterior tibial artery) passes deep to the popliteus muscle

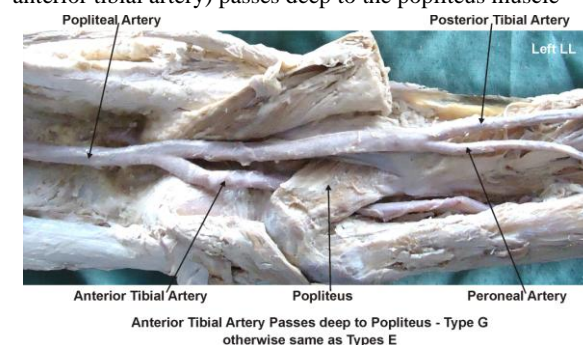


Fig. 8. High origin of anterior tibial artery from the popliteal artery passing deep to the popliteus muscle and giving origin to the peroneal artery

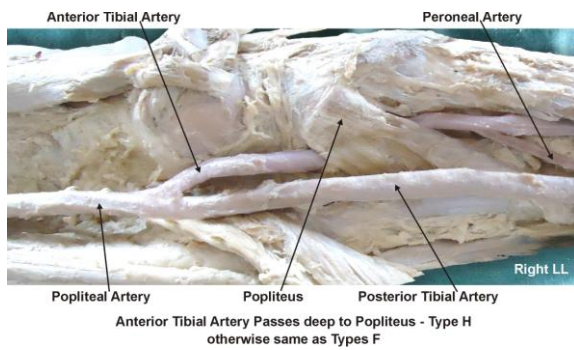


Fig. 9. Unusual termination of popliteal artery into anterior tibial artery and peroneal artery

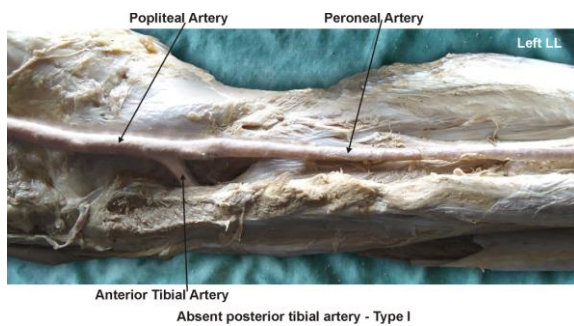


Fig. 10. Small anterior tibial artery and the dorsalis pedis artery arising from posterior tibial artery

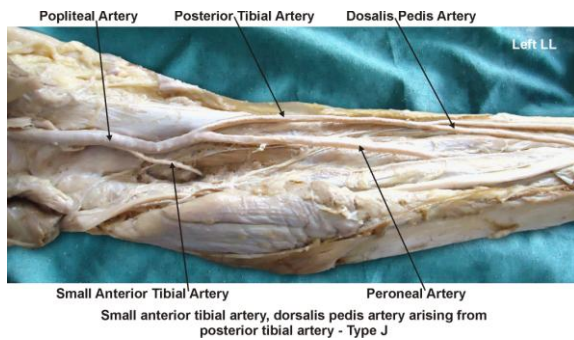
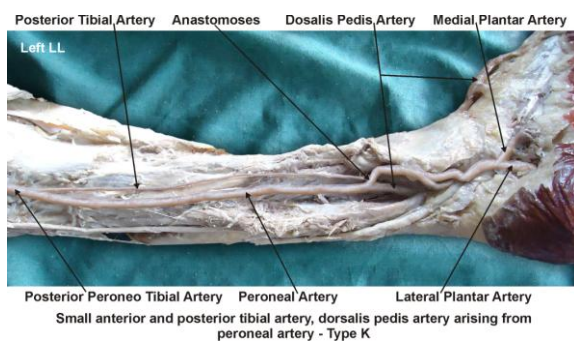


Fig. 11. Small anterior and posterior tibial artery and the dorsalis pedis artery arising from peroneal artery



Discussion

The variations in the branching pattern of the popliteal artery are common. The high level termination of the popliteal artery in relation to the upper border of the popliteus muscle was grouped into 3 types by Adachi. In type I the popliteal artery descended on the posterior surface of the popliteus muscle. The popliteal artery divides into the posterior peroneotibial trunk and the anterior tibial artery (Adachi, 1928). The posterior peroneotibial trunk further divides into the peroneal artery and the posterior tibial artery. The diameter of the anterior tibial artery was equal to the popliteal artery or smaller than the posterior peroneotibial trunk. In type II the popliteal artery descended on the posterior surface of the popliteus muscle. It was divided into the posterior tibial artery and the anterior peroneotibial trunk. The diameter of the anterior peroneotibial trunk was observed to be larger. The anterior peroneotibial trunk divided into the peroneal artery and anterior tibial artery at the lower border of the popliteus muscle. In type III the popliteal artery terminated into the anterior tibial artery and posterior peroneotibial trunk at the upper border of the popliteus muscle. The anterior tibial artery ran downward in between the anterior surface of the popliteus muscle and the posterior surface of the tibia. The posterior peroneotibial trunk ran on the posterior surface of the popliteus muscle. The posterior peroneotibial trunk divided into the peroneal artery and posterior tibial artery distal to the tendinous arch of soleus muscle (Adachi, 1928).

In the present study, out of 120 specimens of inferior extremities in 58 specimens the popliteal artery descended on the posterior surface of the popliteus muscle. It divided into the posterior peroneotibial trunk and the anterior tibial artery. The posterior peroneotibial trunk

Table 1. The variant termination of popliteal artery observed in present study

Groups	Termination of popliteal artery	No. of specimens	Total specimens	%
A	Normal termination of popliteal artery	52	120	43.33
B	Trifurcation of popliteal artery	6	120	05.00
C	Peroneal artery arising from low anterior tibial artery	4	120	03.33
D	“Island” of popliteal artery	2	120	01.67
E	High anterior tibial origin passing superficial (posterior) to popliteus	16	120	13.33
F	High anterior tibial origin passing superficial (posterior) to popliteus giving origin to peroneal artery	4	120	03.33
G	High anterior tibial origin passing deep (anterior) to popliteus	10	120	08.33
H	High anterior tibial origin passing deep (anterior) to popliteus giving origin to peroneal artery	6	120	05.00
I	Absent posterior tibial artery	6	120	05.00
J	Small anterior tibial artery, dorsalis pedis artery arising from posterior tibial artery	8	120	06.67
K	Small anterior and posterior tibial arteries, dorsalis pedis artery arising from peroneal artery	6	120	05.00

further divided into the peroneal artery and the posterior tibial artery. The diameter of the anterior tibial artery was equal to the popliteal artery. Thus the variation in the termination of popliteal artery observed in these specimens is of Adachi's type I. The trifurcation of popliteal artery was seen in 6 specimens. Such type of variations is not documented in literature. In 4 specimens the popliteal artery descended on the posterior surface of the popliteus muscle. It was divided into the posterior tibial artery and the anterior peroneotibial trunk. The diameter of the anterior peroneotibial trunk was observed to be larger. The anterior peroneotibial trunk divided into the peroneal artery and anterior tibial artery at the lower border of the popliteus muscle. Thus the variations in the termination of popliteal artery observed in these specimens are of Adachi's type II. In 2 specimens the anterior tibial artery originated from the medial side of the popliteal artery. The anterior tibial artery turned downward and laterally in between the posterior surface of the popliteus muscle and the posterior peroneotibial trunk. Posterior peroneotibial trunk divides into the posterior tibial and peroneal arteries.

The peroneal artery was larger than the posterior tibial artery. The diameter of the anterior tibial artery was smaller than the posterior peroneotibial trunk. Thus the variations seen in these specimens are of Adachi's type I. In 16 specimens the anterior tibial artery originated from popliteal artery proximal to the popliteus muscle and travelled downwards on the posterior surface of the popliteus muscle. The variations seen in these specimens are of Adachi's type I. In 4 specimens the anterior tibial artery originated from the popliteal artery proximal to the popliteus muscle and travelled downwards on the posterior surface of the popliteus muscle. It gave origin to the peroneal artery at the level of the lower border of the popliteus muscle. The variations seen in these specimens are of Adachi's type II. In 10 specimens the anterior tibial artery originated from popliteal artery proximal to the popliteus muscle. It travelled downwards on the anterior surface of the popliteus muscle. Such type of variations is not documented in literature. In 6 specimens the anterior tibial artery originated from popliteal artery proximal to the popliteus muscle. It travelled downwards on the anterior

surface of the popliteus muscle and gave origin to the peroneal artery.

The variations seen in these specimens are of Adachi's type III. In 6 specimens the posterior tibial artery was absent and not documented in literature. In 8 specimens the anterior tibial artery was small. The variations seen in these specimens are of Adachi's type I. Normally the diameter of the posterior tibial artery is more than the diameter of the peroneal artery, but in present study the diameter of the peroneal artery was observed more than the diameter of the posterior tibial artery in 8 specimens which is similar to the study of Ozgur (Ozgur et al., 2009). It was reported in previous studies that the course of anterior tibial artery could either be from the anterior or posterior surface of the popliteus muscle (Day et al., 2006; Kil et al., 2009). The course of anterior tibial artery on the anterior surface of the popliteus muscle was observed in 1-2.1% of the cases (Day et al., 2006; Tindall et al., 2006; Klecker et al., 2008; Kil et al., 2009).

The course of anterior tibial artery on the posterior surface of the popliteus muscle was observed in 40% of the cases. In present study the course of anterior tibial artery on the posterior surface of the popliteus muscle was observed in 90 specimens (75%) and the course of anterior tibial artery on the anterior surface of the popliteus muscle was observed in 16 specimens (13.33%). The clinicians and the radiologists have defined a different terminology of the popliteal artery and its main branches in popliteal surgery. The anterior tibial artery was defined as the tibial-fibular trunk as soon as it branched from the popliteal artery (Day et al., 2006). The tibial arteries were referred to as anterior or posterior peroneotibial trunk depending upon the origin of the peroneal artery. Anatomic variants will influence the surgical approach and dissection and the choice of suitable

arterial graft sites. The trifurcating popliteal artery seen in 6 specimens (5%) may create a technical challenge during angioplasty or embolectomy. The knowledge of an absent posterior or anterior tibial artery may prevent false diagnosis of arterial damage in trauma when the normal ankle pulses are absent or diminished. In the absence of the posterior and anterior tibial arteries, the peroneal artery serves as the main source of blood supply to the foot (Uppert et al., 1985).

Developmental Basis of Variant Popliteal Artery

The lower extremity blood supply is detectable in the 9-mm embryo (Senior, 1929). The sciatic artery, also referred to as the ischiatic or axial artery, is a branch of the internal iliac artery and is the major supplier to the early developing limb bud. By the 14 mm embryo stage, the femoral artery, a branch of the external iliac artery, has anastomosed with the sciatic artery and become the major supply vessel to the lower limb (Bardsley, 1970).

The more proximal sciatic artery regresses to be represented by the inferior gluteal artery and the artery to the sciatic nerve in the adult. The primitive middle and distal sciatic artery segments persist to form the definitive popliteal and peroneal arteries. The anterior tibial artery arises as a branch of the popliteal artery and initially runs anteriorly (deep) to the popliteus muscle. This is the usual definitive primate anatomy. In humans, however, the early anterior tibial artery is replaced by a superficial popliteal artery that passes posteriorly (superficially) to the popliteus muscle, which then gives rise to the definitive anterior tibial artery (Bardsley, 1970). The posterior tibial artery is formed by an anastomosis between the early distal femoral artery and the popliteal artery (Arey, 1974). The definitive anatomy is completed by 3 months gestation (Senior, 1929). The embryonic vascular development determines

the anatomic variability. Thus, embryonic vessels may either persist or degenerate (degeneration of these vessels is normal), or abnormal fusions may occur (Arey, 1974). Many of the variants can be explained by combinations of persistent primitive arterial segments, abnormal fusions, or segmental hypoplasia or absence (Arey, 1974).

Clinical significance

The arthroscopic knee surgery is a convenient and preferred surgical procedure. The knowledge of branching pattern of the popliteal artery is important for surgical interventions in the popliteal region in order to minimize the surgical complications.

Conclusion

The knowledge of variant termination of popliteal artery is important for the orthopaedicians doing knee joint surgery and total knee arthroplasty, for the surgeons operating on aneurysms of popliteal artery and for the radiologists performing angiographic study. Also the knowledge of such type of variation may have clinical implications regarding vascular grafting, direct surgical repair, transluminal angioplasty, embolectomy, or the diagnosis of arterial injury.

Acknowledgement

I would like to thank to Dr. Arif A. Faruqui for his support and also thankful to Mr. M. Murugan for his help.

References

Adachi B (1928). *Das Arteriensystem der Japaner*, band 2. Kyoto, Kenkyusha 198-201.

Arey LB (1974). *Developmental anatomy*, 7th Ed. Philadelphia, USA, Saunders, 358-360.

Bardsley JL (1970). Variations in branching of the popliteal artery, *Radiology*, 94: 581- 87.

Day CP, Orme R (2006). Popliteal artery branching patterns-an angiographic study. *Clinical Radiology*, 61: 696-699.

Kil SW, Jung GS (2009). Anatomical variations of the popliteal artery and its tibial branches: analysis in 1242 extremities. *Cardiovascular Interventional Radiology*, 32: 233-240.

Kim D, Orron DE, Skillman JJ (1989). Surgical significance of popliteal arterial variants. A unified angiographic classification. *Ann. Surg.*, 210:776-781.

Klecker RJ, Winalski CS, Aliabadi P, Minas T (2008). The aberrant anterior tibial artery: magnetic resonance appearance, prevalence, and surgical implications. *American Journal of Sports Medicine*, 36: 720-727.

Lippert H, Pabst R (1985). Arterial variations in man: classification and frequency. Munchen, J. F. Bergman Verlag., Germany, 62.

Ozgun Z, Ucerler H, Aktan Ikiz ZA (2009). Branching patterns of the popliteal artery and its clinical importance. *Surgical Radiological Anatomy*, 31: 357-362.

Senior HD (1929). Abnormal branching of the popliteal artery. *American Journal of Anatomy*, 44 : 111-120.

Standring S (2008). *Gray's Anatomy*. 40th Ed., London, Churchill Livingstone, 1408, 1424.

Tindall AJ, Shetty AA, James KD, Middleton A, Fernando KW (2006). Prevalence and surgical significance of a high-origin anterior tibial artery. *J Orthop Surg.*, (Hong Kong), 14: 13-16.

Uppert H, Pabst A (1985). Arterial variations in man: classification and frequency. Munich: Bergmann Verlag., Germany, 60-64.