

Morphological Study of Connection Between the Median and the Musculocutaneous Nerves.

Sharadkumar Pralhad Sawant,

Associate Professor, Department of Anatomy, K. J. Somaiya Medical College,
Mumbai-400 022.

ABSTRACT

Aim : To study the connections between the musculocutaneous nerve and the median nerve.

Materials and Methods : 100 upper limbs of 50 donated embalmed cadavers (45 males & 5 females) of age group ranging from 70 to 80 years were studied in the department of Anatomy at K. J. Somaiya Medical College, Sion, Mumbai, INDIA, the connections between the median nerve and the musculocutaneous nerve were observed. The finding was noted after thorough and meticulous dissection of the upper limbs of both sides (axilla, arm, forearm and palm). The arterial pattern in the arm (axillary and brachial arteries) was also observed. The photographs of the connections were taken for proper documentation.

Observations : Out of 100 specimens the variations in the connections between the median nerve and the musculocutaneous nerve were found in 30 specimens i.e. 30% of the total specimens. Out of 30 specimens, 4 specimens showed the median nerve getting the communicating branch from the musculocutaneous nerve, 6 specimens showed the formation of the median nerve by medial and lateral roots in the middle of the arm; 12 specimens showed that the musculocutaneous nerve travelled some distance with the median nerve and then it got separated from the median nerve, the remaining 8 specimens showed that all the muscles of the front of the arm were supplied by the median nerve. The musculocutaneous nerve was absent. There was no associated arterial variations seen in any of the specimens.

Conclusion : The presence of such type of variations are clinically important for surgeons, orthopaedicians and anaesthetist performing pain management therapies on the upper limb. These variations are compared with the earlier data & it is concluded that variations in branching pattern of cords of brachial plexus are a rule rather than exception.

KEY WORDS Axilla, Brachial plexus, Median Nerve, Brachial Artery, Musculocutaneous nerve, Communicating branch, Mid arm position, Pain Management Therapies,

Surgeons, Orthopaedicians.

INTRODUCTION

The median nerve is normally formed by the union of lateral root of median nerve arising from the lateral cord (C5, C6, C7) of brachial plexus and medial root of median nerve arising from the medial cord (C8, T1) of brachial plexus anterior to the axillary artery. Some fibres from C7 often leave the lateral root to join the ulnar nerve. Clinically they are believed to be mainly motor to the flexor carpi ulnaris. The median nerve enters the arm at first lateral to the brachial artery. Near the insertion of the coracobrachialis, it crosses in front of the artery, descending medial to it, to the cubital fossa, where it is posterior to the bicipital aponeurosis and anterior to the brachialis. It usually enters the forearm between the heads of the pronator teres, crossing to the lateral side of the ulnar artery and separated from it by the deep head of pronator teres¹. Anomalous pattern of the median nerve can be explained on the basis of embryological development. The upper limb buds lie opposite the lower five cervical and upper two thoracic segments. As soon as the buds form, the ventral primary rami of the spinal nerves penetrate into the mesenchyme of limb bud. Immediately the nerves enter the limb bud, they establish intimate contact with the differentiating mesodermal condensations and the early contact between nerve and muscle cells is a prerequisite for their complete functional differentiation². The growth as well as the path finding of nerve fibres towards the target is dependent upon concentration gradient of a group of cell surface receptors in the environment. Several signalling molecules and transcription factors have been identified which induce the differentiation of the dorsal and ventral motor horn cells. The high percentage of anomalies as mentioned above emphasizes the complexities and irregularities of this anatomic region with regard to surgical approaches³. Knowledge of such variations is important for surgeons to perform surgical procedures in the axillary region and arm⁴. Considering the high percentage of anomalies in the

formation of median nerve and its paramount clinical importance, the present variations are documented.

Variations in the formation and branching pattern of the brachial plexus constitute an important anatomical and clinical entity and have been reported by several investigators^{5,6,7}. The median, musculocutaneous and ulnar nerves after their origin from the brachial plexus, pass through the anterior compartment of the arm without receiving any branch from any nerve in the neighbourhood⁸. Although the communications between the different nerves in the arm are rare, those between the median nerve (MN) and musculocutaneous nerve (MCN) have been described from nineteenth century⁹. Knowledge of anatomical variation of these nerves at the level of upper arm is essential in light of the frequency with which surgery is performed in the axilla and the surgical neck of the humerus¹⁰.

MATERIALS AND METHODS

100 upper limbs of 50 donated embalmed cadavers (45 males & 5 females) of age group ranging from 70 to 80 years were studied in the department of Anatomy at K. J. Somaiya Medical College, Sion, Mumbai, INDIA, an anastomosis between the median nerve and the musculocutaneous

nerve were observed. The finding was noted after thorough and meticulous dissection of the upper limbs of both sides (axilla, arm, forearm and palm). The arterial pattern in the arm (axillary and brachial arteries) was also observed. The photographs of the anastomosis were taken for proper documentation.

OBSERVATIONS

Out of 100 specimens the variations in the anastomosis between the median nerve and the musculocutaneous nerve were found in 30 specimens i.e. 30% of the total specimens (Table - 1). Out of 30 specimens, 4 specimens showed the median nerve getting the communicating branch from the musculocutaneous nerve, 6 specimens showed the formation of the median nerve by medial and lateral roots in the middle of the arm; 12 specimens showed that the musculocutaneous nerve travelled some distance with the median nerve and then it got separated from the median nerve, the remaining 8 specimens showed that all the muscles of the front of the arm were supplied by the median nerve. The musculocutaneous nerve was absent. There was no associated arterial variations seen in any of the specimens

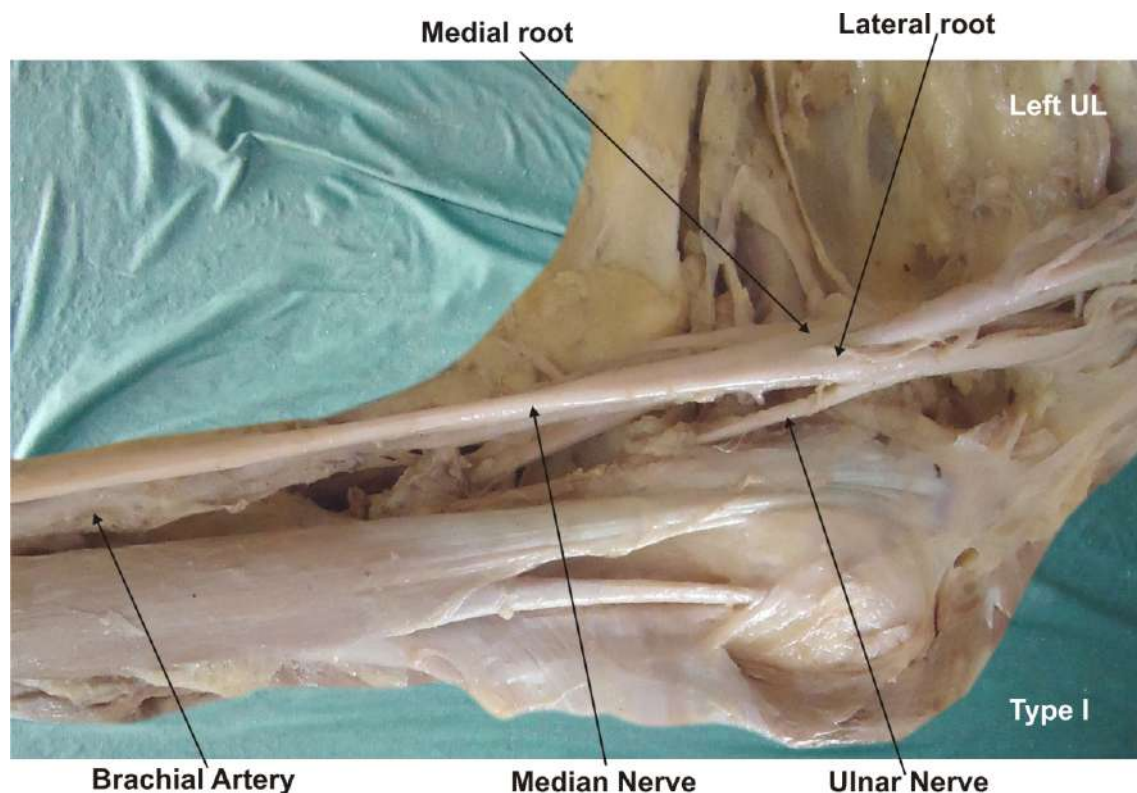


Fig. 1 : Photographic presentation of Type I - there is no communication between the median nerve and the musculocutaneous nerve.

Fig. 2 : Photographic presentation of Type II - the fibers of the lateral root of the median nerve pass through the musculocutaneous nerve and join the median nerve in the middle of the arm.

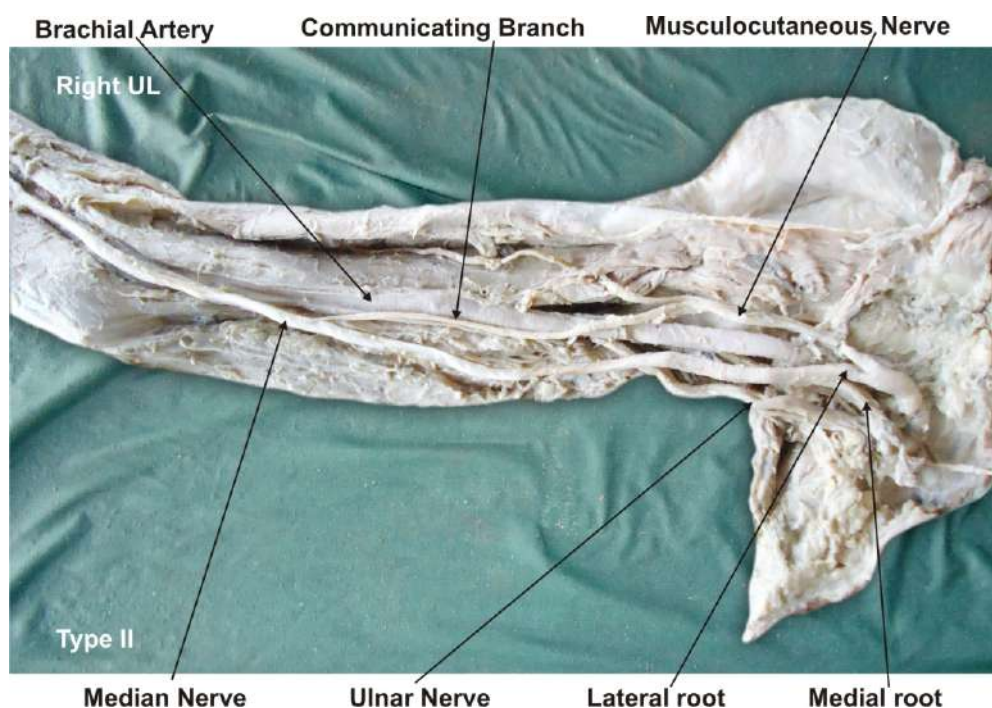


Fig. 3 : Photographic presentation of Type III - the lateral root fibers of the median nerve pass along the musculocutaneous nerve and after some distance, leave it to form the lateral root of the median nerve.

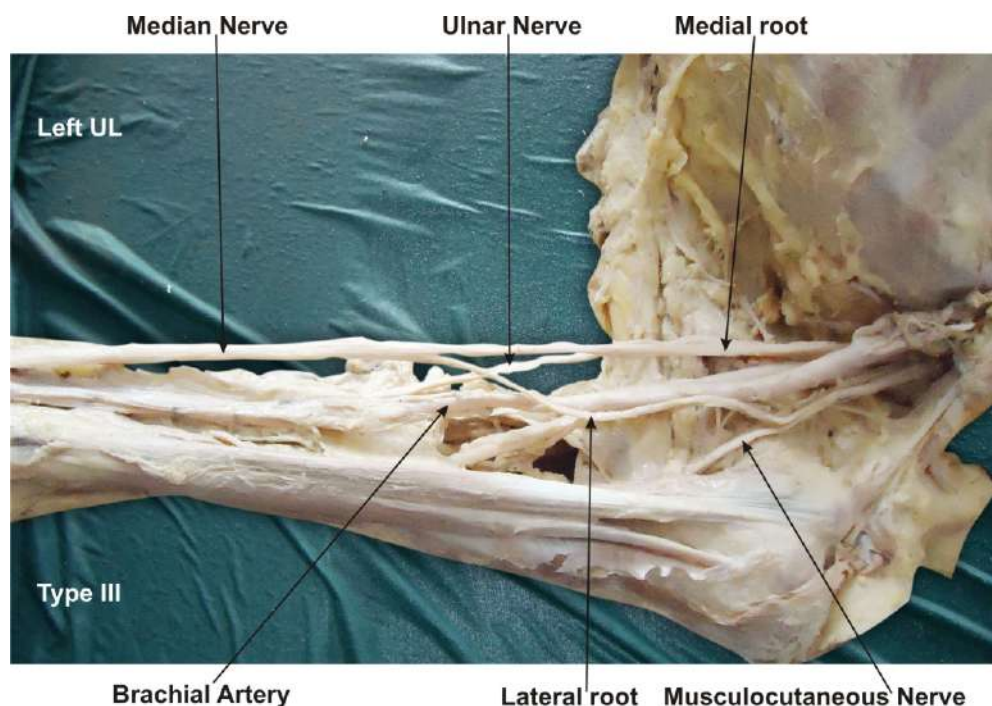


Fig. 4 : Photographic presentation of Type IV - the musculocutaneous nerve fibers join the lateral root of the median nerve and after some distance the musculocutaneous nerve arises from the median nerve.

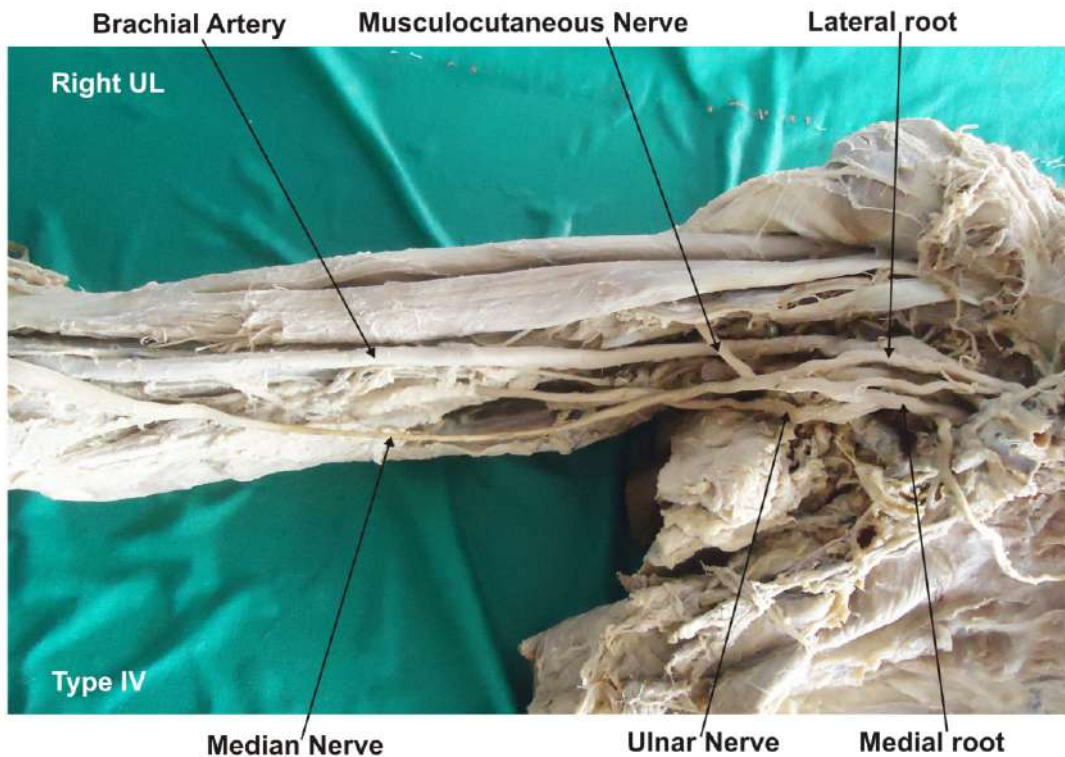


Fig. 5 : Photographic presentation of Type I - the musculocutaneous nerve is absent and the entire fibers of the musculocutaneous nerve pass through the lateral root and fibers to the muscles supplied by the musculocutaneous nerve branch out directly from the median nerve.

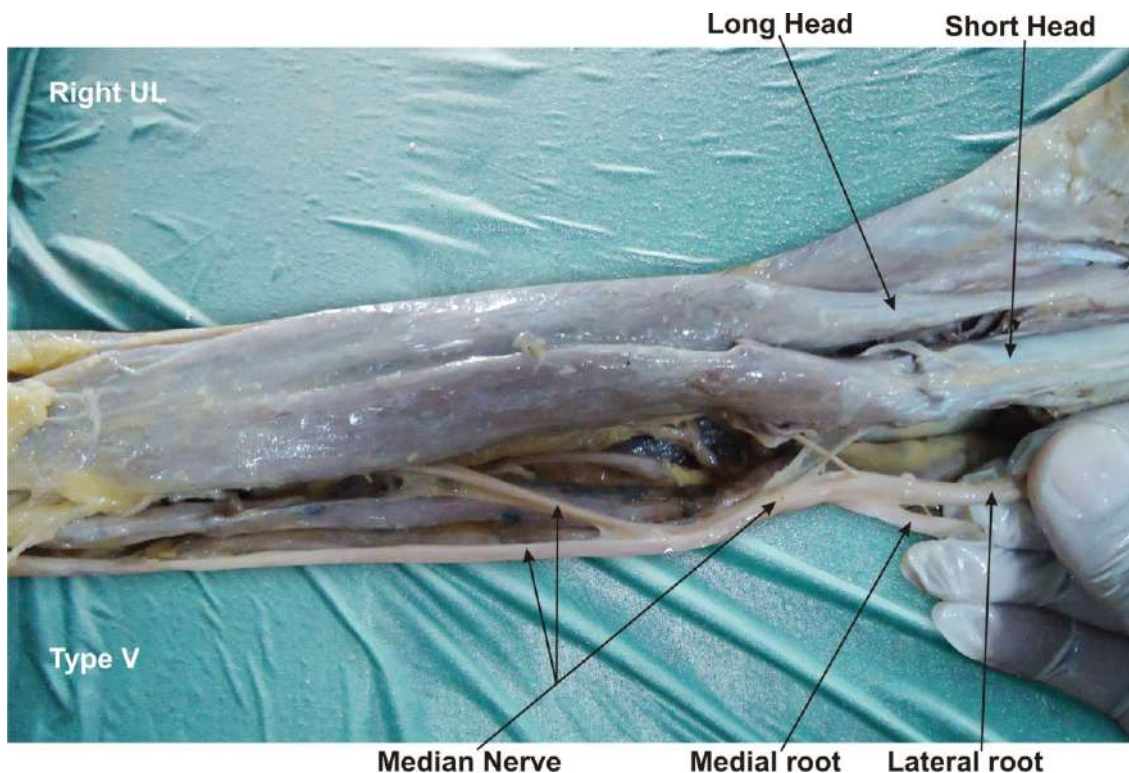


Table - 1 : The incidence of anastomosis between the musculocutaneous nerve and the median nerve as gleaned from literature

Sr. no.	Author	Year	Incidence (%)
1	Watanabe et al ¹¹	1985	01.4
2	Kosugi, Mortia and Yamashita ¹²	1986	21.8
3	Venieratos and Anagnostopoulou ¹³	1998	13.9
4	Choi et al ¹⁴	2002	26.4
5	Loukas and Aqueelah ¹⁵	2008	63.5
6	Guerri-Guttenberg and Ingolotti ¹⁶	2009	53.6
7	Maeda et al ¹⁶	2009	41.5
8	Sawant et al (present study)	2012	30

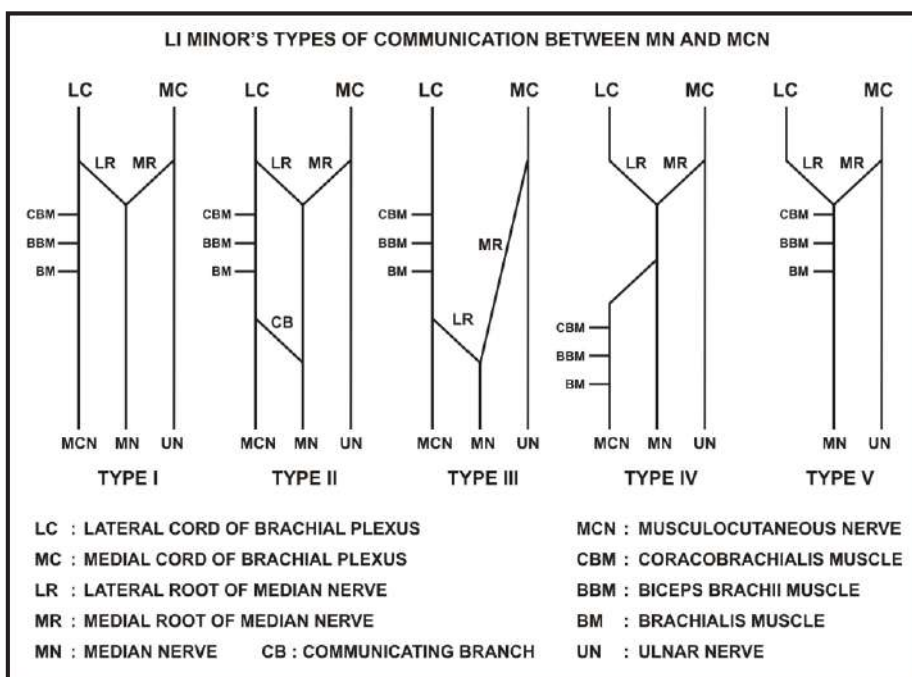


Table - 2 : Li Minor's classification

Li Minor's Type	No. of specimens	%
I	70	70
II	4	4
III	6	6
IV	12	12
V	8	8

Table - 3 : Venierators and Anagnostopoulou's classification.

Venierators and Anagnostopoulou's Type	No. of specimens	%
I	22	22
II	Nil	Nil
III	8	8

DISCUSSION

Anastomosis between the musculocutaneous nerve and the median nerve is by far the most common and frequent of all the variations that are observed among the branches of the brachial plexus¹³. Above Table depicts the incidence of communication between musculocutaneous nerve and median nerve irrespective of its site or type as reported in literature. It is seen to vary between wide ranges of 1.4% to 63.5%. The communication between the musculocutaneous nerve and the median nerve have been classified in different types by Venieratos and Anagnostopoulou, Choi et al and Li Minor^{13,14,18}. Li Minor categorized these communications into following five types: In type I, there is no communication between the median nerve and the musculocutaneous nerve, in type II, the fibers of the lateral root of the median nerve pass through the musculocutaneous nerve and join the median nerve in the middle of the arm, whereas in type III, the lateral root fibers of the median nerve pass along the musculocutaneous nerve and after some distance, leave it to form the lateral root of the median nerve. In type IV, the musculocutaneous nerve fibers join the lateral root of the median nerve and after some distance the musculocutaneous nerve arises from the median nerve. In type V, the musculocutaneous nerve is absent and the entire fibers of the musculocutaneous nerve pass through the lateral root and fibers to the muscles supplied by the musculocutaneous nerve branch out directly from the median nerve¹⁸.

In the present study all the above mentioned types of communication between the musculocutaneous nerve and the median nerve were observed (Table - 2). Out of 30 specimens, 4 specimens showed the median nerve getting the communicating branch from the musculocutaneous nerve i.e. Type II. 6 specimens showed the formation of the median nerve by medial root and lateral root in the middle of the arm i.e. Type III. 12 specimens showed the

musculocutaneous nerve travels some distance with the median nerve and then it got separation from the median nerve i.e. Type IV. 8 specimens showed that all the muscles of the front of the arm were supplied by the median nerve. The musculocutaneous nerve was absent i.e. Type V. The remaining 70 specimens showed no communication between the musculocutaneous nerve and the median nerve i.e. Type I of Li Minor's classification.

Similarly based upon its site with relation to the coracobrachialis muscle Venieratos and Anagnostopoulou¹³ classified this communication into three types. In type I, communication between the musculocutaneous nerve and the median nerve is proximal to the entrance of the musculocutaneous nerve into the coracobrachialis, whereas in type II, the communication is distal to the muscle and in type III neither the nerve nor its communicating branch pierces the muscle. In the present study (Table - 3) 22 specimens are of Type II and 8 specimens are of type III of Venieratos and Anagnostopoulou's classification.

Later on Choi et al.¹⁴ in a study on 138 cadavers classified these communications into three types. The first pattern comprised of fusion of both nerves (19.2%). Pattern 2 showed the presence of one supplementary branch between both nerves (72.6%). This type was further subdivided as Pattern 2a, where a single root from musculocutaneous nerve, contributes to the connection (69.9%) while in Pattern 2b there are two roots from musculocutaneous nerve (2.7%). Pattern 3 showed presence of two branches between both nerves (6.8%). The most frequent variation is the presence of a communicating branch that emerges from the musculocutaneous nerve and goes distally to join the median nerve, an anastomosis observed in the lower third of arm.^{7,13} If this branch is given off in upper third of the arm, it is generally considered as third (double lateral) root of the median nerve⁷. The median nerve, instead of having two roots may have three roots - either one each from lateral cord, medial cord and the

musculocutaneous nerve^{19,20} or two from lateral cord and one from the medial cord²¹ or it may have even four roots - three from the lateral cord and one from the medial cord.²²

Ontogeny : The presence of such different types of anastomosis between the median nerve and the musculocutaneous nerve documented in 15 cases may be attributed to random factors influencing the mechanism of formation of limb muscles and the peripheral nerves during embryonic life. Significant variations in nerve patterns may be a result of altered signaling between mesenchymal cells and neuronal growth cones²³ or circulatory factors at the time of fusion of brachial plexus cords¹². Iwata believed that the human brachial plexus appears as a single radicular cone in the upper limb bud, which divides longitudinally into ventral and the dorsal segments²⁴. The ventral segments give roots to the median and the ulnar nerves with musculocutaneous nerve arising from the median nerve. He further kept the possibility of failure of the differentiation as a cause for some of the fibers taking an aberrant course as a communicating branch. Chiarapattanakom et al.²⁵ are of the opinion that the limb muscles develop from the mesenchyme of local origin, while axons of spinal nerves grow distally to reach the muscles and/or skin. They blamed the lack of coordination between the formation of the limb muscles and their innervation for appearance of a communicating branch.

Phylogeny : Studies of comparative anatomy have observed the existence of such connections in monkeys and in some apes; the connections may represent the primitive nerve supply of the anterior arm muscles⁶. Chauhan et al strongly recommend the consideration of the phylogeny and the development of the nerves of the upper limb for the interpretation of the nerve anomalies of the arm¹⁹. Considering the communication between the musculocutaneous and the median nerve as a remnant from the phylogenetic or comparative anatomical point of view and that the ontogeny recapitulates the phylogeny, they feel that the variations seen are the result of the developmental anomaly.

Clinical significance : The anatomical variation described here has practical implications, since injury to the median nerve in the axilla or arm would, in this case, have caused unexpected paresis or paralysis of the flexor musculature of the elbow and hypoesthesia of the lateral surface of the forearm, in addition to the classical signs that are already well known. Injury to the median nerve could occur in cases

of open or closed trauma to the arm, such as bullet and blade wounds or during surgeries on the axilla or arm. The median nerve and its roots are close to the axillary vein, which is used as the most cranial limit for axillary lymph node dissection, a procedure used in treating certain tumors, such as breast carcinoma and melanoma. If the dissection extends more cranially than normal, injury to the median nerve (or to its medial root)

may occur, with consequent dysfunction of the flexor musculature of the elbow if the anatomical variation described here is present. It would not be unlikely for such accidents to occur even with the most eminent surgeons, considering that the classical concept is that the median nerve does not give rise to branches in the arm²⁶. The clinical relevance of such variations might also be correlated to entrapment syndromes. Entrapment of musculocutaneous nerve is rare and has its origin either in physical activity²⁷ or in violent passive movements of arm and forearm²⁸. This knowledge of anastomosis between the musculocutaneous nerve and the median nerve may prove useful for clinicians in order to avoid an unnecessary Carpal tunnel release¹³. The presence of such type of variations are clinically important for orthopaedicians operating on surgical neck of the humerus and anaesthetist performing pain management therapies on the upper limb.

CONCLUSION

The presence of such type of variations are clinically important for surgeons, orthopaedicians and anaesthetist performing pain management therapies on the upper limb.

These variations are compared with the earlier data & it is concluded that variations in branching pattern of cords of brachial plexus are a rule rather than exception.

Competing Interests: The author declare that they have no competing interest.

Authors' contributions: SPS wrote the manuscript, performed the literature review, obtained the photograph for the study.

ACKNOWLEDGEMENT

Author is thankful to Dean Dr. Geeta Niyogi Madam for her support and encouragement. Author is also thankful to Mr. M. Murugan, Mr. Sanjay, Mr. Sankush, Mr. Pandu, Mr. Kishor and Mr. Raju for their help. Author also acknowledge the immense help received from the scholars whose articles are cited and included in references of this manuscript. The

author is also grateful to authors / editors / publishers of all those articles, journals and books from where the literature for this article has been reviewed and discussed.

REFERENCES

- Williams P.L., Bannister L.H., Berry M.M. et al. *Gray's Anatomy. In: Nervous System.* 38th ed. London Churchill Livingstone, 1999: 231-232:pp1270.
- Saddler T.W. *Langman's Medical Embryology. In: Muscular system.* 10th ed. Philadelphia Lippincott Williams and Wilkins, 2006: pp146-147.
- Edglseder WA JR, Goldman M. *Anatomic variations of the musculocutaneous nerve in the arm.* Amer J Orthop 1997; 26: 777-780.
- Uysal II, Seker M, Karabulut AK, Buyukmumcu M, Ziylan T. *Brachial plexus variation in human fetuses.* Neurosurgery 2003; 53: 676-84; discussion 684.
- Kerr, AT. *The brachial plexus of nerves in man, the variations in its formation and branches.* American Journal of Anatomy, 1918, vol. 23, n. 2, p. 285-395.
- Miller, RA. *Comparative studies upon the morphology and distribution of the brachial plexus.* American Journal of Anatomy, 1934, vol. 54, n. 1, pp 143-166.
- Bergman, RA., afifi, AK., Miyauchir, RA. *Illustrated encyclopedia of human anatomic variation.* In: NERVOUS system - plexuses. 1988.
- Hollinshead, WH. *Functional anatomy of the limbs and back.* 4th ed. Philadelphia: W.B. Saunders, 1976. pp 134-140.
- Harris, W. *The true form of the brachial plexus.* *Journal of Anatomy and Physiology*, 1904, vol. 38, p. 399-422. PMID:17232613. PMCID:1287350.
- Leffert, RD. *Anatomy of the brachial plexus.* New York: Churchill Livingstone, 1985. pp 384 .
- M Watanabe, M., Takatsuji, K., Sakamoto, N., Morit, Y., Ito, H. *Two cases of fusion of the musculocutaneous and median nerves.* *Kalbo gaki Zasshi*, 1985, vol. 60, 1-7.
- Kosugi, K. Mortia, T., Yamashita, H. *Branching pattern of the musculocutaneous nerve. 1. Cases possessing normal biceps brachii.* *Jikeikai Medical Journal*, 1986, vol. 33, 63-71.
- Venieratos, D., Anagnostopoulou, S. *Classification of communications between the musculocutaneous and median nerves.* *Clinical Anatomy*, 1998, vol. 11, 327-331.
- Choi, D., Rodriguez-Niedenfuhr, M., Vazquez, T., Parkin, I., Sanudo, JR. *Patterns of connections between the musculocutaneous and median nerves in the axilla and arm.* *Clinical Anatomy*, 2002, vol. 15, n. 1, 11-17.
- Loukas, M., Aqueelah, H. *Musculocutaneous and median nerve connections within, proximal and distal to the coracobrachialis muscle.* *Folia Morphologica (Warsz)*, 2008, vol. 64, n. 2, p. 101-108.
- Guerri- Guttenberg, RA., Ingolotti, M. *Classifying musculocutaneous nerve variations.* *Clinical Anatomy*, 2009, vol. 22, n. 6, p. 671-683.
- Maeda, S., Kawai, K., Koizumi, M., Ide, J., Tokiyoshi, A., Mizuta, H., Kodama, K. *Morphological study of the communication between the musculocutaneous and median nerves.* *Anatomical Science International*, 2009, vol. 84, n. 1-2, 34-40.
- Li Minor, JM. *A rare variant of median and musculocutaneous nerves in man.* *Archives Anatomy Histology Embryology*, 1992, vol. 73, 33-42.
- Chauhan, R., Roy, TS. *Communication between the median and musculocutaneous nerve: A case report.* *Journal of Anatomical Society of India*, 2002, vol. 51, n. 1, 72-75.
- Saritha, S. *Variations in the median and musculocutaneous nerves-A surgical prospective.* *Journal of Anatomical Society of India*, 2004, vol. 53, n. 1, 31-66.
- Uzun, A., Seelig, LL. *A variation in the formation of the median nerve: communicating branch between the musculocutaneous and median nerves in man.* *Folia Morphologica (Warsz)*, 2001, vol. 60 , n. 2, 99-101.
- Mohapatra, BB., Chinara, PK., Dutta, BK., Nayak, AK. *Variation in the formation and branching pattern of median nerve.* *Journal of Anatomical Society of India*, 2004, vol. 53, n. 1, p. 31-66.

23. Abhaya, A., Bhardwaj, R., Prakash, R. *Dual origin of musculocutaneous nerve*. Journal of Anatomical Society of India, 2003, vol. 52, n. 1, p. 94.
24. Iwata, H. *Studies on the development of the brachial plexus in Japanese embryo*. Republic Department Anatomy Mie Prefect University School of Medicine, 1960, vol. 13, p. 129-144.
25. Chiarapattanakom, P., Leechavengvons, S., Witoonchart, K., Uerpairojkit, C., Thuvasethakul, P. *Anatomy and internal topography of the musculocutaneous nerve: The nerves to the biceps and brachialis muscle*. Journal of Hand Surgery, 1998, vol. 23A, 250-255.
26. Fregnani, JHTG., Macéa, MIM., Pereira, CSB., Barros, MD., Macéa, JR. *Absence of the musculocutaneous nerve: a rare anatomical variation with possible clinical-surgical implications*. Sao Paulo Medical Journal, 2008, vol. 126, n. 5, 288-290.
27. Falsenthal, G., Mondell, DL., Reischer, MA., Mack, RH. *Forearm pain secondary to compression syndrome of the lateral cutaneous nerve of the forearm*. Archaeological Physical Medical Rehabilitation, 1984, vol. 65, 139-141.
28. Kim, SM., Goodrich, JA. *Isolated proximal musculocutaneous nerve palsy: Case report*. Archaeological Physical Medical Rehabilitation, 1984, vol. 65, 0735-736.

CORRESPONDENCE ADDRESS

Dr. Sharadkumar Pralhad Sawant,
25/2, Samrat Ashok Nagar Society,
Shell Colony Road, Chembur,
Mumbai – 400 071, Maharashtra, India.
9322061220, 022-22936867
dr.spsawant@gmail.com