

Original article

The cadaveric study of extensor carpi radialis longus muscle on the developmental basis.

*Sawant SP

Department of Anatomy, K. J. Somaiya Medical College, Somaiya Ayurvihar,
Eastern Express Highway, Sion, Mumbai-400 022.

*Corresponding author: drspsawant@gmail.com

Abstract:

Introduction: Our aim was to study the extensor carpi radialis longus muscle on the basis of development in 100 cadavers in India.

Materials & Methods: This study on extensor carpi radialis longus was performed on 100 (200 specimens of superior extremities) embalmed donated cadavers (90 males & 10 females) in the department of Anatomy of K.J.Somaiya Medical College, Sion, Mumbai, India.

Observations: Out of 200 specimens the variation was observed in 22 specimens. The extensor carpi radialis brevis was absent and the extensor carpi radialis longus was giving two tendons in the second compartment of extensor retinaculum before its insertion while passing deep to the abductor pollicis longus. The arterial pattern of upper limb were also observed. The variation was unilateral. The left upper limb was normal.

Conclusions: A lack of knowledge of such type of variations might complicate surgical repair.

Keywords: Extensor Carpi Radialis Longus, Physiotherapist, Electromyography.

Introduction: The extrinsic extensor muscles of the hand are located in the back of the forearm and have long tendons connecting them to bones in the hand, where they exert their action. Extrinsic denotes their location outside the hand. Extensor denotes their action which is to extend, or open flat, joints in the hand. They include the extensor carpi radialis longus, extensor carpi radialis brevis, extensor digitorum, extensor digiti minimi, extensor carpi ulnaris, abductor pollicis longus, extensor pollicis brevis, extensor pollicis longus, and extensor indicis (1). The extensor carpi radialis longus has the most proximal origin of the extrinsic hand extensors. It originates just distal to the brachioradialis at the lateral supracondylar ridge of

the humerus, the lateral intermuscular septum, and by a few fibers at the lateral epicondyle of the humerus. Distal to this, the extensor carpi radialis brevis, extensor digitorum, extensor digiti minimi, and extensor carpi ulnaris originate from the lateral epicondyle via the common extensor tendon. The extensor carpi radialis brevis has additional origins from the radial collateral ligament, the extensor carpi ulnaris from the dorsal border of the ulna (shared with the flexor carpi ulnaris and flexor digitorum profundus), and all four also originate from various fascia. The extensor carpi radialis longus and extensor carpi radialis brevis, (with the brachioradialis) form the lateral compartment. Their muscle fibers end at the upper third and the

mid forearm respectively, continuing as flat tendons along the lateral border of the radius, beneath the abductor pollicis longus and extensor pollicis brevis. They then pass beneath the extensor retinaculum and dorsal carpal ligament, where they lie in a groove on the back of the radius, immediately behind the styloid process, and continue into the second tendon compartment. The extensor carpi radialis longus inserts into the dorsal surface of the base of the second metacarpal bone on its radial side to extend and abduct the wrist. The extensor carpi radialis brevis inserts into the lateral dorsal surface of the base of the third metacarpal bone, with a few fibres inserting into the medial dorsal surface of the second metacarpal bone, also to extend and abduct the wrist (2). The extensor carpi ulnaris is supplied by the ulnar artery (3). The abductor pollicis longus, extensor pollicis brevis, extensor pollicis longus, extensor indicis extensor digitorum and extensor digiti minimi are supplied by the posterior interosseous artery, a branch of the ulnar artery. The extensor carpi radialis longus and extensor carpi radialis brevis receive blood from the radial artery (4). The extensor carpi radialis longus and extensor carpi radialis brevis muscles may split into two or three tendons of insertion to the second and third or even the fourth metacarpal. The two muscles may unite into a single belly with two tendons. The cross slips between the two muscles may occur. The extensor carpi radialis intermedius rarely arises as a distinct muscle from the humerus, but is not uncommon as an accessory slip from one or both muscles to the second or third or both metacarpals. The extensor carpi radialis accessorius is occasionally found arising from the humerus with or below the

extensor carpi radialis longus and inserted into the first metacarpal, the abductor pollicis brevis, the first dorsal interosseous, or elsewhere (5).

Materials & Methods: This study on extensor carpi radialis longus was performed on 100 (200 specimens of superior extremities) embalmed donated cadavers (90 males & 10 females) in the department of Anatomy of K.J.Somaiya Medical College, Sion, Mumbai, India.

Observations: Out of 200 specimens the variation was observed in 22 specimens i.e. 11%. The extensor carpi radialis brevis was absent and the extensor carpi radialis longus was giving two tendons in the second compartment of extensor retinaculum before its insertion while passing deep to the abductor pollicis longus. The one tendon of extensor carpi radialis longus inserted into the radial side of the dorsal surface of the base of the second metacarpal bone while the other tendon inserted into the lateral dorsal surface of the base of the third metacarpal bone, with a few fibres inserting into the medial dorsal surface of the second metacarpal bone. The variant extensor carpi radialis longus was supplied by the radial nerve. The finding was noted after thorough and meticulous dissection of the upper limbs of both sides. The arterial pattern of upper limb were also observed. The photographs of the variations were taken for proper documentation.

**International Journal of Healthcare
& Biomedical Research**

Now officially listed in

HIFA 2015

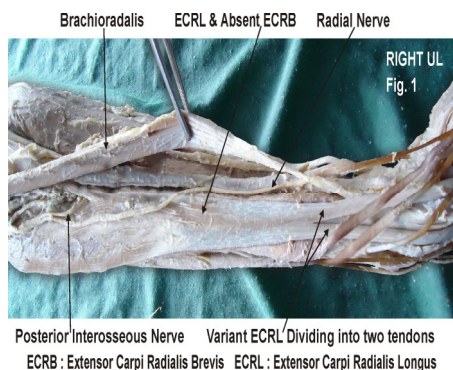


Figure 1 showing the photographic presentation of the variant extensor carpi radialis longus dividing into two tendons and the absent extensor carpi radialis brevis.

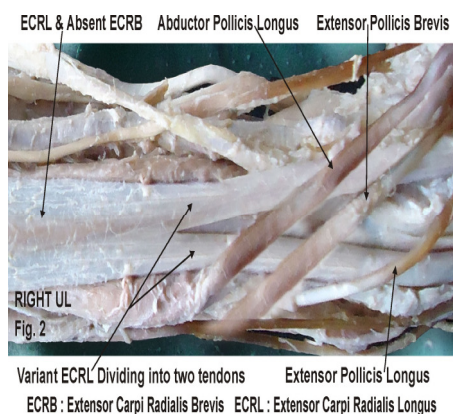


Figure 2 showing the photographic presentation of the variant two tendons of extensor carpi radialis longus passing deep to the abductor pollicis longus.

Discussion: The variations in the superficial group of extensors are rarely observed. Occasionally the aberrant muscle slips are seen among the superficial group of extensors of forearm (6). The accessory head of extensor carpi radialis longus travelled through a separate compartment of the extensor retinaculum and inserted in the middle of the first metacarpal bone was documented in the literature (7). In the present case extensor carpi radialis longus was passing as two tendons in the second compartment of extensor retinaculum

before its insertion. The supernumerary tendons of the extensor carpi radialis longus and the extensor carpi radialis brevis were found in literature whereas the presence of an accessory tendón making the unión between the tendons of the extensor carpi radialis longus and the extensor carpi radialis brevis was also registered (8). In tennis elbow the muscle involved is the extensor carpi radialis brevis (9). The non-inflammatory, chronic degenerative changes occurs in the origin of the extensor carpi radialis brevis muscle (10). The knowledge of the variant extensor carpi radialis longus muscle is important before injecting corticosteroid injections in the treatment of tennis elbow (11). The surgeons performing Z-shaped tenotomy on tennis elbow to lengthen the tendon of extensor carpi radialis brevis must be aware of this variation in order to avoid unwanted complications (12, 13). Recently, extensor carpi radialis brevis has also gained importance for use in ‘free functional muscle transfer’ i.e. transfer of a muscle with its motor nerve and vascular pedicle from one site of the body to another distant site, in order to restore the motor function (14). The knowledge of the variations is thus important while extensor carpi radialis brevis muscle is being harvested.

Ontogeny: Embryologically, the intrinsic muscles of the upper limb differentiate in situ, opposite the lower six cervical and upper two thoracic segments, from the limb bud mesenchyme of the lateral plate mesoderm. The formation of muscular elements in the limbs takes place shortly after the skeletal elements begin to take shape. At a certain stage of development, the muscle primordia within the different layers of the arm fuse to form a single muscle mass (15). Langman stated, however, that

some muscle primordia disappear through cell death despite the fact that cells within them have differentiated to the point of containing myofilaments (16). During fifth week of development, mesoderm invades the upper limb bud to further condense into ventral and dorsal muscle masses (17). The extensor carpi radialis longus and brevis muscles are derived from dorsal muscle mass of upper limb bud and it could be during this period that extensor carpi radialis brevis muscle may have not formed. The failure of muscle primordia to appear during embryologic development may account for the absence of the extensor carpi radialis brevis muscle reported in this study.

Phylogeny: In lower mammals the extensor carpi radialis longus and brevis are represented by one muscle (18). Anatomical variations always have underlying cause as developmental arrest in the different stages of gestation. Ontogeny repeats phylogeny hence, the pattern of muscular arrangement in this case can be said to be less evolved than the usual arrangement (19).

Clinical Significance: The variant extensor carpi radialis longus muscle is clinically important for surgeons dealing with entrapment or compressive

neuropathies, orthopaedicians operating on the fractures of the lower end of the humerus, anaesthetist performing pain management therapies on the upper limb and physiotherapist doing electromyography for evaluating and recording the electrical activity produced by skeletal muscles. A lack of knowledge of such type of variations might complicate surgical repair.

Conclusion: The variant extensor carpi radialis longus muscle with absent extensor carpi radialis brevis muscle is a rare occurrence. The knowledge of such variation is important for plastic surgeons performing 'free functional muscle transfer' and the extensor tendon repair.

Acknowledgement: Author is also thankful to Dean Dr. Geeta Niyogi Madam for her support and encouragement. Author is also thankful to Dr. Arif A. Faruqui and Mr. M. Murugan for their help. Author also acknowledge the immense help received from the scholars whose articles are cited and included in references of this manuscript. The author is also grateful to authors / editors / publishers of all those articles, journals and books from where the literature for this article has been reviewed and discussed.

References:

1. Williams PL, Bannister LH, Berry MM, Collins P, Dyson M, Dussek JE, et al. The Nervous system. In: Gray's Anatomy, 39th edn, Churchill Livingstone, New York; 2005; 879 - 880.
2. Hamilton WJ. Textbook of the Human Anatomy, 2nd edn, Macmillan Press Ltd., London 1976; 651.
3. Last RJ. Anatomy: Regional and Applied, 7th edn, Churchill Livingstone, Edinburgh 1984; 89.
4. Snell RS. Clinical Anatomy for Medical Students, 5th edn, Little Brown and Company, USA; 1995;434.
5. Tountas CP, Bergman RA. Anatomic variations of the upper extremity, Churchill Livingstone, New York; 1993; 11.

6. Hollinshead, W. H. Anatomy for Surgeons. The Back and Limbs. Vol 3. 2nd Ed. Harper and Row Publishers, New York, 1969. pp.428-41.
7. Claassen, H. & Wree, A. Multiple variations in the region of Mm. extensores carpi radialis longus and brevis. Ann. Anal, 754:489-91, 2002.
8. Caetano, F. M.; Albertoni, M. W.; Caetano, B. E. & Pérez, M. R. Anatomical study of insertions of the extensor carpi radialis longus and brevis. Int. J. Morphol, 22(4):245-51, 2004.
9. Garden RS. Tennis elbow. J Bone Joint Surg. 1961;43B(1):100-106.
10. Kalainov D, Cohen MS. Posterolateral rotatory instability of the elbow in association with lateral epicondylitis. A report of three cases. J Bone Joint Surg Am. 2005;87(5):1120-1125. [PubMed]
11. Edwards SG, Calandruccio JH. Autologous blood injections for refractory lateral epicondylitis. J Hand Surg [Am] 2003;28(2):272-278.
12. Boyer MI, Hastings H (1999). "Lateral tennis elbow: "Is there any science out there?"". Journal of Shoulder and Elbow Surgery 8 (5): 481-91. doi:10.1016/S1058-2746(99)90081-2. PMID 10543604.
13. Meyer NJ, Walter F, Haines B, Orton D, Daley RA. Modeled evidence of force reduction at the extensor carpi radialis brevis origin with the forearm support band. J Hand Surg [Am] 2003;28(2):279-287.
14. Binhammer P, Manktelow RT, Haswell T. Applications of the extensor carpi radialis brevis for facial reanimation. Journal of Reconstructive Microsurgery. 1994;10: 109.
15. Arey L. B. (1960). Developmental Anatomy, In: A Textbook and Laboratory Manual of Embryology, 6th Ed., Philidelphia, WB Saunders company, 434-435.
16. Langman J. (1969). Medical Embryology. 2nd Ed., Baltimore, Williams and Wilkins, 143-146.
17. Schoenwolf G. C., Bleyl S. B., Brauer P. R., Francis-West P. H. (2009). Larsen's Human Embryology. 4th Ed., Philadelphia, Churchill Livingstone, 241-242.
18. Bergman, R. A.; Thompson, S. A.; Afifi, A. K. & Saddeh, F. A. Copenidium of Human Anatomical Variation. Urban and Schwarzenburg, Baltimore, 1988. pp.138-9.
19. Anson, B. J. & McVay, C. B. Surgical Anatomy. 5th ed. W.B. Saunders Company, Philadelphia, 1971. pp.1012-7.

Date of submission: 07 March 2013

Date of provisional acceptance: 11 May 2013

Date of Final acceptance: 28 June 2013

Date of Publication: 03 July 2013

Source of support: Nil; Conflict of Interest: Nil