



A CASE REPORT ON BILATERAL THREE SEPARATE HEADS OF SOLEUS MUSCLE AND ITS CLINICAL IMPORTANCE

SAWANT S.P.

Department of Anatomy, K. J. Somaiya Medical College, Somaiya Ayurvihar, Eastern Express Highway, Sion, Mumbai- 400 022, MS, India.

*Corresponding Author: Email- drspsawant@gmail.com

Received: January 04, 2013; Accepted: January 24, 2014

Abstract- During routine dissection, of a 70 years old donated embalmed male cadaver in the Department of Anatomy, K.J. Somaiya Medical College, Sion, Mumbai, India, the variant soleus muscle on both the lower limbs was observed. The back of thigh, popliteal region and back of leg of both the lower limbs were dissected meticulously to observe the variations in the soleus muscle. The soleus muscle showed the three separate heads. The tibial head from soleal line present on the posterior surface of the tibia, the fibular head from the back of the head of the fibula and the intermediate head from the tendinous arch placed between the tibial and the fibular origins of the muscle. The three heads of soleus muscle along with the medial and the lateral heads of gastrocnemius formed the tendo calcaneus which got inserted into the middle part of the posterior surface of the calcaneus bone. The pattern of vessels in the lower limb were normal. The variation was bilateral. The photographs of both the variant soleus muscles were taken for proper documentation.

Conclusion: The existence of such variation of the soleus muscle should be kept in mind by the surgeons, the orthopaedicians, the radiologists and also by the physiotherapists. The three heads of soleus may prove significant and lead to confusion during surgical procedures. A lack of awareness such variations might complicate surgical repair.

Keywords- Soleus Muscle, Three Heads, Surgeons, Orthopaedicians, Radiologists, Physiotherapists.

Introduction

The soleus is a broad flat muscle situated immediately in front of the gastrocnemius. It arises by tendinous fibers from the back of the head of the fibula, and from the upper third of the posterior surface of the body of the bone; from the popliteal line, and the middle third of the medial border of the tibia; some fibers also arise from a tendinous arch placed between the tibial and fibular origins of the muscle, in front of which the popliteal vessels and tibial nerve run. The fibers end in an aponeurosis which covers the posterior surface of the muscle, and, gradually becoming thicker and narrower, joins with the tendon of the gastrocnemius, and forms with it the tendo calcaneus [1]. Accessory head to its lower and inner part usually ending in the tendocalcaneus, or the calcaneus, or the lacinate ligament [2]. The gastrocnemius and soleus together form a muscular mass which is occasionally described as the Triceps surae; its tendon of insertion is the tendo calcaneus (Tendo Achilles), the common tendon of the gastrocnemius and soleus, is the thickest and strongest in the body. It is about 15 cm. long, and begins near the middle of the leg, but receives fleshy fibers on its anterior surface, almost to its lower end. Gradually becoming contracted below, it is inserted into the middle part of the posterior surface of the calcaneus, a bursa being interposed between the tendon and the upper part of this surface. The tendon spreads out somewhat at its lower end, so that its narrowest part is about 4 cm. above its insertion. It is covered by the fascia and the integument, and is separated from the deep muscles and vessels by a considerable interval filled up with areolar and adipose tissue. Along its lateral side, but superficial to it, is the small saphenous vein [4].

Case Report

During routine dissection, of a 70 years old donated embalmed male cadaver in the Department of Anatomy, K.J. Somaiya Medical College, Sion, Mumbai, India, the variant soleus muscle on both the lower limbs was observed. The back of thigh, popliteal region and back of leg of both the lower limbs were dissected meticulously to observe the variations in the soleus muscle.

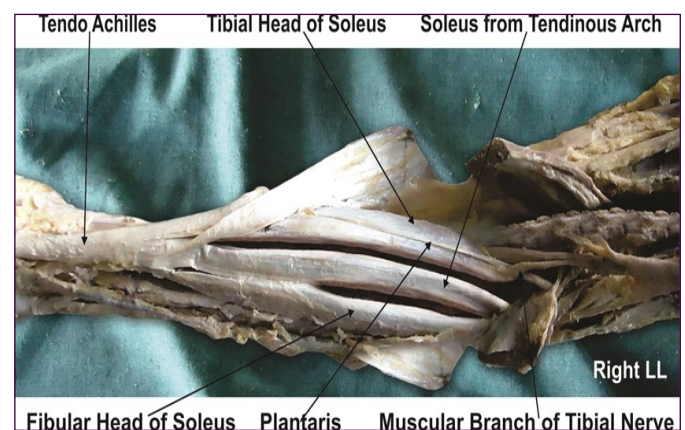


Fig. 1- Photographic presentation of the variant heads of right soleus muscle.

The soleus muscle showed the three separate heads. The tibial head from soleal line present on the posterior surface of the tibia, the fibular head from the back of the head of the fibula and the intermediate head from the tendinous arch placed between the tibial

and the fibular origins of the muscle. The three heads of soleus muscle along with the medial and the lateral heads of gastrocnemius formed the tendo calcaneus which got inserted into the middle part of the posterior surface of the calcaneus bone. The pattern of vessels in the lower limb were normal. The variation was bilateral. The photographs of both the variant soleus muscles were taken proper documentation.

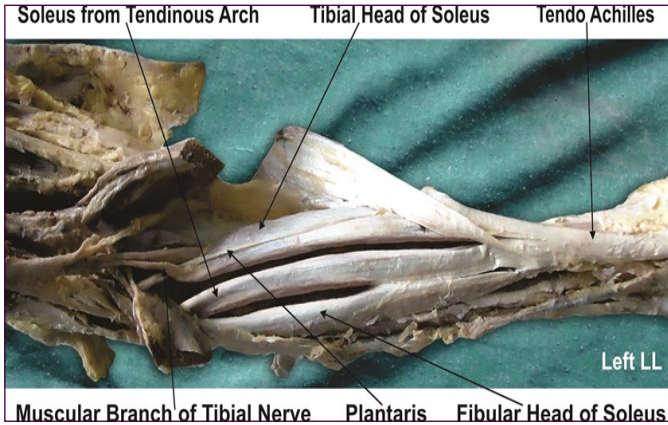


Fig. 2- Photographic presentation of the variant heads of left soleus muscle

Discussion

The accessory soleus muscle was first described in literature by Fuc Cruvelhier in 1834. The variant soleus muscle is present in 0.7 to 5.5% of the population [5]. It is a rare anatomical variation that can present as a soft tissue tumor in this region. A congenital muscle anomaly is more frequent in the upper limbs and is rarely seen in the lower limbs. During embryogenesis the soleus muscle separates into two parts, and this supernumerary muscle has its own blood supply and innervations [6,7]. This supernumerary muscle is located under the gastrocnemius muscle, in the posterior upper third of the fibula, in the oblique soleus line, between the fibular head and the posterior part of the tibia. From its origin, the accessory soleus muscle runs anteriorly and medially until it reaches the Achilles tendon. Five accessory soleus muscle types were described based on their insertion characteristics, including the Achilles tendon, the muscle insertion in the upper calcaneus region, the tendon insertion in the upper calcaneus, the muscle insertion in the medial calcaneus region, and finally the tendon insertion in the medial part of the calcaneus [5]. The accessory soleus muscle is usually observed during the second or third decade of life and more often in males at 2:1 ratio [8-10]. This is a rare condition and its general prevalence has not been established yet [11]. Statistical analysis shows that accessory soleus muscle is more frequently a unilateral finding [12]. But in the present case the variation in the soleus muscle was bilateral. The reports in the literature stated a 0.7 to 5.5% presence of accessory soleus muscle in human beings [13-16]. Some investigators reported a prevalence ranging from 1 to 6% in human beings [17]. Sometimes it is very difficult to identify the origin and insertion of the accessory soleus muscle on the MRI study [18-20]. The variations in the soleus muscle were common in males [21]. In the present case the variation was observed in male specimen. Thus our finding coincides with the literature.

Clinical Significance

The knowledge of any variation in the soleus muscle is clinically

important because the soleus muscle is called as peripheral heart. The presence of variant soleus muscle may appear as a soft tissue tumor on MRI study in this region.

Conclusion

The existence of such variation of the soleus muscle should be kept in mind by the surgeons, the orthopaedicians, the radiologists and also by the physiotherapists. The three heads of soleus may prove significant and lead to confusion during surgical procedures. A lack of awareness such variations might complicate surgical repair.

Competing Interests: The author declare that he has no competing interests.

Acknowledgement: Author is thankful to the Dean, Dr. Geeta Niyogi for her support and encouragement. I would like to thank Mr. M. Murugan, Mr. Sanjay, Mr. Pandu, Mr. Kishor, Mr. Nitin, Mr. San-kush and Mr. Raju for their help. Authors also acknowledge the immense help received from the scholars whose articles are cited and included in references of this manuscript. The author is also grateful to authors / editors / publishers of all those articles, journals and books from where the literature for this article has been reviewed and discussed.

References

- [1] Williams P.L., Bannister L.H., Berry M.M., Collins P., Dyson M., Dussek J.E., et al. (2005) *The Nervous system*, 39th ed., Churchill Livingstone, New York, 879-880.
- [2] Hamilton W.J. (1976) *Textbook of the Human Anatomy*, 2nd ed., Macmillan Press Ltd., London, 651.
- [3] Last R.J. (1984) *Anatomy: Regional and Applied*, 7th ed., Churchill Livingstone, Edinburgh, 89.
- [4] Snell R.S. (1995) *Clinical Anatomy for Medical Students*, 5th ed., Little Brown and Company, USA, 434.
- [5] Sookur P.A., Naraghi A.M., Bleakney R.R., Jalan R., Chan O., White L.M. (2008) *Radiographics*, 28(2), 481-99.
- [6] Moore K.L., Dalley A.F. (1999) *Clinically Oriented Anatomy*, 4th ed., Philadelphia: Lippincott Williams & Wilkins, 347-560.
- [7] Boyd J.D., Clark W.E., Hamilton W.J., Yoffey J.M., Zuckerman S., Appleton A.B. (1956) *Textbook of Human Anatomy*, Mcmillan & Co. Ltd. New York, 341-346.
- [8] Romanus B., Lindahl S., Sterner B. (1986) *J. Bone Joint Surg. Am.*, 68(5), 731-4.
- [9] Leswick D.A., Chow V., Stoneham G.W. (2003) *Can Assoc. Radiol. J.*, 54(5), 313-5.
- [10] Kouvalchouk J.F., Lecocq J., Parier J., Fischer M. (2006) *Rev. Chir Orthop. Reparatrice Appar. Mot.*, 91(3), 232-8.
- [11] Kurtoglu Z., Uluutku H. (2000) *Turk. J. Med. Sci.*, 30, 393-5.
- [12] Christodoulou A., Terzidis I., Natsis K., Gigis I., Pournaras J. (2004) *Br. J. Sport Med.*, 38(6), e 38.
- [13] Toit M.N., de Villiers R.V., Derman E.W. (2009) *S. Afr. Med. J.*, 99(11), 791-2.
- [14] Mir N.A., Kangoo K.A. (2002) *JK Sci.*, 4(1), 41-2.
- [15] Reis F.P., Aragão J.A., Fernandes A.C., Feitosa V.L., Fakhouri R., Nunes M.A. (2007) *Int. J. Morphol.*, 25(4), 881-4.
- [16] Singh S., Suri R.K., Mehta V., Loh H., Arora J., Rath G. (2009) *Int. J. Anat. Var.*, 2, 20-2.

- [17]Luck M.D., Gordon A.G., Beblea J.S., Dalinka M.K. (2008) *Skeletal Radiol.*, 37(12), 1129-33.
- [18]Featherstone T. (1995) *Br. J. Sports Med.*, 29(4), 277-8.
- [19]Doda N., Peh W.C., Chawla A. (2006) *Br. J. Radiol.*, 79(946), e129-32.
- [20]Caroll J.F. (2008) *Accessory muscles of the ankle.*
- [21]Meherzi M.H., Bouaziz M., Hamida F.B., Ghannouchi M., Quertatani M., Nouri H., et al. (2009) *Méd. Chir. Pied.*, 25(1), 17-20.