



Case Report

Variant Coracobrachialis Muscle - A Case Report

Sharadkumar Pralhad Sawant ^{**@}, Shaguphta T. Shaikh ^{*}, Rakhi M. More ^{*}

^{**} Associate Professor, ^{*} Assistant Professor

Department of Anatomy, K. J. Somaiya Medical College, Somaiya Ayurvihar, Sion, Mumbai-400 022

@Correspondence Email: dr.sharadsawant@yahoo.com

Received: 03/10/2012

Revised: 03/11/2012

Accepted: 07/11/2012

ABSTRACT

Case Report: During routine dissection for Ist MBBS students on 65 years donated embalmed male cadaver in the Department of Anatomy, K.J.Somaiya Medical College, we observed an accessory head of the coracobrachialis muscle in the left arm. It extended downwards and medially from the middle part of the medial border of the humerus in front of the median nerve and brachial artery and finally was inserted on the anteromedial aspect of the medial epicondyle of the humerus. The length of the ligament was 15 cm and the diameter was 0.2 cm. The photographs were taken for proper documentation. The existence of accessory head of the coracobrachialis muscle should be kept in mind by surgeons operating on patients with high median nerve palsy and brachial artery compression and radiologists while doing scans of the arm.

Key words: Coracobrachialis Muscle, Median Nerve, Brachial Artery, Medial Epicondyle of Humerus, Orthopaedic Surgeons, Physiotherapists, Radiologists.

INTRODUCTION

The coracobrachialis muscle shows several interesting morphological and anatomical characteristics. It is the counterpart in the arm of the adductors (longus, brevis, magnus) of the thigh. It arises from the apex of the coracoid process, where it is fused with the medial side of the short head of biceps. The tendon is continued into a muscular belly of varying development which is inserted into the medial border of the humerus. The lower extent of the insertion is marked by the nutrient foramen of the humerus, for the nutrient branch of the brachial artery runs along the lower border of the muscle. The

upward extent of the insertion cannot be seen on most bones, the muscle usually leaving no impression. The musculocutaneous nerve passes through the muscle and supplies it. Compared to the morphological interest of this muscle its action is negligible. It is a weak adductor of the shoulder joint, the main adductors of which are pectoralis major and latissimus dorsi. ^(1,2) In some animals the coracobrachialis muscle has three heads, ⁽³⁾ in man two have fused, trapping the nerve between them, and the third part has become suppressed. The occasional supratrochlear spur (on the anteromedial aspect of the lower humerus) may be continuous with a

ligament (of Struthers) which passes to the medial epicondyle and represents the remains of the third head. (4) The median nerve or brachial artery or both may run beneath it and be subjected to compression.

CASE REPORT

During routine dissection for Ist MBBS students on a 65 years donated embalmed male cadaver in the Department of Anatomy, K.J.Somaiya Medical College, we observed an accessory head of the coracobrachialis muscle on the left side. It extended downwards and medially from the middle part of the medial border of the humerus in front of the median nerve and brachial artery and finally was inserted on the anteromedial aspect of the medial epicondyle of the humerus. The length of the ligament was 15 cm and the diameter was 0.2 cm. The photographs were taken for proper documentation.

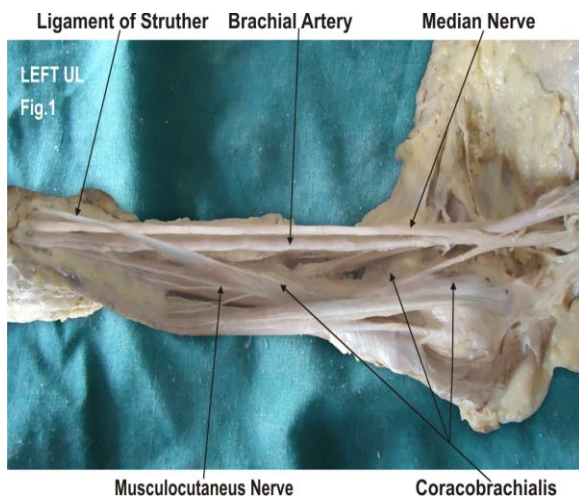


Fig. 1: Photographic presentation of an accessory head of the coracobrachialis muscle crossing the median nerve and the brachial artery and finally was inserted on the anteromedial aspect of the medial epicondyle of the humerus in left upper limb.

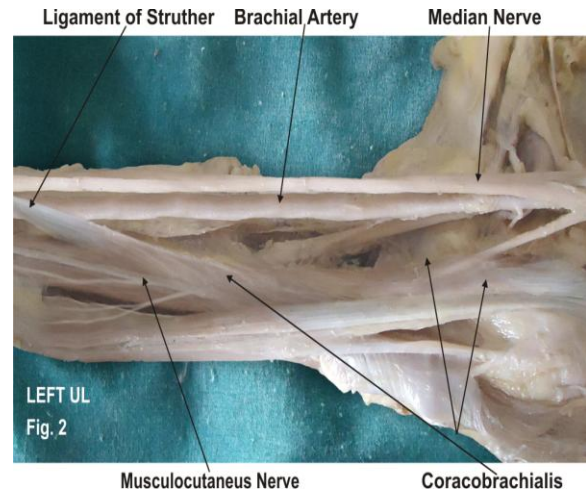


Fig. 2: Photographic presentation of the origin of the accessory head of the coracobrachialis muscle from the middle part of the medial border of the humerus and the nerve supply from the musculocutaneous nerve.

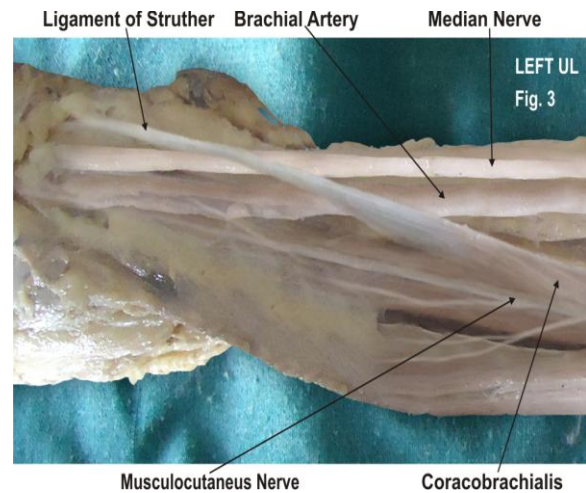


Fig. 3: Photographic presentation of Ligament of Struther' attached to the anteromedial aspect of the medial epicondyle of the humerus.

DISCUSSION

The accessory head of coracobrachialis muscle may be attached to the lesser tubercle, medial epicondyle or medial intermuscular septum. (2) The clinical implication of the accessory head of coracobrachialis is that it has the potential to cause median nerve entrapment and brachial artery compression. Various studies have described the compression of median nerve and brachial artery with anomalous muscles.

(5, 6, 7, 8) According to some authors the accessory head of the coracobrachialis continues with the medial head of triceps to be inserted on the olecranon process of ulna. This additional belly extending towards the ulna through the triceps brachii can be called “coracoularis”. The “coracoularis” muscle can help in the extension of the elbow and pronation of the forearm. (9) In the present case the accessory head of coracobrachialis muscle arises from superficial fibres of coracobrachialis muscle having 3 cm muscle belly and 15 cm tendinous band. It extended downwards and medially in front of the median nerve and brachial artery and finally got inserted on the anteromedial aspect of the medial epicondyle of the humerus. The accessory head of the coracobrachialis muscle reported in this case may be explained on the basis of the embryogenesis of the muscles of the arm. An important finding in our case is a passage for the brachial artery and median nerve formed by the tendinous band of the accessory head of the coracobrachialis muscle. This tendinous band forming the tunnel is called as Ligament of Struther’s. Other openings, however, have been described for the passage of the median nerve and brachial artery, the most common being the tunnel formed beneath the ligament of Struthers. (4) The neurovascular bundle of the arm may undergo active or passive compression by ligament of Struthers leading to neurovascular disorders. It may lead to wasting or ischaemic contraction of flexors of the forearm. This variation is important during the active use of coracobrachialis as a transposition flap in deformities of infraclavicular and axillary areas and in postmastectomy reconstruction, (11) during surgical intervention of the anterior compartment of the arm, such as trauma, tumour, neurovascular disease; while using conjoint tendon for stabilisation treatment for recurrent dislocation and subluxation of

the shoulder joint, (12) while using coracobrachialis as a vascularised muscle for transfer in the treatment of longstanding facial paralysis (9) during evaluation of computed tomography (CT) and magnetic resonance imaging (MRI) . As the coracobrachialis is also a guide to the axillary artery during surgery and anaesthesia, knowledge of this abnormal insertion may prove significant. Accessory muscles in the arm and forearm may lead to confusion during surgical procedures or cause compression of neurovascular structures. To avoid clinical complications, during radiodiagnostic procedures e.g. CT, MRI or surgical approach of these regions, awareness of such variations must be borne in mind. These types of variations are interesting not only to anatomists, but also to orthopaedic surgeons, physiotherapists and radiologists.

Developmental Basis:

During development, the limb bud mesenchyme of the lateral plate differentiates into intrinsic muscles of the upper limb. A single muscle mass is formed by fusion of the muscle primordia within the different layers of the arm at certain stages of development; thereafter, some muscle primordia disappears through cell death. The morphological variations of the coracobrachialis muscle may be due to failure of muscle primordia to disappear during embryological development. (10)

CONCLUSION

The existence of such variation of the coracobrachialis muscle should be kept in mind by the surgeons operating on patients with high median nerve palsy and brachial artery compression, by the orthopaedicians dealing with fracture of the humerus, the radiologists while doing radiodiagnostic procedures e.g. CT scan, MRI of the arm and angiographic studies

and also by the physiotherapists. These accessory fibres of coracobrachialis may be used as a transposition flap in deformities of infraclavicular and axillary areas and in postmastectomy reconstruction. The accessory fibres of coracobrachialis may prove significant and lead to confusion during surgical procedures or cause compression of neurovascular structures.

Competing Interests:

The authors declare that they have no competing interest.

Authors' contributions:

SPS wrote the case report, performed the literature review & obtained the photograph for the study. RMM performed the literature search and assisted with writing the paper. STS conceived the study and helped to draft the manuscript. All authors have read and approved the final version manuscript.

ACKNOWLEDGEMENT

All the authors wish to convey thanks to Dr. Arif A. Faruqui for his valuable support. We are also thankful to Mr. M. Murugan. Authors also acknowledge the immense help received from the scholars whose articles are cited and included in references of this manuscript. The authors are also grateful to authors / editors / publishers of all those articles, journals and books from where the literature for this article has been reviewed and discussed.

REFERENCES

1. McMinn RMH., editor Last's anatomy: regional and applied. 8. Edinburgh: Churchill Livingstone; 1990. p. 79.
2. Williams PL, Warwick R, Dyson M, Bannister LH., editors Gray's anatomy. 39.

Edinburgh-London: Churchill Livingstone; 2005. pp. 852.

3. Parsons FG. The muscles of mammals with special relation to human myology. J Anat 1898; 32:721-52.
4. Struthers J. On some points in the abnormal anatomy of the arm. Br Foreign Med Chir Rev 1854; 14:224-36.
5. Dharap AS. An anomalous muscle in the distal half of the arm. Surg Radiol Anat. 1994; 16:97-99. doi: 10.1007/BF01627930.
6. El-Naggar M. A study on the morphology of the coracobrachialis muscle and its relationship with the musculocutaneous nerve. Folia Morphol (Warsz) 2001; 60:217-224.
7. El-Naggar M, Al-Saggaf S. Variant of the Coracobrachialis Muscle With a Tunnel for the Median Nerve and Brachial Artery. Clin Anat. 2004; 17:139-143. doi: 10.1002/ca.10213.
8. Vollala VR, Nagabhooshana S, Bhat SM, Potu BK, Gorantla VR. Multiple accessory structures in the upper limb of a single cadaver. Singapore Med J. 2008;49:e254-e258.
9. Wood J. On human muscular variations and their relation to comparative anatomy. J Anat Physiol. 1867; 1:44-59.
10. Lewis WH. The development of the muscular system. In: Keibel F, Mall FP, ed. Manual of Embryology. Vol 2. Philadelphia: JB Lippincott, 1910: 455-522.
11. Kopuz C, Icten N, Yildirim M. A rare accessory coracobrachialis muscle: a review of the literature. Surg Radiol Anat. 2003;24:406-10.
12. Jiang LS, Cui YM, Zhou ZD, Dai LY. Stabilizing effect of the transferred conjoined tendon on shoulder stability. Knee Surg Sports Traumatol Arthrosc 2007; 15:800-5.

How to cite this article: Sawant SP, Shaikh ST, More RM. Variant coracobrachialis muscle - a case report. Int J Health Sci Res. 2012;2(8):107-110.
