	International Journal of	<h1>Innovative Drug Discovery</h1>	e ISSN 2249 - 7609 Print ISSN 2249 - 7617
<a href="http://www.ijidd.com">www.ijidd.com</a>			

## CADAVERIC STUDY OF FLEXOR CARPI ULNARIS MUSCLE

**Sharadkumar Pralhad Sawant\***

Professor and Head, Department of Anatomy, K.J.Somaiya Medical College, Somaiya Ayurvihar, Eastern Express Highway, Sion, Mumbai-400 022, Maharashtra, India.

### ABSTRACT

Aim to study the variant Flexor Carpi Ulnaris muscle. 100 upper limbs of 50 donated embalmed cadavers (45 males & 5 females) of age group ranging from 70 to 80 years were dissected in the department of Anatomy at K. J. Somaiya Medical College, Sion, Mumbai, INDIA. The variant Flexor Carpi Ulnaris muscle was observed in 2 specimens. The neurovascular pattern was also observed. The photographs of the variation of the Flexor Carpi Ulnaris muscle were taken for proper documentation. The separate humeral and ulnar heads of flexor carpi ulnaris muscle were observed in 2 specimens. The ulnar head of flexor carpi ulnaris muscle was more bulky. It separated ulnar nerve and artery. The humeral and ulnar heads were separated from each other by ulnar nerve. These two heads fused with each other just before their insertion, where the ulnar artery came in contact with ulnar nerve. The further course and distribution of ulnar artery and ulnar nerve were normal. The knowledge of such unusual ulnar head separating ulnar artery and ulnar nerve may be clinically important for plastic surgeons doing flap surgeries and for the surgeon dealing with cubital tunnel syndrome.

**KEY WORDS:** Flexor carpi ulnaris, Ulnar artery, Ulnar Head, Ulnar nerve, Humeral head, plastic surgeons, cubital tunnel syndrome.

### INTRODUCTION

Flexor carpi ulnaris muscle is the medial most muscle of the superficial flexor group. It arises by two heads, humeral and ulnar, connected by a tendinous arch. The small humeral head arises from the medial epicondyle via the common flexor tendon. The ulnar head has an extensive origin from the medial margin of the olecranon process and proximal two-thirds of the posterior border of the ulna, an aponeurosis (along with flexor digitorum profundus and extensor carpi ulnaris) and from the intermuscular septum between it and flexor digitorum superficialis. A thick tendon forms along its anterolateral border in its distal half. The tendon is attached to the pisiform, and thence prolonged to the hamate and the fifth metacarpal bone by pisohamate and pisometacarpal ligaments (pisiform is the sesamoid bone developing in the tendon of flexor carpi ulnaris). Acting with the flexor carpi radialis, it flexes the wrist and acting with the extensor carpi ulnaris it adducts the wrist [1]. Flexor carpi ulnaris muscle is innervated by the ulnar nerve (C7, C8 and T1). The line between the medial humeral epicondyle and the pisiform,

along the anterior palmar margin of the muscle, is used as a reference point for locating the ulnar neurovascular bundle. The ulnar artery reaches the muscle in its middle third, whereas the ulnar nerve is covered by the muscle throughout its entire course running under the tendon in the wrist region. The ulnar artery, the larger of the two terminal branches of the brachial, begins a little below the bend of the elbow, and, passing obliquely downward, reaches the ulnar side of the forearm at a point about midway between the elbow and the wrist. It then runs along the ulnar border to the wrist, crosses the transverse carpal ligament on the radial side of the pisiform bone, and immediately beyond this bone divides into two branches, which enter into the formation of the superficial and deep palmar arches. The ulnar nerve, after descending in the forearm between the flexor digitorum profundus and flexor carpi ulnaris muscles, pierces the deep fascia and enters the wrist through the Guyon's canal. In the distal part of the canal, the ulnar nerve divides into a superficial sensory branch and a deep motor branch, which supplies the hypothenar muscles and then

passes across the palm, distributing to other intrinsic hand muscles.

### MATERIALS AND METHODS

100 upper limbs of 50 donated embalmed cadavers (45 males & 5 females) of age group ranging from 70 to 80 years were dissected in the department of Anatomy at K. J. Somaiya Medical College, Sion, Mumbai, INDIA. The variant Flexor Carpi Ulnaris muscle was observed in 2 specimens. The neurovascular pattern in the arm was also observed. The photographs of the variation of the Flexor Carpi Ulnaris muscle were taken for proper documentation.

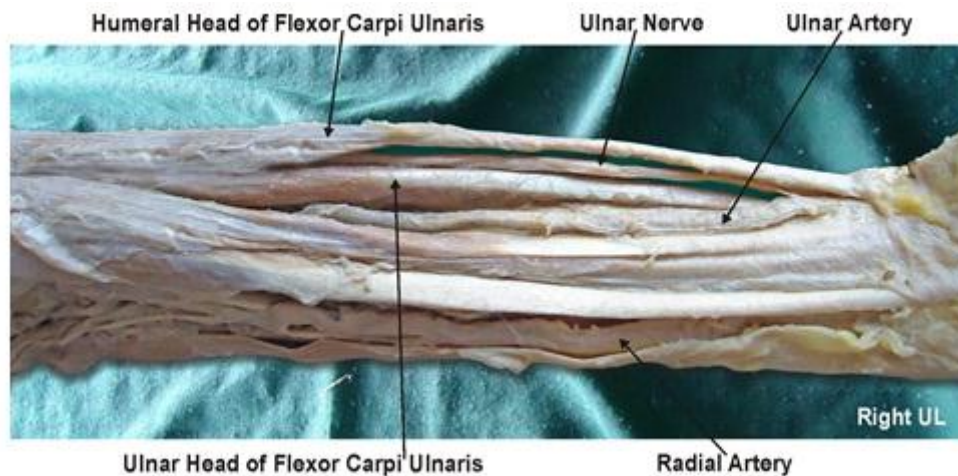
### OBSERVATIONS

The separate humeral and ulnar heads of flexor carpi ulnaris muscle were observed in 2 specimens. The ulnar head of flexor carpi ulnaris muscle was more bulky. It separated ulnar nerve and artery.

The humeral and ulnar heads were separated from each other by ulnar nerve. These two heads fused with each other just before their insertion, where the ulnar artery came in contact with ulnar nerve.

The further course and distribution of ulnar artery and ulnar nerve were normal.

**Figure 1. Showing photographic presentation of the ulnar head of flexor carpi ulnaris muscle separating ulnar nerve and artery.**



### DISCUSSION

The variations of flexor carpi ulnaris muscle have been reported previously by many authors. These variations include: (i) an additional slip of flexor carpi ulnaris [2], (ii) variations in musculotendinous junction of the flexor carpi ulnaris muscle [3], (iii) variant flexor carpi ulnaris causing ulnar nerve compression [4]. In the present case the two heads of flexor carpi ulnaris muscle remain separate. The ulnar head separated ulnar artery and nerve. The ulnar nerve runs in between the two heads of the flexor carpi ulnaris muscle in the forearm. Such variation is not yet reported in literature. The flexor carpi ulnaris muscle acts as an anatomical guideline for finding the neurovascular bundle (ulnar nerve, ulnar artery and accompanying venae comitantes), it can be easily palpated in its distal course if the wrist is flexed and adducted. The present variation need to be taken into account when interpreting ultrasound and MR images, as well as during dissection of the ulnar neurovascular bundle when using flexor carpi ulnaris as a guideline. The flexor carpi ulnaris is a useful local muscle flap in the forearm and elbow. It is, however, an important palmar flexor and ulnar deviator of the wrist, and functional loss may arise from the use of this

muscle in its entirety. The flexor carpi ulnaris is made up of two distinct neuromuscular compartments.

This arrangement allows for splitting of the muscle and the potential use of the larger ulnar compartment as a local muscle flap while maintaining the humeral compartment as an ulnar deviator and palmar flexor of the wrist [5]. After multiple efforts to heal an infected non union of the proximal ulna, a flexor carpi ulnaris muscle pedicle flap was used to improve blood supply and soft tissue coverage at the non union site. It was observed that it promoted bone healing and restoration of useful elbow function [6]. The course and distribution of ulnar nerve and ulnar artery can assist the surgeon in the diagnosis and effective management of the more common pain syndromes conditions associated with the ulnar aspect of the hand [7]. As the two heads of flexor carpi ulnaris muscles were separate the tendinous arch between them was absent. The possibility of entrapment of ulnar nerve in cubital tunnel in such cases is rare.

### CONCLUSION

The knowledge of such unusual variations of flexor carpi ulnaris is a must before any operative

procedures of the forearm and hand. The ulnar head of flexor carpi ulnaris separating ulnar artery and ulnar nerve seen in present study is important for Anatomists. It may be clinically important for plastic surgeons doing flap surgeries and for the surgeons dealing with cubital tunnel syndrome. Orthopaedicians have used this muscle flap for treating non union of proximal ulna and hence knowledge of this variable head is important.

#### ACKNOWLEDGEMENT

The authors wish to convey his sincere thanks to our Dean Dr. Geeta Niyogi Madam for her valuable help, support and inspiration. I am also thankful to Mr. M. Murugan.

#### REFERENCES

1. Susan, Standring, Gray's Anatomy, 40<sup>th</sup> Edition Elsevier Churchill Livingstone, 2008, 877.
2. Bergman RA, Thomson SA, Afifi AK & Saadesh FA. Compendium of human anatomic variations. Urban & Schwarzenberg, Baltimore – Munich, 13, 1988.
3. Grechenig W, Clement H, Egner S, Tesch NP, Weiglein A & Peicha G. Musculo-tendinous junction of the flexor carpi ulnaris muscle. An anatomical study. *Surg Radiol Anat*, 22, 2000, 255-60.
4. Al-Qattan MM & Duerksen F. A variant of flexor carpi ulnaris causing ulnar nerve compression. *J Anat*, 180, 1992, 189-190.
5. Lingaraj K, Lim AY, Puhaindran ME & Kumar PV. The split flexor carpi ulnaris as a local muscle flap. *Clin Orthop Relat Res*, 455, 2007, 262-6.
6. Meals RA. The use of a flexor carpi ulnaris muscle flap in the treatment of an infected nonunion of the proximal ulna. A case report. *Clin Orthop Relat Res*, 240, 1989, 168- 72.
7. Kleinert H and Hayes J. The ulnar tunnel syndrome. *Plastic Reconstructive Surgery*, 47, 1971, 21-24.

Author also acknowledges the immense help received from the scholars whose articles are cited and included in references of this manuscript. The author is also grateful to authors / editors / publishers of all those articles, journals and books from where the literature for this article has been reviewed and discussed.

#### Competing Interests

The author declares that he has no competing interest.

#### Authors' contributions

SPS draft the manuscript, performed the literature review & obtained the photograph for the study.