



STUDY OF VARIANT FLEXOR CARPI ULNARIS MUSCLE AND ASSOCIATED NEUROVASCULAR VARIATIONS

Sharadkumar Pralhad Sawant*

Professor and Head, Department of Anatomy, K.J.Somaiya Medical College, Somaiya Ayurvihar, Eastern Express Highway, Sion, Mumbai - 400 022, Maharashtra, India.

ABSTRACT

Aim to study the variant Flexor Carpi Ulnaris muscle and associated neurovascular variations. 100 upper limbs of 50 donated embalmed cadavers (45 males & 5 females) of age group ranging from 70 to 80 years were dissected in the department of Anatomy at K. J. Somaiya Medical College, Sion, Mumbai, INDIA. The accessory slip of flexor carpi ulnaris muscle was observed in 2 specimens. The associated neurovascular variations were also observed in 2 specimens. The photographs of the variations were taken for proper documentation. The accessory slip of flexor carpi ulnaris muscle was observed in 2 specimens. The accessory slip of flexor carpi ulnaris originated from lower part of its tendon and got inserted into the palmar aponeurosis and the tendon of palmaris longus muscle. The total length of flexor carpi ulnaris muscle was 26 cm, with a muscular belly of 22 cm and 3.5 cm of width and 0.5 cm of thickness. In one specimen the total length of an accessory slip of flexor carpi ulnaris muscle is 2 cm, and thickness 0.5 cm and in another specimen the total length of an accessory slip of flexor carpi ulnaris muscle is 4 cm, and thickness 0.5 cm. The accessory muscle is located between the tendon of flexor carpi ulnaris muscle and palmaris longus muscle. The associated neurovascular variations were also observed in 2 specimens. The accessory slip of flexor carpi ulnaris muscle was associated with incomplete superficial palmar arch in one specimen and the accessory slip of flexor carpi ulnaris muscle was associated with high division of ulnar nerve in another specimen. The knowledge of such accessory slip of flexor carpi ulnaris muscle and associated neurovascular variations may be clinically important for plastic surgeons doing flap surgeries and for the surgeon dealing with cubital tunnel syndrome.

Keywords: Flexor carpi ulnaris muscle, Accessory muscle, Forearm, Cadaver.

INTRODUCTION

The flexor carpi ulnaris muscle is the most medial of the muscles superficial flexors. It can make the flexing and adduction of the hand simultaneously. Her innervation is made completely by the ulnar nerve [1]. According to Williams, Warwick, Dyson et al [2], it possesses heads ulnar and ulnar united by an arch tendon, below these structures it travels the ulnar nerve and the posterior branch of the artery recurrent ulnar. The small head ulnar originates from the medial epicondyle through a common tendon; the head ulnar is an extensive fixation of the medial margin of the olecranon and two thirds proximalis of the posterior border of the ulna through a common aponeurosis. In this report, we described a rare anatomical variation

involving this important muscle of the anterior area of the forearm and discuss the clinical implications of this anatomical variation.

MATERIALS AND METHODS

100 upper limbs of 50 donated embalmed cadavers (45 males & 5 females) of age group ranging from 70 to 80 years were dissected in the department of Anatomy at K. J. Somaiya Medical College, Sion, Mumbai, INDIA. The accessory slip of flexor carpi ulnaris muscle was observed in 2 specimens. The associated neurovascular variations were also observed in 2 specimens. The photographs of the variations were taken for proper documentation.

OBSERVATIONS

The accessory slip of flexor carpi ulnaris muscle was observed in 2 specimens. The accessory slip of flexor carpi ulnaris originated from lower part of it's tendon and got inserted into the palmar aponeurosis and the tendon of palmaris longus muscle. The total length of flexor carpi ulnaris muscle was 26 cm, with a muscular belly of 22 cm and 3.5 cm of width and 0.5 cm of thickness. In one specimen the total length of an accessory slip of flexor carpi ulnaris muscle is 2 cm, and thickness 0.5 cm and in

another specimen the total length of an accessory slip of flexor carpi ulnaris muscle is 4 cm, and thickness 0.5 cm. The accessory muscle is located between the tendon of flexor carpi ulnaris muscle and palmaris longus muscle. The associated neurovascular variations were also observed in 2 specimens. The accessory slip of flexor carpi ulnaris muscle was associated with incomplete superficial palmar arch in one specimen and the accessory slip of flexor carpi ulnaris muscle was associated with high division of ulnar nerve in another specimen.

Figure 1. Showing photographic presentation of the accessory slip of flexor carpi ulnaris muscle. The total length of an accessory slip of flexor carpi ulnaris muscle is 4 cm, and thickness 0.5 cm. The accessory muscle is located between the tendon of flexor carpi ulnaris muscle and palmaris longus muscle.

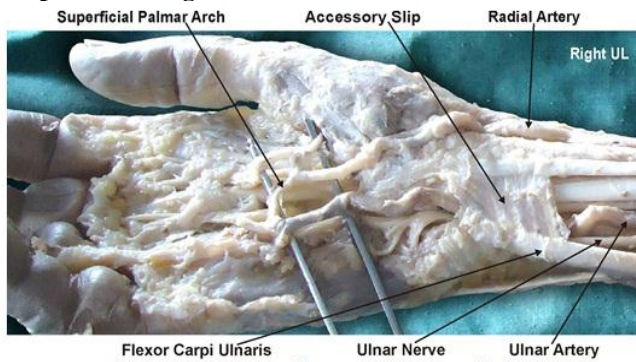


Figure 2. Showing photographic presentation of the accessory slip of flexor carpi ulnaris muscle associated with incomplete superficial palmar arch.

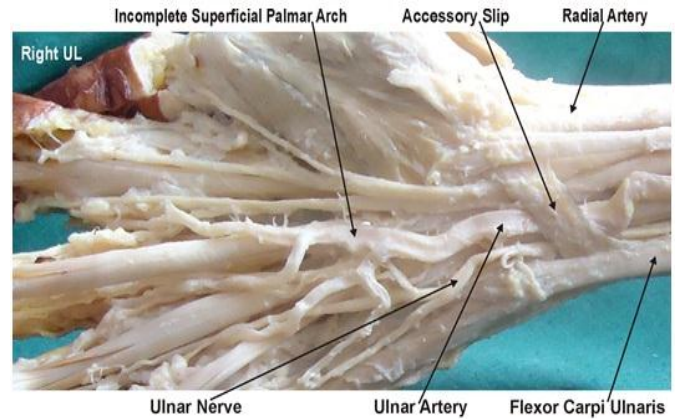
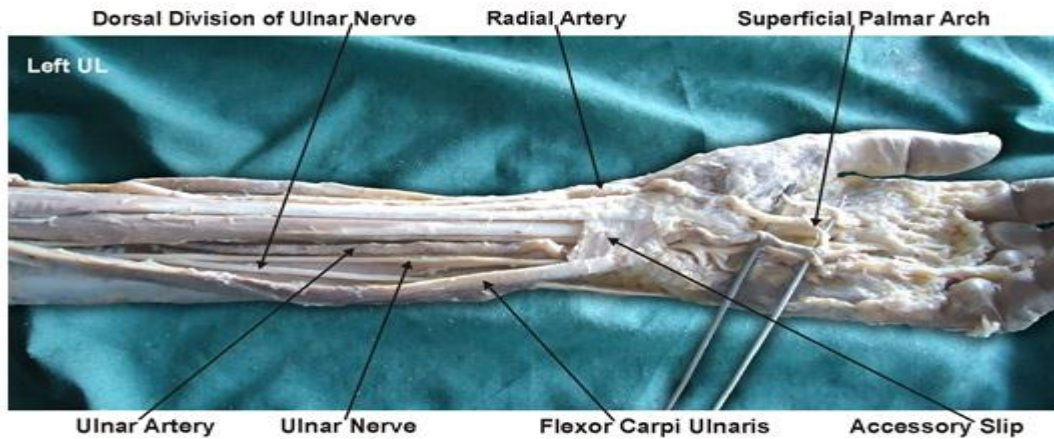


Figure 3. Showing photographic presentation of the accessory slip of flexor carpi ulnaris muscle associated with high division of ulnar nerve.



DISCUSSION

The ulnar tunnel is located at the proximal part of the hand radial to the pisiform bone and to the proximal part of the carpal tunnel. Inside it lies the ulnar nerve and artery. Compression of the ulnar nerve in this tunnel is often reported. Cysts, occupational trauma, fractures and muscle variations are among the main causes [3,4]. As mentioned by Khaledpour and Schindelmeiser [5] the knowledge of such variations supplements the body of

information on the muscles of the antebrachial and carpal regions may be important for hand surgeons. The importance of continuing to record and discuss anatomical anomalies was addressed recently by Hicks and Newell [6] in the light of technical advances and interventional methods of diagnosis and treatment. According to Soldado-Carrera, Vilar-Coromina and Rodriguez-Baeza [7], accessory fasciculi of the hypothenar muscles have been

involved in vascular and nerve compressions. Olave, Del Sol, Gabrielli et al [8] comments that the flexor retinaculum lays dorsal to the contents of the ulnar tunnel and medially there were some anomalous muscle fibres extending between the pisiform bone and the retinaculum. Natsis, Levva, Totlis et al [9] reports that after dissection of the left forearm of a 73-year-old female cadaver was found a reversed palmaris longus muscle. This means that the palmaris longus muscle was tendinous in its upper part and muscular in its lower part. Additionally, the muscle belly was triple. Nakahashi and Izumi [10] cited a rare case of a short radiocarpal flexor found on the right forearm of a 47-year-old Japanese male corpse. The muscle arose from the anterior surface of the radius, ran distally in the deep layer of the flexor region to enter deeply into the carpal tunnel, and then interconnected with the subtendon of the extensor carpi radialis brevis at the gap between the bases of the second and third metacarpal bones. Sakuma, Kato, Honda et al [11] tell they found a case of the absence of the tendon to the fourth toe of the extensor digitorum longus muscle of the right leg in the body of a 73-year-old Japanese woman during the course of dissection. It is already evident that the muscles vary plenty as for his insert; they can be absentees, and many accessory muscles were described already [12] especially to the musculature of the hand [13-16] and forearm [17,18]. The variation of the accessory muscle of the flexor carpi ulnaris muscle described in our study differs relatively from those reported in our literature revision. However, the specific anatomic variations described may be anticipated and more readily recognized by hand

surgeons during such open surgery, thus increasing the efficacy and safety of this common procedure.

CONCLUSION

The knowledge of such unusual variations of flexor carpi ulnaris and associated neurovascular variations is a must before any operative procedures of the hand. This knowledge of variant slip of flexor carpi ulnaris muscle is important for Anatomists. It may be clinically important for plastic surgeons doing flap surgeries and for the surgeons dealing with ulnar tunnel syndrome.

Competing Interests

The author declares that he has no competing interest.

Authors' contributions

SPS draft the manuscript, performed the literature review & obtained the photograph for the study.

ACKNOWLEDGEMENT

The authors wish to convey his sincere thanks to our Dean Dr. Geeta Niyogi Madam for her valuable help, support and inspiration. I am also thankful to Mr. M. Murugan. Author also acknowledges the immense help received from the scholars whose articles are cited and included in references of this manuscript. The author is also grateful to authors / editors / publishers of all those articles, journals and books from where the literature for this article has been reviewed and discussed.

REFERENCES

1. Moore KL and Dalley AF. *Anatomia Orientada para a Clínica*. 4 ed. Rio de Janeiro: Guanabara Koogan, 2007.
2. Williams PL, Warwick R, Dyson M and Bannister LH. *Gray Anatomia*. Edinburgh: Churchill Livingstone, 1995.
3. Kleinert H and Hayes J. The ulnar tunnel syndrome. *Plastic Reconstructive Surgery*, 47, 1971, 21-24.
4. Schjelderup H. Aberrant muscle in the hand causing ulnar nerve compression. *Journal of Bone and Joint Surgery*, 46B, 1964, 361.
5. Khaledpour C and Schindelmeiser J. Atypical course of the rare accessory extensor carpi radialis muscle. *Journal of Anatomy*, 184, 1994, 161-163.
6. Hicks J and Newell R. Supernumerary muscles in the pectoral and axillary region, and the nature of the axillary arches. *Clinical Anatomy*, 10, 1997, 211-212.
7. Soldado-Carrera F, Vilar-Coromina N and Rodriguez-Baeza A. An accessory belly of the abductor digiti minimi muscle: a case report and embryologic aspects. *Surgical and Radiologic Anatomy*, 22, 2000, 51-54.
8. Olave E, Del Sol M, Gabrielli C, Prates JC and Rodrigues CFS. The ulnar tunnel: a rare disposition of its contents. *Journal of Anatomy*, 191, 1997, 615-616.
9. Natsis K, Levva S, Totlis T, Anastasopoulos N and Paraskevas G. Three-headed reversed palmaris longus muscle and its clinical significance. *Annals of Anatomy*, 189, 2007, 97-101.
10. Nakahashi T and Izumi R. Anomalous interconnection between flexor and extensor carpi radialis brevis tendons. *Anatomical Record*, 218, 1987, 94-97.
11. Sakuma E, Kato H, Honda N, Mabuchi Y and Soji T. A rare anomaly of the extensor digitorum longus. *Anatomical Science International*, 79, 2004, 235-238.
12. Gardner E, Gray DJ and O'rahilly R. *Anatomia: Estudo Regional do Corpo Humano*. 4 ed. Rio de Janeiro: Guanabara Koogan, 1988.
13. Aydinlioglu A, Sakul BU and Diyarbakirli S. A rare insertion site for abductor pollicis longus and extensor pollicis brevis muscles. *Acta Anatomica*, 163, 1998, 229-232.

14. D'costa S, Jiji PJ, Sivanadan R and Abhishek A. Anomalous muscle belly to the index finger. *Annals of Anatomy*, 188, 2006, 473-475.
15. Nakano M, Watanabe Y and Masutani M. A case of extensor digitorum brevis manus. *Dermatology Online*, 9, 2003, 21.
16. Windisch G. The fourth lumbrical muscle in the hand: a variation of insertion on the fifth finger. *Surgical and Radiologic Anatomy*, 22, 2000, 213-215.
17. Cigali BS, Kutoglu T and Cikmaz S. Musculus extensor digiti medii proprius and musculus extensor digitorum brevis manus - a case report of a rare variation. *Anatomia, Histologia, Embryologia*, 31(2), 2002, 126-127.
18. Hong, MK. An uncommon form of the rare extensor carpi radialis accessorius. *Annals of Anatomy*, 187, 2005, 89-92.