



Journal homepage: [www.mcmed.us/journal/ijacr](http://www.mcmed.us/journal/ijacr)

## A CASE REPORT ON VARIANT FIRST LUMBRICAL FOUND AT KJ SOMAIYA MEDICAL COLLEGE, SION, MUMBAI

**Brendon Barretto\***, Sharadkumar Pralhad Sawant, Rakhi M. More, Shaguphta T. Shaikh, Shaheen Rizvi, Uma R

Department of Anatomy, K. J. Somaiya Medical College,  
Somaiya Ayurvihar, Eastern Express Highway, Sion, Mumbai-400 022, India.

Corresponding Author:- **Brendon Barretto**

**E-mail:** bestbrendon@gmail.com

### Article Info

*Received 15/01/2015*

*Revised 27/01/2015*

*Accepted 12/02/2015*

### Key words:

Lumbricals,  
Accessory Belly,  
Intrinsic Muscles,  
Flexor Digitorum  
Profundus, Hand  
Surgeons.

### ABSTRACT

During routine dissection for first MBBS students on 70 years donated embalmed male cadaver in the Department of Anatomy, K. J. Somaiya Medical College, Sion, Mumbai, India, we observed an accessory belly of first lumbrical originating from the radial side of the most radial tendon of the flexor digitorum profundus (corresponding to the index finger) in the right hand. It passes posteriorly along the radial side of the index finger. The two bellies of first lumbricals join with each other to insert on the extensor expansion near the metacarpophalangeal joint. The photographs were taken for proper documentation. The existence of two bellies of first lumbrical should be kept in mind by surgeons operating on hand.

### INTRODUCTION

The lumbricals are intrinsic muscles of the hand that flex the metacarpophalangeal joints and extend the interphalangeal joints [1]. There are four of these small, worm-like muscles on each hand. These muscles are unusual in that they have no bony attachment. Instead they attach proximally to the tendons of flexor digitorum profundus and distally to the extensor expansions [2]. The first lumbrical is unipennate. It originates from the radial side of the most radial tendon of the flexor digitorum profundus (corresponding to the index finger). It passes posteriorly along the radial side of the index finger to insert on to the extensor expansion near the metacarpophalangeal joint. The second lumbrical is also unipennate. It originates from the radial side of the second most radial tendon of the flexor digitorum profundus (which corresponds to the middle finger). It passes posteriorly along the radial side of the middle finger and inserts on to the extensor expansion near the metacarpophalangeal joint. The third lumbrical is

bipennate. One head originates on the radial side of the flexor digitorum profundus tendon corresponding to the ring finger, while the other originates on the ulnar side of the tendon for the middle finger. The muscle passes posteriorly along the radial side of the ring finger to insert on its extensor expansion. The fourth lumbrical is bipennate. One head originates on the radial side of the flexor digitorum profundus tendon corresponding to the little finger, while the other originates on the ulnar side of the tendon for the ring finger. The muscle passes posteriorly along the radial side of the little finger to insert on its extensor expansion. The first and second lumbricals (the radial two) are innervated by the median nerve. The third and fourth lumbricals (the ulnar two) are innervated by the deep branch of the ulnar nerve. This is the usual innervation of the lumbricals (occurring in 60% of individuals). However 1:3 (median:ulnar - 20% of individuals) and 3:1 (median:ulnar - 20% of individuals)



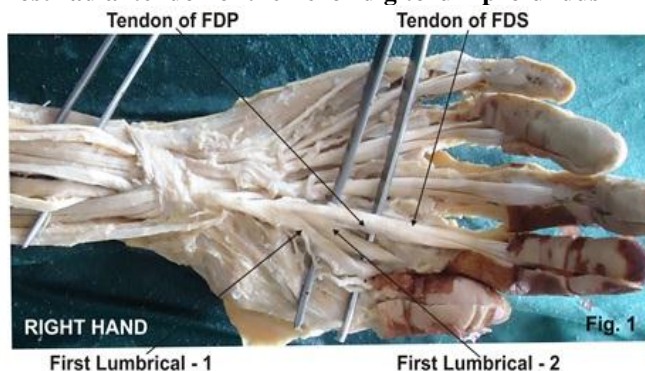
also exist. The lumbrical innervation always follows the innervation pattern of the associated muscle unit of flexor digitorum profundus (i.e. if the muscle units supplying the tendon to the middle finger are innervated by the median nerve, the second lumbrical will also be innervated by the median nerve] [3]. There are four separate sources of blood supply for these muscles: the superficial palmar arch, the common palmar digital artery, the deep palmar arch, and the dorsal digital artery. The lumbrical muscles, with the help of the interosseous muscles, simultaneously flex the metacarpophalangeal joints while extending both interphalangeal joints of the digit on which it inserts. The lumbricals are used during an upstroke in writing. As a part of the intrinsic musculature, the lumbricals are important for delicate digital movements. They are said to flex the metacarpophalangeal joints and extend the interphalangeal joints. These are quite unique in their position as they connect the flexors of the digits to the extensors and that both of its attachments are mobile. These play a vital role in the precision movements of the hands, along with thenar, hypothenar, and interossei muscles. There are also

lumbrical muscles of the foot that have a similar action, though these are of less clinical concern.

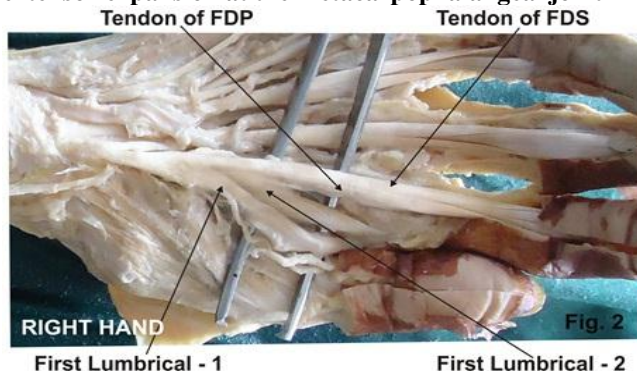
### CASE REPORT

During routine dissection for First MBBS students on 70 years donated embalmed male cadaver in the Department of Anatomy, K. J. Somaiya Medical College, Sion, Mumbai, India, we observed an accessory belly of first lumbrical originating from the radial side of the most radial tendon of the flexor digitorum profundus (corresponding to the index finger). It passed posteriorly along the radial side of the index finger. The two bellies of the first lumbrical joined with each other to insert on the extensor expansion at the metacarpophalangeal joint in the right hand. This additional slip was fleshy in the middle, while it was tendinous at both the ends. The additional slip of origin was innervated by a twig from the lateral branch of the median nerve. However second, third, fourth lumbricals were having normal origin, insertion and innervations. The photographs were taken for proper documentation.

**Figure 1. Photographic presentation of an accessory belly of first lumbrical originating from the radial side of the most radial tendon of the flexor digitorum profundus**



**Figure 2. Photographic presentation of The two bellies of the first lumbrical joined with each other to insert on the extensor expansion at the metacarpophalangeal joint**



### DISCUSSION

Much of the versatility of the human hand depends upon its intrinsic musculature. The lumbrical muscles constitute an important part of the intrinsic musculature of the hands. Lumbricals as a part of the intrinsic musculature are important for its delicate digital movements. Variations in the origin and insertion of the lumbricals are common [4].

Lumbrical muscle variation has been reported in the literature by various authors [5-9]. Mehta et al described the anomalous origin of first lumbrical in 2.7% cases they studied [10]. In the present case we observed an accessory belly of the first lumbrical originating from the radial side of the tendon of the flexor digitorum profundus to index finger which merged with the first lumbrical for insertion into the radial side of the index finger into the dorsal digital expansion. Additional lumbricals occurring more frequently than a reduction in their number. Origin of lumbricals may be displaced proximally arising from

flexor carpi radialis, flexor digitorum superficialis, flexor digitorum profundus or flexor pollicis longus. Accessory belly of first lumbrical may arise from flexor pollicis longus, flexor digitorum superficialis, first metacarpal, opponens pollicis or palmar carpal ligament [11]. In literature it has been found that the additional fibers from the forearm merged at varying points with the belly coming from the palmar origin and in no case reached the insertion of extensor expansion independently. Hence these are termed as additional forearm origin and not as double lumbricals [10]. In the present case the first lumbrical had an accessory belly originating from the radial side of the tendon of the flexor digitorum profundus to index finger hence termed as double lumbricals [10]. First lumbrical and the distal muscle belly for the index finger of the flexor digitorum superficialis have an intimate relationship with each other and have a common phylogenetic origin [12]. The articular system in the digits is connected by



mechanical links and lumbrical muscles are one of the links of this system that produces dynamic controlled extension of interphalangeal joints [1]. Potu BK et al studied an anomalous origin of the lumbrical muscles on South Indian cadavers [13]. Haines studied flexor muscles of the forearm and hand in the mammals and lizards; he suggested that the FDS in mammals is homologous with the intrinsic muscles of the palm, and that it shifts its origin proximally in forearm [14]. Further more Koizumi et al. mentioned that the first lumbrical muscle and the distal muscle belly for the index finger of the FDS have an intimate relationship with each other, and have a common phylogenetic origin [12]. From the above discussion it is quite clear that the additional muscle belly for the first lumbrical as observed in the present case has a phylogenetical significance.

## CONCLUSION

Clinicians and hand surgeons should be aware of such variations of first lumbrical while dealing with the hand, during various surgical procedures.

## REFERENCES

1. Standring S, editor. (2005). The anatomical basis of clinical practice. International 39th ed. Churchill Livingstone, Gray's Anatomy, 836.
2. Gosling JA, Harris PF, Humpherson JR, Whitmore I, Willan PLT. (2008). Human Anatomy, Color Atlas and Textbook by AL Bentley (5th ed.). Philadelphia, Mosby.
3. Last's Anatomy. (2000). Regional and Applied, 10th edn, Chummy S Sinnatam by, 64 and 82.
4. Bergman RA, Thompson SA, Afifi AK, Saadeh FA. (1988). Compendium of Human Anatomic Variation. Munich, Urban and Schwarzenberg, 13–14, 17.
5. Eriksen J. (1973). A case of carpal tunnel syndrome on the basis of an abnormally long lumbrical muscle. *Acta Orthop Scand*, 44, 275-7.
6. Goto S, Kojima T. (1993). An anomalous lumbrical muscle with an independent muscle belly associated with carpal tunnel syndrome. *Handchir Mikrochir Plast Chir*, 25, 72-4.
7. Koizumi M, Kawai K, Honma S, Kodama K. (2002). Anomalous lumbrical muscles arising from the deep surface of flexor digitorum superficialis muscles in man. *Ann Anat*, 184, 387-92.
8. Singh G, Bay BH, Yip GW, Tay S. (2001). Lumbrical muscle with an additional origin in the forearm. *ANZ J Surg*, 71, 301-2.
9. Potu BK, Gorantla VR, Rao MS, et al. (2008). Anomalous origin of the lumbrical muscles, a study on South Indian cadavers. *Morphologie*. doi, 10.1016/j.morpho.2008.04.006.
10. Mehta HJ, Gardner WU. (1961). A study of lumbrical muscles in the human hand. *Am J Anat*, 109, 227-38.
11. Ajmani ML. (2001). Morphological variations of lumbrical muscles in the human hand with some observations on its nerve supply. *Med J Iran Hosp*, 3, 20–25.
12. Koizumi M, Kawai K, Honma S, Kodma K. (2002). Anomalous lumbrical muscles arising from the deep surface of flexor digitorum superficialis muscles in man. *Ann Anat*, 184, 387–392.
13. Haines RW. (1950). The flexor muscles of the forearm and hand in lizards and mammals. *J Anat*, 84, 13–29.

## COMPETING INTERESTS

The authors declare that they have no competing interests.

## AUTHORS' CONTRIBUTIONS

SPS wrote the case report, performed the literature review & obtained the photograph for the study. RMM performed the literature search and assisted with writing the paper. STS conceived the study and helped to draft the manuscript. All authors have read and approved the final version manuscript.

## ACKNOWLEDGEMENT

All the authors wish to convey our sincere thanks to Dr. Arif A. Faruqui for his valuable help, support and inspiration. Authors also acknowledge the immense help received from the scholars whose articles are cited and included in references of this manuscript. The authors are also grateful to authors / editors / publishers of all those articles, journals and books from where the literature for this article has been reviewed and discussed.

