



NEUROMUSCULAR ENTRAPMENT IN THE ARM DUE TO VARIANT CORACOBRACHIALIS AND BRACHIALIS MUSCLES

Dishant D Oswal*, Sharadkumar Pralhad Sawant, Rakhi M More, Shaguphta T Shaikh,
Shaheen Rizvi, Uma R

Department of Anatomy, K.J. Somaiya Medical College,
Somaiya Ayurvihar, Eastern Express Highway, Sion, Mumbai-400 022, India.

Corresponding Author:- **Dishant D. Oswal**
E-mail: dishantoswal@gmail.com

<p>Article Info</p> <p><i>Received 15/01/2015</i> <i>Revised 27/01/2015</i> <i>Accepted 12/02/2015</i></p> <p>Key words: Coracobrachialis Muscle, Brachialis Muscle, Accessory Belly, Median Nerve, Brachial Artery, Variation, Neurovascular Compression, Upper Limb Injuries, Elbow Joint.</p>	<p>ABSTRACT</p> <p>During routine dissection for First MBBS students on a 65 years donated embalmed male cadaver in the Department of Anatomy, K.J.Somaiya Medical College, we observed an entrapment of brachial artery and median nerve by coracobrachialis and brachialis muscles. The median nerve and the brachial artery passed through the coracobrachialis muscle in the right arm. The superficial fibres of the coracobrachialis muscle were normal in their insertion i.e. on the middle 5 cm of the medial border of the shaft of the humerus. We also encountered an accessory slip of the brachialis muscle originated from anteromedial surface of the shaft of humerus and got inserted into the medial epicondyle of the humerus. The accessory slip of the brachialis muscle passed over the brachial artery and the median nerve. This may result in neurovascular compression and it may have some mechanical advantages and disadvantages during the movement of elbow joint. The knowledge of such variations were important for medical fraternity such as surgeons, orthopaedicians, neurologists, radiologists and physiotherapist for dealing with injuries or operations around the elbow joint.</p>
--	--

INTRODUCTION

The coracobrachialis muscle shows several interesting morphological and anatomical characteristics. It is the counterpart in the arm of the adductors (longus, brevis, magnus) of the thigh. It arises from the apex of the coracoid process, where it is fused with the medial side of the short head of biceps. The tendon is continued into a muscular belly of varying development which is inserted into the medial border of the humerus. The lower extent of the insertion is marked by the nutrient foramen of the humerus, for the nutrient branch of the brachial artery runs along the lower border of the muscle. The upward extent of the insertion cannot be seen on most bones, the muscle usually leaves no impression. The musculocutaneous nerve passes through the muscle and supplies it. Compared to the

morphological interest of this muscle its action is negligible. It is a weak adductor of the shoulder joint, the main adductors of which are pectoralis major and latissimus dorsi [1,2].

In some animals the coracobrachialis muscle has three heads[3]; in man two have fused, trapping the nerve between them, and the third part has become suppressed. The occasional supratrochlear spur [on the anteromedial aspect of the lower humerus] may be continuous with a ligament [of Struthers] which passes to the medial epicondyle and represents the remains of the third head [4]. The median nerve or brachial artery or both may run beneath it and be subjected to compression. The brachialis is the muscle of the front of the arm region. It is situated



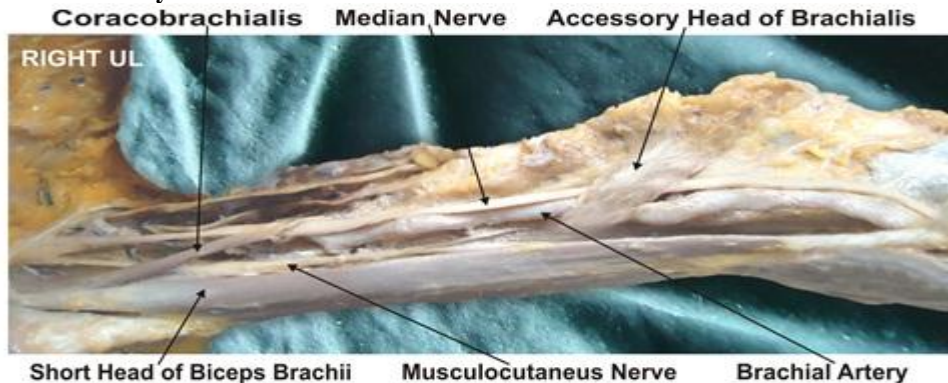
behind the biceps brachii muscle. The brachialis arises from the lower half of the front of the shaft of the humerus including both the anteromedial and anterolateral surface of the shaft of the humerus. It also take origin from lower part of the present on the posterior surface of the shaft of the humerus and the medial intermuscular septum attached to the medial border of the shaft of the humerus. It is separated distally from the lateral intermuscular septum by brachioradialis and extensor carpi radialis longus muscle. The brachialis covers the anterior part of the elbow joint. The fibres of brachialis muscle converge to form a thick and broad tendon which is inserted into the ulnar tuberosity and to a rough surface on the anterior part of the coronoid process of ulna. The brachialis muscle is hybrid muscle, it has dual nerve supply. The muscles cutaneous nerve (C5, 6) supplies the medial part of the muscle. Whereas the radial nerve [7] supplies its lateral part. The brachialis muscle is a flexor of the elbow joint. The brachialis muscle along with the supinator muscle forms the floor of the cubital fossa. The content of cubital fossa from medial to lateral side are median nerve, brachial artery, tendon of biceps brachii muscle and radial nerve. All these contents of cubital fossa are present anterior to the brachialis muscle. The brachialis muscle may be derived into two or more parts. It may be fused with the brachioradialis, the pronator teres or the biceps brachii muscle. Sometimes the brachialis muscle may give slip to radius or bicipital aponeurosis. The blood supply of the brachialis muscle is derived from the superior and inferior branches. The superior branch is from the brachial artery and the inferior branch is either from the superior ulnar collateral artery or from the brachial artery. The accessory arteries supplying the brachialis muscle are small and variable in number.

They may arise from the brachial artery, superior and inferior ulnar collateral arteries or the profunda brachii artery. The brachialis muscle can be tested clinically by palpating its fibres during flexion of elbow joint against resistance.

CASE REPORT

During routine dissection for First MBBS students on a 65 years donated embalmed male cadaver in the Department of Anatomy, K.J.Somaiya Medical College, we observed an entrapment of brachial artery and median nerve by coracobrachialis and brachialis muscles in the right upper limb. It was unilateral. The median nerve and the brachial artery passes through the coracobrachialis muscle. The superficial fibres of the coracobrachialis muscle were normal in their insertion i.e. on the middle 5 cm of the medial border of the shaft of the humerus. An accessory slip of brachialis muscle originated from the anteromedial surface of the shaft of the humerus and got inserted into medial epicondyle of the humerus. This accessory slip of the brachialis muscle passed over the brachial artery and the median nerve. The median nerve and the brachial artery passes deep to the superficial fibres of the coracobrachialis muscle in the upper 1/3rd of the arm and deep to the accessory slip of brachialis muscle in the lower 1/3rd of the arm. Such type of double muscular variation is very rare and not documented in the literature. The further course of the brachial artery and the median nerve was normal. The accessory slip of the brachialis muscle was supplied by the musculocutaneous nerve. The left arm of the same cadaver was normal. The photographs of the variations were taken for proper documentation and for ready reference.

Figure 1. Showing the superficial fibres of the coracobrachialis muscle and an accessory slip of the brachialis muscle passed over the brachial artery and the median nerve



DISCUSSION

The accessory head of coracobrachialis muscle may be attached to the lesser tubercle, medial epicondyle or the medial intermuscular septum [2]. The clinical implication of the accessory head of the coracobrachialis is that it has the potential to cause the median nerve entrapment and the brachial artery compression. Various

studies have described the compression of the median nerve and the brachial artery with anomalous muscles [5,6,7,8]. In the present case the accessory head of the coracobrachialis muscle arises from superficial fibres of the coracobrachialis muscle having 3cm muscle belly and 15cm tendinous band. It extended downwards and medially in front of the median nerve and brachial artery and finally



got inserted on the anteromedial aspect of the medial epicondyle of the humerus. The accessory head of the coracobrachialis muscle reported in this case may be explained on the basis of the embryogenesis of the muscles of the arm. During development, the limb bud mesenchyme of the lateral plate differentiates into the intrinsic muscles of the upper limb. A single muscle mass is formed by fusion of the muscle primordia within the different layers of the arm at certain stages of development; thereafter, some muscle primordia disappears through cell death. The morphological variations of the coracobrachialis muscle may be due to failure of muscle primordia to disappear during the embryological development [9].

The presence of accessory belly of the brachialis muscle has been reported by many authors. Dharap observed an unusual muscle that passed obliquely from the middle of the humerus anterior to the median nerve and brachial artery, forming a tunnel for them, before inserting with the common origin of the forearm flexor muscles [5]. Loukas et al. reported an accessory brachialis muscle originating from middle of the shaft of the humerus and the medial intermuscular septum. The accessory brachialis muscle crossed over both the brachial artery and the median nerve. The distal tendon split to surround the median nerve before inserting into the brachialis tendon and the common tendon of the antebrachial flexor compartment muscles [10]. Paraskevas et al. have described a variant muscle on the left side arising from the medial border of the brachialis muscle and after bridging the median nerve, the brachial artery and vein; it was fused with the medial intermuscular septum. The muscle was innervated by the musculocutaneous nerve [11]. George and Nayak have described few fleshy fibers of brachialis arising from the distal third of the muscle and merging with superficial flexors of the forearm and to the medial aspect of the olecranon process of ulna [12]. Rajanigandha et al. reported the occurrence of an accessory brachialis muscle that formed a fibro-muscular tunnel after blending with the medial intermuscular septum [13]. An anomalous muscle, without any contribution from the biceps or the brachialis, originated between the coracobrachialis and the brachialis from the humerus, has been reported previously. This muscle passed obliquely across the front of the brachial artery and the median nerve. The muscle also was found to blend with common origin of flexor muscles. There are three well described entrapment syndromes involving the median nerve or its branches, namely carpal tunnel syndrome, pronator teres syndrome and anterior interosseous syndrome. A few case reports were found in the literature, explaining the possible median nerve entrapment due to a third head of biceps brachii [14,15]. Even though anatomy literature hardly mentions the median nerve compression due to bicipital aponeurosis, a few research reports say that it could be a cause of high median nerve compression, along with brachial artery [16]. The simultaneous occurrence of the above mentioned

variants in the same specimen has not been reported to the best of our knowledge. Although causes no symptoms most of the time, such structures have the potential to compress the median nerve with consequent functional impairment. Such accessory muscle slips may also compress the underlying arteries viz., ulnar artery in the present case. Embryologically, the intrinsic muscles of the upper limb differentiate in situ, opposite the lower six cervical and upper two thoracic segments, from the limb bud mesenchyme of the lateral plate mesoderm. The formation of muscular elements in the limbs takes place shortly after the skeletal elements begin to take shape. At a certain stage of development, the muscle primordia within the different layers of the arm fuse to form a single muscle mass [17]. Langman stated, however, that some muscle primordia disappear through cell death despite the fact that cells within them have differentiated to the point of containing myofilaments [18]. Failure of muscle primordia to disappear during embryologic development may account for the presence of the accessory muscular bands reported in this case. Compression of the median nerve and brachial artery by various types of structures leading to clinical neurovasculopathy has been reported [19, 20]. On contraction, these muscles can compress the median and ulnar nerves, leading to further irritation of the nerves. Also, on contraction these muscles can compress both the brachial artery and brachial veins. The possibility of those muscles anomalies should, therefore, be considered when in any patient, a high median or ulnar or medial antebrachial cutaneous nerve paralysis exists with symptoms of lower brachial artery or brachial vein compression. Also, these muscles should not be mistaken for tumors on MR imaging of the arm [21]. The fibres of accessory slip of the brachialis muscle can be used in reconstruction surgery of the annular ligament and the medial collateral ligament of elbow joint.

COMPETING INTERESTS

The authors declare that they have no competing interest.

AUTHORS' CONTRIBUTIONS

DDO wrote the case report, SPS performed the literature review, SR obtained the photograph for the case, RMM performed the literature search and RU assisted with writing the paper. STS helped to draft the manuscript. All authors have read and approved the final version manuscript.

ACKNOWLEDGEMENT

All the authors wish to convey our sincere thanks to our Dean Dr. Geeta Niyogi Madam for her valuable help, support and inspiration. We are also thankful to Mr. M. Murugan. Authors also acknowledge the immense help received from the scholars whose articles are cited and included in references of this manuscript. The authors are also grateful to authors / editors / publishers of all those articles, journals and books from where the literature for this article has been reviewed and discussed.



REFERENCES

1. Standring S, ed. Gray's Anatomy. (2005). The anatomical basis of clinical practice. 39th Ed, Elsevier Churchill Livingstone, 855, 859.
2. Mc Minn RMH. (1990). Editor Last's anatomy, regional and applied. 8. Edinburgh, Churchill Livingstone, 79.
3. Parsons FG. (1898). The muscles of mammals with special relation to human myology. *J Anat*, 32, 721-52.
4. Struthers J. (1854). On some points in the abnormal anatomy of the arm. *Br Foreign Med Chir Rev*, 14, 224-36.
5. Dharap AS. (1994). An anomalous muscle in the distal half of the arm. *Surg Radiol Anat*, 16, 97-99.
6. El-Naggar M. (2001). A study on the morphology of the coracobrachialis muscle and its relationship with the musculocutaneous nerve. *Folia Morphol (Warsz)*, 60, 217-224.
7. El-Naggar M, Al-Saggaf S. (2004). Variant of the Coracobrachialis Muscle with a Tunnel for the Median Nerve and Brachial Artery. *Clin Anat*, 17, 139-143.
8. Vollala VR, Nagabhooshana S, Bhat SM, Potu BK, Gorantla VR. (2008). Multiple accessory structures in the upper limb of a single cadaver. *Singapore Med J*, 49, e254-e258.
9. Lewis WH. (1910). The development of the muscular system. In, Keibel F, Mall FP, ed. Manual of Embryology. Vol 2. Philadelphia, JB Lippincott, 455-522.
10. Loukas M, Louis RG Jr, South G, Alsheik E, Christopherson C. (2006). A case of an accessory brachialis muscle. *Clin Anat*, 19, 550-553.
11. Paraskevas G, Natsis K, Loannidis O, Papaziogas B, Kitsoulis P, Spanidou S. (2008). Accessory muscles in the lower part of the anterior compartment of the arm that may entrap neurovascular elements. *Clin Anat*, 21, 246-251.
12. George BM, Nayak SB. (2008). Median nerve and brachial artery entrapment in the abnormal brachialis muscle – a case report. *Neuroanatomy*, 7, 41-42.
13. Vadgaonkar R, Rai R, Ranade AV, Nayak SR, Pai MM, Lakshmi R. (2008). A case report on accessory brachialis muscle. *Rom J Morphol Embryol*, 49, 581-583.
14. Paval J. (2006). A rare case of possible median nerve entrapment. *Neuroanatomy*, 5, 35-38.
15. Mas N, Pelin C, Zagyanan r, Bahar H. (2006). Unusual relation of the median nerve with the accessory head of the biceps brachii muscle, an original case report. *Int J Morphol*, 24, 561-564.
16. Kumar H, Das S, Gaur S. (2007). Entrapment of the median nerve and the brachial artery by lacertus fibrosis. *Arch Sci*, 3, 284-286.
17. Arey LB. (1960). Developmental Anatomy. In, A Textbook and Laboratory Manual of Embryology. 6th Ed, Philadelphia, WB Saunders Company, 434-435.
18. Langman J. (1969). Medical Embryology. 2nd Ed, Baltimore, Williams and Wilkins, 143-146.
19. Gessini L, Jandolo B, Pietrangeli A. (1983). Entrapment neuropathies of the median nerve at and above the elbow. *Surg Neurol*, 19, 112-116.
20. Nakatani T, Tanaka S, Mizukami S. (1998). Bilateral four-headed biceps brachii muscles, the median nerve and brachial artery passing through a tunnel formed by a muscle slip from the accessory head. *Clin Anat*, 11, 209-212.
21. Leonello DT, Galley IJ, Bain GI, Carter C.D. (2007). Brachialis muscle anatomy. A study in cadavers. *J Bone Joint Surg Am*, 89, 1293-1297.

