



**A CASE REPORT ON VARIANT DISTAL ATTACHMENT OF
BRACHIALIS MUSCLE**

**Janhavi H Bhende*, Sharadkumar Pralhad Sawant, Rakhi M. More, Shaguphta T. Shaikh,
Shaheen Rizvi, Uma R**

Department of Anatomy, K.J.Somaiya Medical College,
Somaiya, Ayurvihar, Eastern Express Highway, Sion, Mumbai-400 022, India.

Corresponding Author:- **Janhavi H Bhende**
E-mail: janhavibhende@gmail.com

<p>Article Info <i>Received 15/01/2015</i> <i>Revised 27/01/2015</i> <i>Accepted 12/02/2015</i></p> <p>Key words: Accessory Brachialis Muscle, Median Nerve, Brachial Artery, Variation, Nerve Compression, Radius Bone, Pronation and Supination, Orthopedicians.</p>	<p>ABSTRACT During routine dissection for first M.B.B.S. students on 65 years donated embalmed male cadaver in the Department of Anatomy, K. J. Somaiya Medical College, we observed an additional insertion of left brachialis muscle. The origin of the accessory muscle belly was from the anteromedial surface of the shaft and the medial supracondylar ridge of the lower end of the humerus. The accessory muscle slip merged with the tendon of pronator teres and got inserted on to the upper one third of the lateral surface of the shaft of the radius. The accessory muscle belly of the brachialis muscle was innervated by musculocutaneous nerve. The median nerve and the brachial artery travelled deep to the accessory muscle belly of the brachialis muscle. The role of additional muscles in compression syndrome is a well known phenomenon. Similar to the biceps brachii muscle, the brachialis got inserted on the radius bone, and therefore can participate in pronation and supination of the forearm. There was no associated altered anatomy of the blood vessels observed in the specimen. The right upper limb of the same cadaver was normal. The photographs of the variations were taken for proper documentation and for ready reference. The knowledge of such type of variation is clinically important for Anatomists, Neurologists, Radiologists, Surgeons Plastic surgeons and Orthopedicians.</p>
--	---

INTRODUCTION

The brachialis is a muscle in the upper arm that flexes the elbow joint. It lies deeper than the biceps brachii, and is a synergist that assists the biceps brachii in flexing at the elbow. It makes up part of the floor of the region known as the cubital fossa. The brachialis originates from the lower half of the front of the humerus, near the insertion of the deltoid muscle, which it embraces by two angular processes. Its origin extends below to within 2.5 cm of the margin of the articular surface of the humerus at the elbow joint. It also arises from the intermuscular septa of the arm, but more extensively from the medial than the lateral; it is separated from the lateral below by the brachioradialis and extensor carpi radialis longus muscles. Its fibers converge to a thick tendon, which is inserted into the tuberosity of the ulna and the rough depression on the

anterior surface of the coronoid process of the ulna. The brachialis muscle is innervated by the musculocutaneous nerve, which runs on its superficial surface, between it and the biceps brachii. Part of it is also innervated by the radial nerve (proprioceptive branch) which allows it to be split during certain approaches to the arm. The divide between the two innervations is at the insertion of the deltoid. Unlike the biceps, the brachialis does not insert on the radius, and therefore cannot participate in pronation and supination of the forearm. It flexes the elbow joint. The muscle is occasionally doubled; additional nip to the supinator, pronator teres, biceps brachii, bicipital aponeurosis, brachioradialis or radius are more rarely found [1].



CASE REPORT

During routine dissection for first M.B.B.S. students on 65 years donated embalmed male cadaver in the Department of Anatomy, K. J. Somaiya Medical College, we observed an additional insertion of left brachialis muscle. The origin of the accessory muscle belly was from the anteromedial surface of the shaft and the medial supracondylar ridge of the lower end of the humerus. The accessory muscle slip merged with the tendon of pronator teres and got inserted on to the upper one third of the lateral surface of the shaft of the radius. The accessory muscle belly of the brachialis muscle was

innervated by musculocutaneous nerve. The median nerve and the brachial artery travelled deep to the accessory muscle belly of the brachialis muscle. The role of accessory muscles in compression syndrome is a well known phenomenon. Similar to the biceps brachii muscle, the brachialis got inserted on the radius bone, and therefore can participate in pronation and supination of the forearm. There was no associated altered anatomy of the blood vessels observed in the specimen. The right upper limb of the same cadaver was normal. The photographs of the variations were taken for proper documentation and for ready reference.

Figure 1. The origin of the accessory muscle belly was from the anteromedial surface of the shaft and the medial supracondylar ridge of the lower end of the humerus

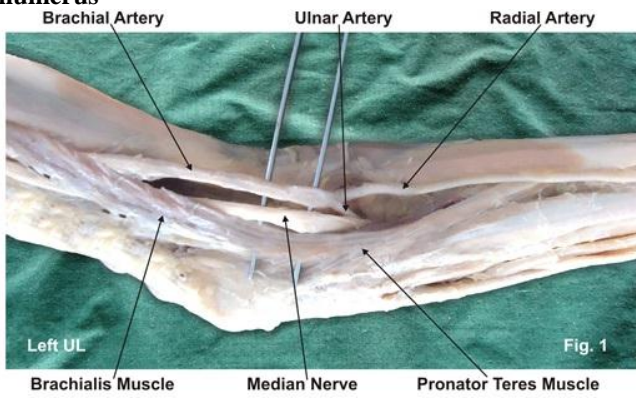


Figure 2. The accessory muscle slip merged with the tendon of pronator teres and got inserted on to the upper one third of the lateral surface of the shaft of the radius

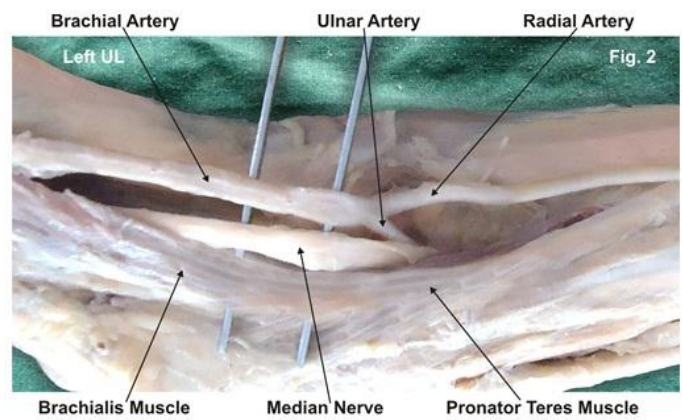
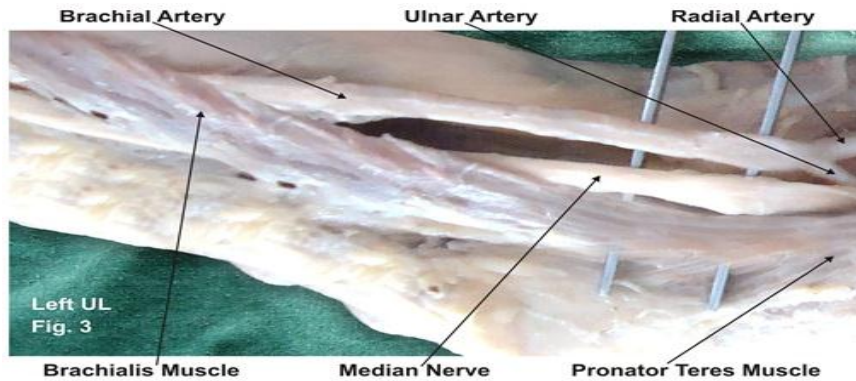


Figure 3. The median nerve and the brachial artery travelled deep to the accessory muscle belly of the brachialis muscle



DISCUSSION

Several cases on the presence of accessory brachialis muscle in the arm have been reported. Dharap observed an unusual muscle that passed obliquely from the middle of the humerus anterior to the median nerve and brachial artery, forming a tunnel for them, before inserting with the common origin of the forearm flexor muscles [2]. Loukas et al. reported an accessory brachialis muscle originating from mid shaft of humerus and medial intermuscular septum. During its course medially, toward the elbow, the accessory brachialis muscle crossed both the

brachial artery and the median nerve. The distal tendon split to surround the median nerve before inserting into the brachialis tendon and the common tendon of the antebrachial flexor compartment muscles [3]. Paraskevas et al. have described a variant muscle on the left side arising from the medial border of brachialis muscle and after bridging the median nerve, the brachial artery and vein; it was fused with the medial intermuscular septum. The muscle was innervated by musculocutaneous nerve (4). George and Nayak have described few fleshy fibers of brachialis arising from the distal third of the muscle and



merging with superficial flexors of the forearm and to the medial aspect of olecranon process of ulna [5]. Rajanigandha et al. reported the occurrence of an accessory brachialis muscle that formed a fibro-muscular tunnel after blending with the medial intermuscular septum [6]. Although the accessory brachialis muscle documented in the present case causes no symptoms most of the time but they have the potential to compress the median nerve and the brachial artery with consequent functional impairment. The compression of the median nerve and brachial artery by various types of structures leading to clinical neurovasculopathy has been reported in literature [7,8]. Also, these muscles should not be mistaken for tumors on magnetic resonance imaging of the arm.

DEVELOPMENTAL BASIS OF PRESENT VARIATION

Embryologically, the intrinsic muscles of the upper limb differentiate in situ, opposite the lower six cervical and upper two thoracic segments, from the limb bud mesenchyme of the lateral plate mesoderm. The formation of muscular elements in the limbs takes place shortly after the skeletal elements begin to take shape. At a certain stage of development, the muscle primordia within the different layers of the arm fuse to form a single muscle mass [9]. Langman stated, however, that some muscle primordia disappear through cell death despite the fact that cells within them have differentiated to the point of containing myofilaments [10]. Failure of muscle primordia to disappear during embryologic development may account for the presence of the accessory muscular bands reported in this case.

CONCLUSION

The existence of such variation of the brachialis muscle should be kept in mind by the surgeons operating on patients with high median nerve palsy and brachial

artery compression, by the orthopaedicians dealing with fracture of the humerus, the radiologists while doing radiodiagnostic procedures e.g. CT scan, MRI of the arm and angiographic studies and also by the physiotherapists. These accessory fibres of brachialis may be used as a transposition flap in deformities of infraclavicular and axillary areas and in postmastectomy reconstruction. The accessory fibres of brachialis may prove significant and lead to confusion during surgical procedures or cause compression of neurovascular structures. As the accessory fibres of brachialis muscle are inserted on the radius bone, the brachialis muscle play important role in pronation and supination of the forearm.

COMPETING INTERESTS

The authors declare that they have no competing interest.

AUTHORS' CONTRIBUTIONS

JHB wrote the case report, SPS performed the literature review, SR obtained the photograph for the case, RMM performed the literature search and RU assisted with writing the paper. STS helped to draft the manuscript. All authors have read and approved the final version manuscript.

ACKNOWLEDGEMENT

All the authors wish to convey our sincere thanks to our Dean Dr. Geeta Niyogi Madam for her valuable help, support and inspiration. We are also thankful to Mr. M. Murugan. Authors also acknowledge the immense help received from the scholars whose articles are cited and included in references of this manuscript. The authors are also grateful to authors / editors / publishers of all those articles, journals and books from where the literature for this article has been reviewed and discussed.

REFERENCES

1. Standring S, ed. (2005). Gray's Anatomy, The anatomical basis of clinical practice. 39th Ed, Elsevier Churchill Livingstone, 855.
2. Dharap AS. (1994). An anomalous muscle in the distal half of the arm. *Surg Radiol Anat*, 16, 97–99.
3. Loukas M, Louis RG Jr, South G, Alsheik E, Christopherson C. (2006). A case of an accessory brachialis muscle. *Clin Anat*, 19, 550–553.
4. Paraskevas G, Natsis K, Loannidis O, Papaziogas B, Kitsoulis P, Spanidou S. (2008). Accessory muscles in the lower part of the anterior compartment of the arm that may entrap neurovascular elements. *Clin Anat*, 21, 246–251.
5. George BM, Nayak SB. (2008). Median nerve and brachial artery entrapment in the abnormal brachialis muscle – a case report. *Neuroanatomy*, 7, 41–42.
6. Vadgaonkar R, Rai R, Ranade AV, Nayak SR, Pai MM, Lakshmi R. (2008). A case report on accessory brachialis muscle. *Rom J Morphol Embryol*, 49, 581–583.
7. Gessini L, Jandolo B, Pietrangeli A. (1983). Entrapment neuropathies of the median nerve at and above the elbow. *Surg Neurol*, 19, 112–116.
8. Nakatani T, Tanaka S, Mizukami S. (1998). Bilateral four-headed biceps brachii muscles, the median nerve and brachial artery passing through a tunnel formed by a muscle slip from the accessory head. *Clin Anat*, 11, 209–212.
9. Arey LB. (1960). Developmental Anatomy. In, A Textbook and Laboratory Manual of Embryology. 6th Ed, Philadelphia, WB Saunders Company, 434–435.
10. Langman J. (1969). Medical Embryology. 2nd Ed, Baltimore, Williams and Wilkins, 143–146.

