



VARIANT TERMINATION OF POPLITEAL ARTERY – A CASE REPORT

**Sagar S Sadarangani*, Sharadkumar Pralhad Sawant, Rakhi M More,
Shaguphta T Shaikh, Shaheen Rizvi, Uma R**

Department of Anatomy, K. J. Somaiya Medical College,
Somaiya Ayurvihar, Eastern Express Highway, Sion, Mumbai-400 022, India.

Corresponding Author:- **Sagar S Sadarangani**

E-mail: sagarsadarangani@hotmail.com

Article Info	ABSTRACT
<p><i>Received 15/01/2015</i> <i>Revised 27/01/2015</i> <i>Accepted 12/02/2015</i></p> <p>Key words: Popliteal Artery, Anterior Tibial Artery, Popliteus Muscle, Posterior Peroneotibial Trunk, Posterior Tibial Artery, Peroneal Artery, Tendinous Arch of Soleus, Orthopaedicians, Arthroscopic Knee Surgery, Radiologist, Angiographic Study.</p>	<p>ABSTRACT</p> <p>During routine dissection for first MBBS students on 65 years donated embalmed male cadaver in the Department of Anatomy, K.J.Somaiya Medical College, we observed the high origin of anterior tibial artery from the popliteal artery proximal to the popliteus muscle. The anterior tibial artery ran downward on the posterior surface of the popliteus muscle. The posterior peroneotibial trunk distal to the tendinous arch of soleus muscle divides into the posterior tibial and the peroneal arteries. The further course of anterior, posterior tibial and peroneal arteries was normal. The photographs of the variations were taken for proper documentation and ready reference. There were no associated neuromuscular variations found in same specimen. The right lower limb of the same cadaver was normal. The arthroscopic knee surgery is a convenient and preferred surgical procedure. The knowledge of branching pattern of popliteal artery is important for surgical interventions in the popliteal region in order to minimize the surgical complications due to anatomical variations. Therefore the origin of anterior tibial artery from the popliteal artery proximal to the popliteus muscle is an important anatomical variation which should be kept in mind by the orthopaedicians doing knee joint surgery and total knee arthroplasty, by the surgeons operating on aneurysms of popliteal artery and by the radiologist performing angiographic study.</p>

INTRODUCTION

The popliteal artery is the continuation of the femoral artery. It begins at the level of hiatus magnus and ends at the lower border of popliteal muscle by dividing into anterior tibial and posterior tibial arteries [1]. The popliteus muscle is the 'key muscle' of the popliteal region. The popliteal artery may divide proximal to the lower border of popliteal muscle. This is called as 'high division of the popliteal artery'. In high division, the anterior or posterior branch may arise at or above the articular surface of the tibial plateau [2]. When the popliteal artery divides any where proximal to the lower

border of the muscle, it is termed as 'high division of the popliteal artery' [3]. The anterior tibial artery runs downwards on the posterior surface of the popliteus muscle and then it enters in to the anterior compartment of the leg through the oval space located at the superior border of the interosseous membrane of the leg. There it travels on the anterior surface of the interosseous membrane along with the deep peroneal nerve [1]. The popliteal artery may divide proximal to the popliteus muscle into anterior and posterior tibial arteries. The anterior tibial artery descends downward either anterior or posterior to the popliteus



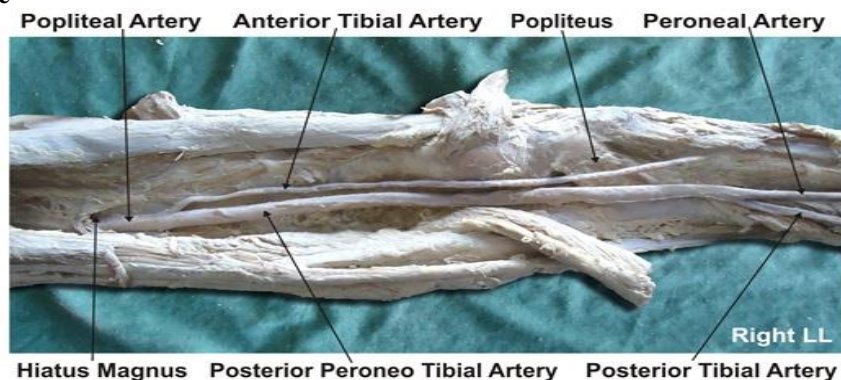
muscle [1]. The popliteal artery may terminate distal to the lower border of popliteus muscle which may interfere with the reconstruction surgeries [4]. The variations in the branching pattern of the popliteal artery increase the risk of vascular trauma and unnecessary haemorrhage during arthroscopic surgery of knee joint. Preoperative diagnosis of variations in the branching pattern of the popliteal artery may help to avoid excessive unwanted haemorrhage and unnecessary complications during surgery [5]. The knowledge of variations in the branching pattern of the limb arteries are important for the success of the arthroscopic surgeries.

CASE REPORT

During routine dissection for first MBBS students on 65 years donated embalmed male cadaver in the Department of Anatomy, K.J.Somaiya Medical College, we observed the origin of anterior tibial artery from the popliteal artery proximal to the popliteus muscle. The

popliteal artery immediately below the adductor hiatus terminated into anterior tibial artery and perineotibial trunk. The termination level of the popliteal artery was proximal to the upper border of the popliteus muscle. The anterior tibial artery ran downwards on the posterior surface of the popliteus muscle and then it entered in to the anterior compartment of the leg through the oval space located at the superior border of the interosseous membrane of leg. There it traveled downwards on the anterior surface of the interosseous membrane along with the deep peroneal nerve. The posterior peroneotibial trunk distal to the tendinous arch of soleus muscle divided into the posterior tibial and the peroneal arteries. The rest of the course of anterior, posterior tibial and peroneal arteries was normal. The photographs of the variations were taken for proper documentation and ready reference. There were no associated neuromuscular variations found in same specimen. The right lower limb of the same cadaver was normal.

Figure 1. Photographic presentation of the right popliteal artery terminating into anterior tibial artery and perineotibial trunk below the adductor hiatus. The anterior tibial artery running downwards on the posterior surface of the popliteus muscle



DISCUSSION

The variations in the branching pattern of the popliteal artery are common. The high level termination of the popliteal artery in relation to the upper border of the popliteus muscle was grouped into 3 types by Adachi. In type I the popliteal artery descended on the posterior surface of the popliteus muscle. The popliteal artery divides into the posterior peroneotibial trunk and the anterior tibial artery. The posterior peroneotibial trunk further divides into the peroneal artery and the posterior tibial artery. The diameter of the anterior tibial artery was equal to the popliteal artery or smaller than the posterior peroneotibial trunk. In type II the popliteal artery descended on the posterior surface of the popliteus muscle. It was divided into the posterior tibial artery and the anterior peroneotibial trunk. The diameter of the anterior peroneotibial trunk was observed to be larger. The anterior peroneotibial trunk divided into the peroneal artery and anterior tibial artery at the lower border of the popliteus muscle. In type III the popliteal artery terminated into the anterior tibial artery and posterior peroneotibial trunk at the

upper border of the popliteus muscle. The anterior tibial artery ran downward in between the anterior surface of the popliteus muscle and the posterior surface of the tibia. The posterior peroneotibial trunk ran on the posterior surface of the popliteus muscle. The posterior peroneotibial trunk divided into the peroneal artery and posterior tibial artery distal to the tendinous arch of soleus muscle [2]. The variation in the termination of popliteal artery observed in the present case is of Adachi's type III. The high origin of anterior tibial artery at or above the level of the articular surface of the tibial plateau is documented in literature [6, 7, 8, 9]. Another radiological study of the femoral angiograms on 495 lower extremities was performed to view the tibial arterial anatomy, and found that 7.8% of the cases revealed variations [4]. Normally the diameter of the posterior tibial artery is more than the diameter of the peroneal artery, but in present case the diameter of the peroneal artery was more than the diameter of the posterior tibial artery which is similar to the study of Ozgur et al [8]. It was reported in previous studies that the course of anterior tibial artery could either be from the anterior or



posterior surface of the popliteus muscle [6, 7, 10]. The course of anterior tibial artery on the anterior surface of the popliteus muscle was observed in 1-2.1% of the cases [2, 3, 5, 7, 9, 10]. The course of anterior tibial artery on the posterior surface of the popliteus muscle was observed in 40% of the cases. In present case the course of anterior tibial artery on the posterior surface of the popliteus muscle was observed. Clinicians and radiologists have defined a different terminology of the popliteal artery and its main branches in popliteal surgery. The anterior tibial artery was defined as the tibial-fibular trunk as soon as it branched from the popliteal artery [6]. The tibial arteries were referred to as anterior or posterior peroneotibial trunk depending upon the origin of the peroneal artery [2]. In the present case the peroneal artery arises from the posterior tibial artery and hence the posterior tibial artery is defined as the tibial – fibular trunk.

CONCLUSION

The arthroscopic knee surgery is a convenient and preferred surgical procedure. The knowledge of branching pattern of the popliteal artery is important for surgical interventions in the popliteal region in order to minimize the surgical complications due to anatomical variations. Therefore the origin of the anterior tibial artery from the popliteal artery proximal to the popliteus muscle is an important anatomical variation which should be kept in mind by the orthopaedicians doing knee joint surgery and total knee arthroplasty, by the surgeons operating on

aneurysms of popliteal artery and by the radiologists performing angiographic study. These variations are compared with the earlier data & it is concluded that variations in branching pattern of cords of the popliteal artery are a rule rather than an exception.

COMPETING INTERESTS

The authors declare that they have no competing interest.

AUTHORS' CONTRIBUTIONS

SSS wrote the case report, SPS performed the literature review, SR obtained the photograph for the case, RMM performed the literature search and RU assisted with writing the paper. STS helped to draft the manuscript. All authors have read and approved the final version manuscript.

ACKNOWLEDGEMENT

All the authors wish to convey our sincere thanks to our Dean Dr. Geeta Niyogi Madam for her valuable help, support and inspiration. We are also thankful to Mr. M. Murugan.

Authors also acknowledge the immense help received from the scholars whose articles are cited and included in references of this manuscript. The authors are also grateful to authors / editors / publishers of all those articles, journals and books from where the literature for this article has been reviewed and discussed.

REFERENCES

1. Standring S. (2008). Gray's Anatomy. 40th Ed., London, Churchill Livingstone, 1408, 1424.
2. Adachi B. (1928). Das Arteriensystem der Japaner, band 2. Kyoto, Kenkyusha, 198–201.
3. Lippert H, Pabst R. (1985). Arterial variations in man, classification and frequency. Munchen, JF Bergman Verlag, 62.
4. Kim D, Orron DE, Skillman JJ. (1989). Surgical significance of popliteal arterial variants. A unified angiographic classification. *Ann Surg*, 210, 776–781.
5. Klecker RJ, Winalski CS, Aliabadi P, Minas T. (2008). The aberrant anterior tibial artery, magnetic resonance appearance, prevalence, and surgical implications. *Am J Sports Med*, 36, 720–727.
6. Day CP, Orme R. (2006). Popliteal artery branching patterns-an angiographic study. *Clin Radiol*, 61, 696–699.
7. Kil SW, Jung GS. (2009). Anatomical variations of the popliteal artery and its tibial branches, analysis in 1242 extremities. *Cardiovasc Intervent Radiol*, 32, 233–240.
8. Ozgur Z, Ucerler H, Aktan Ikiz ZA. (2009). Branching patterns of the popliteal artery and its clinical importance. *Surg Radiol Anat*, 31, 357–362.
9. Tindall AJ, Shetty AA, James KD, Middleton A, Fernando KW. (2006). Prevalence and surgical significance of a high-origin anterior tibial artery. *J Orthop Surg (Hong Kong)*, 14, 13–16.
10. Trotter M. (1940). The level of termination of the popliteal artery in the white and the Negro. *Am J Phys Anthropol*, 27, 109–118.

