



## A CASE REPORT ON DOUBLE PROFUNDA BRACHII ARTERIES OBSERVED DURING ROUTINE DISSECTION IN K. J. SOMAIYA MEDICAL COLLEGE IN MUMBAI

**Shreyal Koli\*, Sharadkumar Pralhad Sawant, Rakhi M More, Shaguphta T Shaikh,  
Shaheen Rizvi, Uma R**

Department of Anatomy, K. J. Somaiya Medical College,  
Somaiya Ayurvihar, Eastern Express Highway, Sion, Mumbai-400 022, India.

Corresponding Author:- **Shreyal Koli**  
E-mail: [shreyal.koli@gmail.com](mailto:shreyal.koli@gmail.com)

Article Info	ABSTRACT
<p><i>Received 15/01/2015</i> <i>Revised 27/01/2015</i> <i>Accepted 12/02/2015</i></p> <p><b>Key words:</b> Profunda Brachii Artery, Brachial Artery, Posterior Circumflex Humeral Artery, Quadrangular Space, Fractures of Humerus, Angiographic Studies.</p>	<p>During the routine dissection of first M.B.B.S. students on a 65 year old donated embalmed male cadaver in the department of Anatomy at K.J.Somaiya Medical College, Sion, Mumbai, India, a double profunda brachii artery was found in the left upper limb. The profunda brachii artery - 1 was originated from the posteromedial aspect of the brachial artery, distal to teres major muscle. The profunda brachii artery - 2 was originated from the posterior circumflex humeral artery in quadrangular space around the surgical neck of the humerus. The profunda brachii artery - 2 divided into the anterior descending (Radial collateral) &amp; the posterior descending (middle collateral) arteries. The profunda brachii artery - 1 gives nutrient artery to the humerus and runs with posterior descending (middle collateral) artery &amp; ends by anastomosing with interosseous recurrent artery behind the lateral epicondyle. The photographs of the variations were taken for proper documentation. The presence of double profunda brachii arteries in the radial groove may result in excessive haemorrhage during fractures. Topographical anatomy of the normal and abnormal variations of the brachial artery are clinically important for surgeons, orthopaedicians and radiologists performing angiographic studies on the upper limb.</p>

### INTRODUCTION

The profunda brachii artery (also known as arteria profunda brachii, deep artery of the arm and the deep brachial artery) provides muscular branches to the triceps before beginning its course around the humerus in company with the radial nerve. It continues to give off twigs to the muscle as it runs this spiral course. It may give off a nutrient artery to the humerus. Deep to the long head of the triceps it regularly gives rise to a deltoid branch that ascends to anastomose with the posterior humeral circumflex artery. This anastomoses accounts for the fact that the profunda brachii sometimes arises from the posterior humeral circumflex, or more rarely, the circumflex arises from the profunda (1). The terminal

branches of the profunda brachii artery are the radial and middle collateral arteries, both of which help to form the anastomoses around the elbow. The radial collateral artery follows the radial nerve through the lateral intermuscular septum and anastomoses in front of the elbow with the radial recurrent artery. The middle collateral artery descends on the triceps, disappears deep to the anconeus, and anastomoses behind the elbow with the interosseous recurrent artery. The present study describes a rare anatomical variant i.e double profunda brachii arteries traversing the radial groove. The knowledge of such anomalies may be of great clinical significance to vascular surgeons, orthopaedicians and radiologists performing



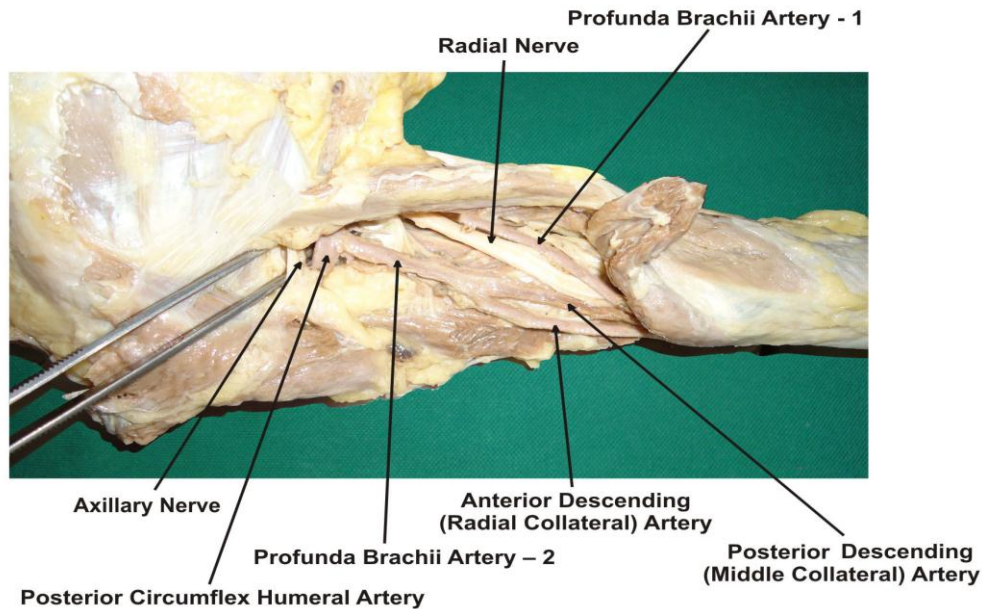
angiographic studies. Appreciation of variations in the upper limb vessels is important due to increasing number of procedures both diagnostic and therapeutic as in breast cancer surgery, flap harvesting and arteriography. The arterial pattern of the upper limb is one of the systems that shows a large number of variations in the adult human body (2).

**CASE REPORT**

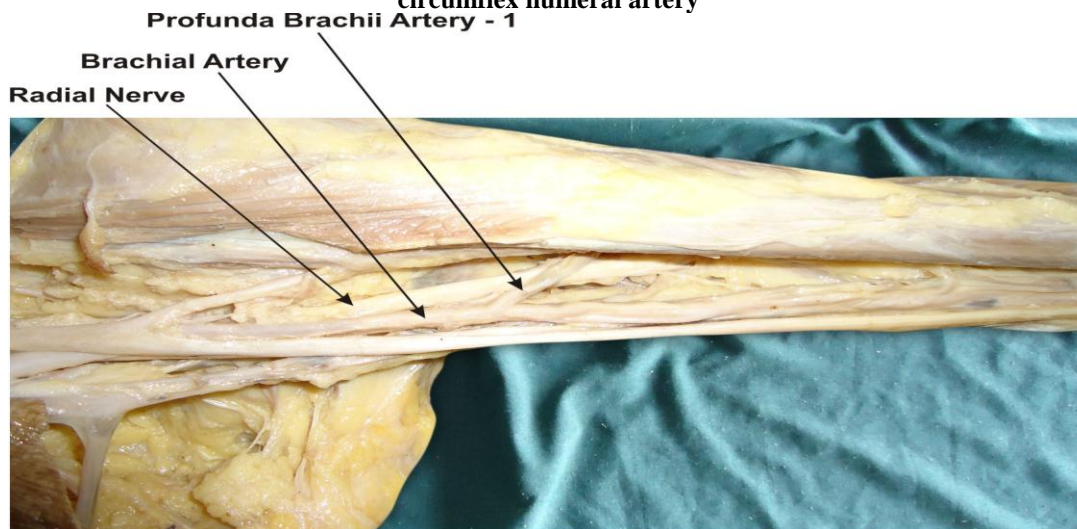
During routine dissection for first M.B.B.S.

students on 65 years donated embalmed male cadaver in the Department of Anatomy, K. J. Somaiya Medical College, we encountered a double profunda brachii artery in left upper limb. The profunda brachii artery - 1 was originating from the posteromedial aspect of the brachial artery, distal to teres major muscle & the profunda brachii artery - 2 was originating from the posterior circumflex humeral artery in the quadrangular space around the surgical neck of the humerus. The photographs of the variations were taken for proper documentation.

**Figure 1. Showing photographic presentation of the profunda brachii artery - 1 originating from the posteromedial aspect of the brachial artery, distal to teres major muscle**



**Figure 2. Showing photographic presentation of the profunda brachii artery - 2 originating from the posterior circumflex humeral artery**



**DISCUSSION**

The profunda brachii, largest branch of the brachial, shows considerable variations in its origin. In 55% of cases, it arises as a single trunk at the level of the

tendon of teres major muscle. It may arise from the axillary artery (22%), as common trunk with the superior ulnar collateral artery in 22%, or as a branch of the posterior circumflex humeral artery (7%) (3). The profunda brachii



artery can originate from a common origin with the posterior circumflex humeral artery, from the axillary artery proximal to the tendon of latissimus dorsi or from the distal portion of the axillary artery (1).

The present study describes a rare anatomical variant i.e double profunda brachii arteries traversing the radial groove. The profunda brachii artery - 1 was originating from the posteromedial aspect of the brachial artery, distal to teres major muscle. The profunda brachii artery - 2 was originating from the posterior circumflex humeral artery in quadrangular space around the surgical neck of the humerus. The profunda brachii artery - 2 divides into the posterior descending (middle collateral) & the anterior descending (Radial collateral) arteries. The profunda brachii artery - 1 runs with posterior descending (middle collateral) artery & ends by anastomosing with interosseous recurrent artery behind the lateral epicondyle. The anterior descending (Radial collateral) artery is the continuation of the profunda brachii artery. It accompanies the radial nerve through the lateral inter muscular septum descending between brachialis & brachioradialis anterior to the lateral epicondyle and ends by anastomosing with the radial recurrent artery. It supplies brachialis, brachioradialis, the radial nerve and few fascio cutaneous perforators.

According to Charles et al there are 7 types of origins for profunda brachii artery. In Type I the profunda brachii artery is the branch of brachial artery, Type Ia the profunda brachii artery originates by 2 separate branches, Type Ib the profunda brachii artery originates by 3 separate branches, In Type II the profunda brachii artery arises as a common trunk with superior ulnar collateral artery, In Type III the profunda brachii artery arises at lower border of teres major so can be considered to be arising from axillary or brachial, In Type IV profunda brachii artery is the branch of 3rd part of axillary artery. In Type V profunda brachii artery arises as a common trunk with posterior circumflex humeral. In Type VI profunda brachii artery arises as a common trunk with subscapular and both circumflex humerals from axillary artery and in Type VII profunda brachii artery is absent (4). The profunda brachii artery - 1 is Charles et al Type I and the profunda brachii artery - 2 is Charles et al Type V.

#### **ANATOMICAL IMPORTANCE**

As the profunda brachii artery arises from the 3<sup>rd</sup> part of the axillary artery in the quadrangular space the contents of the space are:

1. Axillary nerve
2. Posterior circumflex humeral artery
3. Profunda brachii artery

The contents of radial groove in the present case are

1. Radial nerve
2. Profunda brachii artery - 1
3. Profunda brachii artery - 2

#### **SURGICAL IMPORTANCE**

The present paper describes a rare anomaly of the presence of double profunda brachii artery. In the present case, both arteries traversed the radial groove. In case of fractures involving the radial groove of the humerus both the profunda brachii arteries may be involved resulting in excessive hemorrhage. Middle collateral (posterior descending) artery & its fascio cutaneous perforators provide the anatomical basis to elbow skin flap (the lateral arm flap) which are surgically raised for reconstructing areas of tissue missing elsewhere in the body (1).

#### **CLINICAL IMPORTANCE**

Knowledge of anomalous origin is important for surgeons who operate on patients of fracture in the mid-shaft region & surgical neck of humerus (5).

#### **EMBRYOLOGICAL BASIS**

Variations of the arterial pattern of the Upper Limb can be explained on the basis of the embryological development. Developmentally, the Upper Limb bud is initially supplied by a vascular plexus derived from 4 or 5 consecutive intersegmental branches of the dorsal aortae. Very early in the development, the 7th intersegmental artery forms the main artery (axis artery) of the developing Upper Limb bud. The axis artery gives rise to the subclavian, axillary, brachial and interosseous arteries. Other branches are added subsequently to the axis artery. First is the median artery. The ulnar and the radial arteries arise from the axis artery later. Because of this temporal succession of emergence of principle arteries, anomalies of forearm vasculature occur. The arterial pattern of the upper limb develops from an initial capillary plexus by a proximal and distal differentiation, due to maintenance, enlargement and differentiation of certain capillary vessels, and the regression of others. The number of upper limb arterial variations arises through the persistence, enlargement and differentiation of parts of the initial network which would normally remain as capillaries or even regress (6, 7, 8, 9, 10).

#### **CONCLUSION**

The presence of double profunda brachii artery may be clinically important for clinicians, surgeons, orthopaedicians and radiologists performing angiographic studies. Undoubtedly, such variations are important for diagnostic evaluation and surgical management of vascular diseases and injuries. The knowledge of such variations is important; not only for surgeons but also for other medical and nursing staff because intravascular canulations are commonly performed by them. Palpating for a superficial pulse over the canulation site before such a procedure will probably minimize the risk of damaging an artery and subsequent bleeding. This also emphasizes the importance of preoperative arterial doppler or angiography to correctly identify the regional anatomy of the vessels in certain procedures. Otherwise, the presence of the variations may



be unexpectedly encountered during cases of vascularized forearm flap transfer or elective vascular surgery especially in the hand. These variations are compared with the earlier data & it is concluded that variations in branching pattern of axillary artery are a rule rather than exception. Therefore both the normal and abnormal anatomy of the region should be well known for accurate diagnostic interpretation and therapeutic intervention.

#### COMPETING INTERESTS

The authors declare that they have no competing interest.

#### AUTHORS' CONTRIBUTIONS

SK wrote the case report, SPS performed the literature review, SR obtained the photograph for the case,

RMM performed the literature search and RU assisted with writing the paper. STS helped to draft the manuscript. All authors have read and approved the final version manuscript.

#### ACKNOWLEDGEMENT

All the authors wish to convey our sincere thanks to our Dean Dr. Geeta Niyogi Madam for her valuable help, support and inspiration. We are also thankful to Mr. M. Murugan. Authors also acknowledge the immense help received from the scholars whose articles are cited and included in references of this manuscript. The authors are also grateful to authors / editors / publishers of all those articles, journals and books from where the literature for this article has been reviewed and discussed.

#### REFERENCES

1. Standring S. (2005). Gray's Anatomy, 39th Ed, London, Elsevier Churchill Livingstone, 844-45, 856-57.
2. Durgun B, Yucel AH, Kizilkanat ED & Dere F. (2002). Multiple arterial variation of the human upper limb. *Surg Radiol Anat*, 24, 125-8,
3. Tountas CP & Bergman RA. (1993). Anatomic variations of the upper extremities. New York, Churchill Livingstone, 197-210
4. Charles CM, Pen L, Holden HF, Miller RA & Elvis EB. (1931). The origin of the deep brachial artery in American White & American Negro males. *Anatomical Record*, 50, 299-302.
5. Jurjus, A, Sfeir R & Bezirdjian R. (1986). Unusual variation of the arterial pattern the human upper limb. *Anat Rec*, 215, 82-3,
6. Chummy S Sinnatamy. (2001). Last's Anatomy Regional and applied. 10th Ed. New York, Churchill Livingstone, 48-55.
7. Moore KL & Persand TVN. (2003). The Cardio vascular system. In the developing Human, Clinically oriented embryology. 7th Ed. Elsevier, India, 329-80
8. Rodriguez-Niedenfuhr M, Vazquez T, Parkin IG & Sanudo JR. (2003). Arterial patterns of the human upper limb, update of anatomical variations and embryological development. *Eur J Anat*, 7(1), 21-8.
9. Singer E. (1933). Embryological pattern persisting in the arteries of the arm. *Anat Rec*, 55, 403-09,
10. Hamilton WJ & Mossman HW. (1978). Cardiovascular System. In. Human Embryology. 4th Ed. Baltimore, Williams & Wilkins, 268-72.

