



**ADDITIONAL SLIP OF FLEXOR CARPI ULNARIS ASSOCIATED  
WITH VARIANT HIGH DIVISION OF ULNAR NERVE IN FOREARM**

**Dhruv Dhiren Kalawadia<sup>1</sup> and Sharadkumar Pralhad Sawant<sup>2</sup>**

<sup>1</sup>Grant Medical College & Sir J. J. Group of Hospitals, Byculla, Mumbai-400 008, Maharashtra, India.

<sup>2</sup>Department of Anatomy, K. J. Somaiya Medical College, Somaiya Ayurvihar, Sion, Mumbai-400 022, Maharashtra, India.

Corresponding Author:- **Dhruv Dhiren Kalawadia**  
E-mail: [dhruv.kalawadia@gmail.com](mailto:dhruv.kalawadia@gmail.com)

|  |  |
|--|--|
| <p><b>Article Info</b><br/> <i>Received 15/08/2016</i><br/> <i>Revised 27/09/2016</i><br/> <i>Accepted 2/10/2016</i></p> <p><b>Key words:</b> Flexor Carpi Ulnaris, Additional Muscle Slip, Ulnar Nerve, Ulnar Artery, Median Nerve, High Division of Dorsal Branch of Ulnar Nerve, Surgeons, Entrapment, Orthopaedicians, Fractures of Radius or Ulna, Anaesthetist, Pain Management Therapy.</p> | <p><b>ABSTRACT</b><br/>                 During routine dissection, of the right upper limb of a 70 year old donated embalmed male cadaver in the Department of Anatomy, Grant Medical College &amp; Sir J. J. Group of Hospitals, Byculla, Mumbai, we observed an additional muscle slip of flexor carpi ulnaris associated with anomalous high division of dorsal branch of ulnar nerve. The additional belly originated from the lower part of the flexor carpi ulnaris muscle and crossed ulnar nerve, ulnar vessels and median nerve. The additional belly merged with the flexor retinaculum. The ulnar nerve divided into the terminal branches in the upper part of the forearm. However, the distribution of the terminal branches of ulnar nerve was normal in palm. The arterial pattern in the forearm was normal. The variations were unilateral and the left upper limb was normal. The photographs of the additional muscle slip of flexor carpi ulnaris associated with anomalous high division of dorsal branch of ulnar nerve were taken for proper documentation. The awareness of additional muscle slip of flexor carpi ulnaris associated with anomalous high division of dorsal branch of ulnar nerve is clinically important for surgeons dealing with entrapment or compressive neuropathies, orthopaedicians operating on the fractures of radius or ulna or both and anaesthetist performing pain management therapies on the upper limb. These variations are compared with the earlier data &amp; it is concluded that variations in branching pattern of nerves are a rule rather than exception. A lack of knowledge of such type of variations with different patterns might complicate surgical repair and may cause ineffective nerve blockade.</p> |
|--|--|

**INTRODUCTION**

Flexor carpi ulnaris muscle is the most medial muscle of the superficial forearm flexors. It arises by two heads, humeral and ulnar, connected by a tendinous arch. The small humeral head arises from the medial epicondyle via the common tendon. The ulnar head has an extensive origin from the medial margin of the olecranon process and proximal two-thirds of the posterior border of the ulna, an aponeurosis (which it shares with the extensor carpi ulnaris and flexor digitorum profundus), and from the intermuscular septum between it and flexor digitorum superficialis. A thick tendon forms along its anterolateral border in its distal half. The tendon is attached to the

pisiform, and thence prolonged to the hamate and fifth metacarpal bone by pisohamate and pisometacarpal ligaments. Acting with the flexor carpi radialis, it flexes the wrist and acting with the extensor carpi ulnaris it adducts the wrist [1].

Flexor carpi ulnaris muscle is innervated by the ulnar nerve (C7, C8 and T1). The line between the medial humeral epicondyle and the pisiform, along the anterior palmar margin of the muscle, is used as a reference point for locating the ulnar neurovascular bundle. The ulnar artery reaches the muscle in its middle third, whereas the ulnar nerve is covered by the muscle throughout its entire



course running under the tendon in the wrist region [2]. The ulnar artery, the larger of the two terminal branches of the brachial, begins a little below the bend of the elbow, and, passing obliquely downward, reaches the ulnar side of the forearm at a point about midway between the elbow and the wrist. It then runs along the ulnar border to the wrist, crosses the transverse carpal ligament on the radial side of the pisiform bone, and immediately beyond this bone divides into two branches, which enter into the formation of the superficial and deep palmar arches. The ulnar nerve, after descending in the forearm between the flexor digitorum profundus and flexor carpi ulnaris muscles, pierces the deep fascia and enters the wrist through the Guyon's canal. In the distal canal, the ulnar nerve bifurcates into a superficial sensory branch and a deep motor branch, which supplies the hypothenar muscles and then passes across the palm, distributing to other intrinsic hand muscles [3].

**CASE REPORT**

During routine dissection, of the right upper limb of a 70 year old donated embalmed male cadaver in the Department of Anatomy, Grant Medical College & Sir J. J. Group of Hospitals, Byculla, Mumbai, we observed an additional muscle slip of flexor carpi ulnaris associated with anomalous high division of dorsal branch of ulnar nerve. The additional belly originated from the lower part of the flexor carpi ulnaris muscle and crossed ulnar nerve, ulnar vessels and median nerve. The additional belly

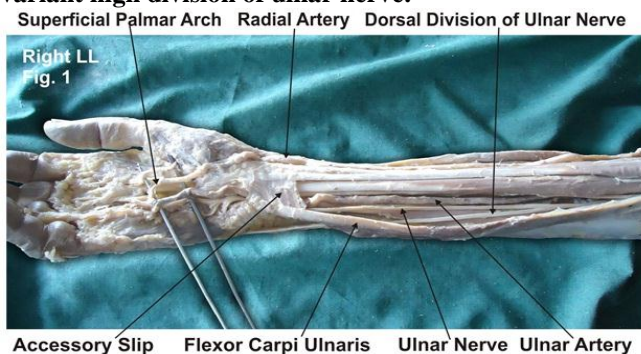
merged with the flexor retinaculum. The ulnar nerve divided into the terminal branches in the upper part of the forearm. However, the distribution of the terminal branches of ulnar nerve was normal in palm. The arterial pattern in the forearm was normal. The variations were unilateral and the left upper limb was normal. The photographs of the additional muscle slip of flexor carpi ulnaris associated with anomalous high division of dorsal branch of ulnar nerve were taken for proper documentation.

**OBSERVATIONS / RESULTS**

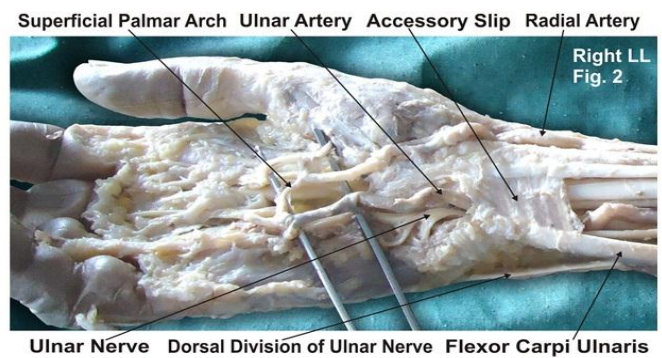
The present variations were found in the right upper extremity. However, the left upper extremity was normal. The specimen revealed an unusual anomalous flexor carpi ulnaris (FCU) muscle. There was an additional muscle slip from the flexor carpi ulnaris in the lower part of anterior compartment of forearm (Fig. 1).

These muscle fibers separated from the lower part of the flexor carpi ulnaris and formed a small muscle belly, which crossed ulnar nerve and vessels, median nerve and ended in a broad aponeurosis which crossed the tendons of flexor digitorum superficialis and merged with the deep fascia and flexor retinaculum (Fig. 2). In the same specimen we also observed ulnar nerve dividing into their terminal branches in the lower part of the forearm. The distribution of the terminal branches of ulnar nerve were normal. The flexor carpi ulnaris muscle and ulnar nerve were studied in detail and were photographed.

**Figure 1 showing the photographic presentation of an additional muscle slip from the flexor carpi ulnaris in the lower part of anterior compartment of forearm and variant high division of ulnar nerve.**



**Figure 2 showing the photographic presentation of variant small muscle belly of flexor carpi ulnaris crossing ulnar nerve, vessels and median nerve.**



**DISCUSSION**

Anatomical variations of the flexor carpi ulnaris that have been reported previously are (a) variations in musculotendinous junction of the flexor carpi ulnaris muscle, (b) variant flexor carpi ulnaris causing ulnar nerve compression [4], (c) an additional slip of flexor carpi ulnaris (Bergman et al., 1988) as in the present case. The FCU acts as an anatomical guideline for finding the neurovascular bundle (ulnar nerve, ulnar artery and accompanying venae comitantes), it can be easily palpated in its distal course if the wrist is flexed and adducted.

The present variation need to be taken into account when interpreting ultrasound and MR images, as well as during dissection of the ulnar neurovascular bundle when using FCU as a guideline. The flexor carpi ulnaris is a useful local muscle flap in the forearm and elbow. It is, however, an important palmar flexor and ulnar deviator of the wrist, and functional loss may arise from the use of this muscle in its entirety. The flexor carpi ulnaris is made up of two distinct neuromuscular compartments. This arrangement allows for splitting of the muscle and the



potential use of the larger ulnar compartment as a local muscle flap while maintaining the humeral compartment as an ulnar deviator and palmar flexor of the wrist [5]. After multiple efforts to heal an infected nonunion of the proximal ulna, flexor carpi ulnaris muscle has been used as a pedicle flap to improve blood supply and soft tissue coverage at the nonunion site and observed promoted bone healing and restoration of useful elbow function [6]. Entrapment or compressive neuropathies are important and wide spread debilitating clinical problems. They are caused frequently as the nerve passes through a fibrous tunnel, or an opening in fibrous or muscular tissue. The most common is the median nerve entrapment in the wrist leading to carpal tunnel syndrome.

As in the present case, the crossing of accessory belly of the flexor carpi ulnaris muscle over the ulnar nerve and median nerve and compressing them might lead to numbness and tingling in the hand. This variation may be clinically important because symptoms of median nerve compression arising from similar variations are often confused with more common causes, such as, radiculopathy and carpal tunnel syndrome [7]. The knowledge of course and distribution of ulnar nerve can assist the surgeon in the diagnosis and treatment of conditions associated with the ulnar aspect of the hand. Recognition and diagnosis of this problem will help ensure timely and effective management of the more common pain syndromes.

#### CLINICAL SIGNIFICANCE

The anatomical variation described here has practical implications, since injury to the ulnar nerve in the forearm would, in this case, have caused unexpected loss of cutaneous sensation on the dorsum of the hand. The crossing of accessory belly of the flexor carpi ulnaris muscle over the ulnar nerve and the median nerve might compress them leading to numbness and tingling in the

hand. The knowledge of this variation may be clinically important because the symptoms are similar to those of the carpal tunnel syndrome.

#### CONCLUSION

The awareness of additional muscle slip of flexor carpi ulnaris associated with anomalous high division of dorsal branch of ulnar nerve is clinically important for surgeons dealing with entrapment or compressive neuropathies, orthopaedicians operating on the fractures of radius or ulna and anaesthetist performing pain management therapies on the upper limb. These variations are compared with the earlier data & it is concluded that variations in branching pattern of nerves are a rule rather than exception. A lack of knowledge of such type of variations with different patterns might complicate surgical repair and may cause ineffective nerve blockade.

#### ACKNOWLEDGEMENT

Authors wish to convey our sincere thanks to Dr. T. P. Lahane for his valuable help, support and inspiration. Authors also acknowledge the immense help received from the scholars whose articles are cited and included in references of this manuscript. The authors are also grateful to authors / editors / publishers of all those articles, journals and books from where the literature for this article has been reviewed and discussed.

#### COMPETING INTERESTS

The authors declare that they have no competing interests.

#### AUTHORS' CONTRIBUTIONS:

DDK wrote the case report, performed the literature review & obtained the photograph for the study. SPS performed the literature search and assisted with writing the paper. Authors have read and approved the final version manuscript.

#### REFERENCES

1. Williams PL, Warwick R, Dyson M, Bannister LH. (2005). *Editors Gray's Anatomy*. 39<sup>th</sup> Edition. Edinburgh-London: Churchill Livingstone; pp. 877.
2. Romanes G J. (2003). *Cunningham's Manual of Practical Anatomy*, Upper and lower limbs Vol.1. 15th edn. Oxford University Press, 74-75.
3. Bergman RA, Thomson SA, Afifi AK & Saadesh FA. (1988). Compendium of human anatomic variations. *Urban Schwarzenberg, Baltimore – Munich*, 1 3.
4. Grechenig W, Clement H, Egner S, Tesch NP, Weiglein A & Peicha G. (2000). Musculo-tendinous junction of the flexor carpi ulnaris muscle. An anatomical study. *Surg. Radiol. Anat*, 22, 255-60.
5. Lingaraj K, Lim AY, Puhaindran ME & Kumar PV. (2007). The split flexor carpi ulnaris as a local muscle flap. *Clin Orthop. Relat. Res*, 455, 262-266.
6. Meals RA. (1989). The use of a flexor carpi ulnaris muscle flap in the treatment of an infected nonunion of the proximal ulna. A case report. *Clin. Orthop. Relat. Res*, 240, 168- 72.
7. Al-Qattan MM & Duerksen F. (1992). A variant of flexor carpi ulnaris causing ulnar nerve compression. *J. Anat*, 180, 189-190.

