



A CASE REPORT ON VARIANT TERMINATION OF SCIATIC NERVE

Amalsh S. Honnekeri^{1*}, Sharadkumar P. Sawant², Shaheen Rizvi³

¹First MBBS, ²Professor and Head, ³Assistant Lecturer, Department of Anatomy, K. J. Somaiya Medical College, Somaiya Ayurvihar, Eastern Express Highway, Sion, Mumbai-400 022, Maharashtra, India.

ABSTRACT

The sciatic nerve is the thickest nerve in the body. It leaves the pelvis via the greater sciatic foramen below piriformis and descends between the greater trochanter and ischial tuberosity, along the back of the thigh, dividing into the tibial and common peroneal (fibular) nerves at a varying level proximal to the knee. During routine dissection for the first MBBS students, I observed an unusual termination of the sciatic nerve on the back of the left thigh in the middle of the popliteal fossa of a 70 year old, donated embalmed male cadaver in the Department of Anatomy, K.J. Somaiya Medical College, Sion, Mumbai, India. The sciatic nerve terminated in the middle of the popliteal fossa into the tibial nerve, common peroneal (fibular) and the sural nerve. The photographs of the three branches of the sciatic nerve were taken for proper documentation and for ready reference. **Conclusion:** The trifurcation of the sciatic nerve is very rare. The knowledge of low level of termination of sciatic nerve is important for clinicians and surgeons. Clinically, the sural nerve is widely used for both diagnostic (biopsy and nerve conduction velocity studies) and therapeutic purposes (nerve grafting). Thus, a detailed knowledge of the anatomy of the sural nerve and its contributing nerves are important in carrying out these and other procedures.

Key words: Sciatic Nerve, Trifurcation, Tibial Nerve, Common Peroneal, Lateral Sural Cutaneous Nerve, Popliteal Fossa, Sural Nerve.

Access this article online

Home page:

<http://www.mcmed.us/journal/ijacr>

DOI:

<http://dx.doi.org/10.21276/ijacr.2017.4.3.23>

Quick Response code



Received:25.02.17

Revised:12.03.17

Accepted:25.03.17

INTRODUCTION

The sciatic nerve is 2 cm wide at its origin and is the thickest nerve in the body. It leaves the pelvis via the greater sciatic foramen below piriformis and descends between the greater trochanter and ischial tuberosity, along the back of the thigh, dividing into the tibial and common peroneal (fibular) nerves at a varying level proximal to the knee. Superiorly it lies deep to the gluteus maximus, resting first on the posterior ischial surface with the nerve

to the quadratus femoris lying between them. It then crosses posterior to the obturator internus, the gemelli and quadratus femoris, separated by the latter from obturator externus and the hip joint. It is accompanied medially by the posterior femoral cutaneous nerve and the inferior gluteal artery. More distally it lies behind adductor magnus and is crossed posteriorly by the long head of biceps femoris.

Articular branches arise proximally to supply the hip joint through its posterior capsule, these are sometimes derived directly from the sacral plexus. Muscular branches are distributed to biceps femoris, semitendinosus, semimembranosus and the ischial part of adductor magnus.

Corresponding Author

Amalsh S. Honnekeri

Department of Anatomy, K.J. Somaiya Medical College, Somaiya Ayurvihar, Eastern Express Highway, Sion, Mumbai-400 022, Maharashtra, India.

Email: amalshhonnekeri@gmail.com

The point of division of the sciatic nerve into the tibial and the common peroneal nerve is very variable. The common site is at the junction of the middle and lower thirds of the thigh, near the apex of the popliteal fossa. The division may occur at any level above this, through rarely below it. It is not uncommon for the major components to leave the sacral plexus separately, in which case the common peroneal component usually passes through piriformis at the greater sciatic notch while the tibial component passes below the muscle [1].

The sciatic nerve supplies the knee flexors and all the muscles below the knee, so that a complete palsy of the sciatic nerve results in a flail foot and severe difficulty in walking. This is rare and usually related to trauma. The nerve is vulnerable in posterior dislocation of the hip. As it leaves the pelvis it passes either behind piriformis or sometimes through the muscle and at that point it may become entrapped (the piriformis syndrome; this is a common anatomical variant but an extremely rare entrapment neuropathy). External compression over the buttock (e.g. in patients who lie immobile on a hard surface for a considerable length of time) can injure the nerve. The most common cause of serious sciatic nerve injury (and consequent major medicolegal claims) is iatrogenic. It may be damaged in misplaced therapeutic injections into gluteus maximus. The safe zone for deep intramuscular injections here is the upper outer quadrant of the buttock. Sciatic nerve palsy occurs after total hip replacement or similar surgery in 1% of cases. This can be due to sharp injury burning from bone cement, traction from instruments, manipulation of the hip, inadvertent lengthening of the femur, or haematoma surrounding the nerve or within its soft tissue coverings. The patient has a foot drop and a high stepping gait. The sciatic nerve bifurcates into two major divisions (tibial and common peroneal), most commonly at the lower part of the posterior compartment of the thigh. Several authors have reported variations on its division into the tibial and common peroneal nerve from the sacral plexus to the lower part of the popliteal space. These anatomical variations may

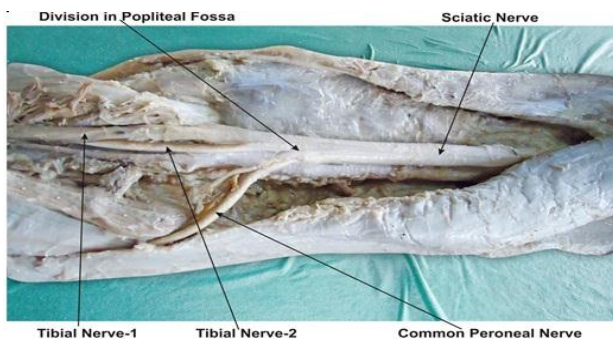
contribute to piriformis syndrome, sciatica, coccygodynia and muscle atrophy. This should be taken into account by clinicians who are planning interventions around the sciatic nerve and its division in the lower extremity. Higher level of the sciatic nerve division is a relatively frequent phenomenon [2].

The sural nerve (short saphenous nerve), is a sensory nerve formed by the union of the medial sural cutaneous with the peroneal anastomotic branch of the lateral sural cutaneous nerve, passes downward near the lateral margin of the tendo calcaneus, lying close to the small saphenous vein, to the interval between the lateral malleolus and the calcaneus. It runs forward below the lateral malleolus, and is continued as the lateral dorsal cutaneous nerve along the lateral side of the foot and little toe (via a dorsal digital nerve), communicating on the dorsum of the foot with the intermediate dorsal cutaneous nerve, a branch of the superficial peroneal. In the leg, its branches communicate with those of the collateral branches of the common tibial, and common fibular nerve [1].

Case Report:

During routine dissection for the first MBBS students, I observed an unusual termination of the sciatic nerve on the back of the left thigh in the middle of the popliteal fossa of a 70 year old, donated embalmed male cadaver in the Department of Anatomy, K.J. Somaiya Medical College, Sion, Mumbai, India. The sciatic nerve terminated in the middle of the popliteal fossa by giving 3 branches. The three branches given were the tibial, common peroneal and sural nerves [2] (Fig 1). The common peroneal nerve was reduced in size due to the sural nerve, which was almost as thick as the common peroneal nerve. The sural nerve continues down the leg on the posterior-lateral side, then posterior to the lateral malleolus where it runs deep to the fibularis tendon sheath and reaches the lateral tuberosity of the fifth toe. The photographs of the trifurcation of the sciatic nerve were taken for proper documentation and for ready reference.

Figure 1. showing the photographic presentation of the sciatic nerve terminating in the middle of the popliteal fossa by giving three branches. The three branches given were the tibial nerve-1, common peroneal and tibial nerve-2 [sural nerve]. Common peroneal nerve reduced in size due to the sural nerve, which was almost as thick as the common peroneal nerve.



DISCUSSION

During embryological development at the base of the limb bud, the nerves contributing to the lower limb forms two plexuses (lumbar and sacral). Later, as the elements from each of these plexuses grow out into the limb, they are subdivided into dorsal and ventral components, for the dorsal and ventral musculatures. The sciatic nerve is formed when the large dorsal component of the sacral plexus (common fibular nerve) and the ventral component (tibial nerve) moves downward close together [4].

A number of variations in the course and distribution of the sciatic nerve have been reported. Bifurcation into its two major divisions (common peroneal and tibial) may occur anywhere between the sacral plexus and the lower part of the thigh. The two terminal branches of the sciatic may arise directly from the sacral plexus [3]. Pokorný et al, Ugrenović et al, Saleh et al studied the different level of division of the sciatic nerve [7,8,9]. When the sciatic nerve divides in the pelvis, the common peroneal nerve usually pierces the piriformis muscle. The common peroneal nerve passes either through the piriformis or above the piriformis [5,6]. The entire sciatic nerve may pass through the piriformis causing the sciatica [7]. The tibial nerve passing deep and common peroneal nerve passing superficial to the superior gemellus has been found in literature [8]. The trifurcation of sciatic nerve into tibial, common peroneal and lateral cutaneous nerve of calf has been observed [10] but the trifurcation of sciatic nerve into tibial, common peroneal and sural nerves is not documented in literature. Normally the sural nerve is formed by medial sural cutaneous nerve arising from the tibial nerve and lateral sural cutaneous nerve from the common peroneal nerve. The knowledge of these variations is important because the sural nerve is the most frequently used sensory nerve in nerve transplantation. Reports on variations and surgical application of the variations of sural and peroneal communicating nerve are available in literature [11]. The present case of trifurcation of the sciatic nerve is important to surgeons who do the popliteal block for leg surgery, because high divisions of sciatic nerve may lead to failure of popliteal block anesthesia [12]. The thick sural nerve in this case is ideal for nerve grafts. Since the division of sciatic nerve is very low, its branches may interfere in knee surgery. The knowledge of the trifurcation of the sciatic nerve, seen in the present case extremely important to the surgeons dealing with popliteal aneurysms. Although entrapment of the sural nerve is a rare condition, the resultant pain can be debilitating for patients. A thorough knowledge of the trajectory of the nerve is essential for establishing a diagnosis, as well as for treatment. [13,14,15].

REFERENCES

1. Standring S. (2005) *Gray's Anatomy*, 39th Ed, London: Elsevier Churchill Livingstone, pp 1456.

Clinical significance:

The trifurcation of the sciatic nerve is important to the surgeons who perform the popliteal block for leg surgery, because high divisions of sciatic nerve may lead to failure of popliteal block anesthesia [13]. The sural nerve serves a purely sensory function, and therefore its removal results in only a relatively trivial deficit. For this reason, it is often used for nerve biopsy, as well as the donor nerve when a nerve graft is performed. The sural nerve is the most frequently used sensory nerve in nerve transplantations. It is either transplanted alone or together with the other elements of the neurovascular stalk within the superficial sural flap [14]. Clinically, the sural nerve is widely used for both diagnostic (biopsy and nerve conduction velocity studies) and therapeutic purposes (nerve grafting). Thus, a detailed knowledge of the anatomy of the sural nerve and its contributing nerves are important in carrying out these and other procedures [15].

CONCLUSION

The existence of such variations should be kept in mind by the surgeons dealing with popliteal aneurysms, by the orthopaedicians dealing with fracture of the femur, the radiologists while doing radio-diagnostic procedures e.g. CT scan, MRI of the thigh, by anesthetists performing pain management and also by the physiotherapists.

Acknowledgement:

Authors are thankful to Dean Dr. Vinayak Sabnis Sir for his support and encouragement. Authors are also thankful to Mr. M. Murugan, Mrs. Pallavi Kadam, Mr. Shivaji Dalvi, Mr. Kishor Rangle, Mr. Sankush Adkhale, Mr. Sanjay Shinde, Mr. Kishor Baradiya and Mr. Panduj for their help. Authors also acknowledge the immense help received from the scholars whose articles are cited and included in references of this manuscript. The authors are also grateful to authors / editors / publishers of all those articles, journals and books from where the literature for this article has been reviewed and discussed.

Conflict of Interest

The authors declare that they have no conflict of interest.

Statement of Human and Animal Rights

All procedures performed in human participants were in accordance with the ethical standards of the institutional research committee and with the 1964 Helsinki declaration and its later amendments or comparable ethical standards. This article does not contain any studies with animals performed by any of the authors.

2. Paval J, Nayak S. (2006) A case of bilateral high division of sciatic nerve with a variant inferior gluteal nerve. *Neuroanatomy*, 5, 33-4.
3. Moore KL, Dalley AF. (1999) *Clinically Oriented Anatomy*. 4th ed. Philadelphia: Lippincott Williams & Wilkins, 347-560.
4. Ndiaye A, Sakho Y, Fall F, Dia A, Sow ML. (2004) Sciatic nerve in gluteal portion: application of sciatic nerve post injection lesion. *Morphologie*, 88, 135-8.
5. Babinski MA, Machado FA, Costa WS. (2003) A rare variation in the high division of the sciatic nerve surrounding the superior gemellus muscle. *Eur J Morphol*, 41, 41-2.
6. Pokorný D, Jahoda D, Veigl D, Pinskerová V, Sosna A. (2006) Topographic variations of the relationship of the sciatic nerve and the piriformis muscle and its relevance to palsy after total hip arthroplasty; *Surg Radiol Anat*, 28, 88-91.
7. Saleh HA, El-fark MM, Abdel-Hamid GA. (2009) Anatomical variation of sciatic nerve division in the popliteal fossa and its implication in popliteal nerve block. *Folia Morphol (Warsz)*, 68, 256-9.
8. Ugrenovic S, Jovanovic I, Krstic V, Stojanovic V, Vasovic L, Antic S, Pavlovic S. (2005) The level of the sciatic nerve division and its relations to the piriform muscle. *Vojnosanit Pregl*, 62, 45-49.
9. Chen WS. (1994) Bipartite piriformis muscle: an unusual cause of sciatic nerve entrapment. *Pain*, 58, 269-272.
10. Babinski MA, Machado FA, Costa WS. (2003) A rare variation in the high division of the sciatic nerve surrounding the superior gemellus muscle. *Eur. J. Morphol*, 41, 41-42
11. Nayak S. (2008) An unusual case of trifurcation of the sciatic nerve. *Neuroanatomy*, 5, 6-7.
12. Benjamim AC, Tuma Junior P, Grillo MA, Ferreira MC. (1995) *Surgical anatomy of the sural nerve*. *Rev. Hosp. Clin. Fac. Med. Sao. Paulo*, 50, 25-29.
13. Vloka JD, Hadzić A, April E, Thys DM. (2001) The division of sciatic nerve in popliteal fossa: anatomical implications for popliteal nerve blockade. *Anesth Analg*, 92, 215-7.
14. Bryan BM 3rd, Lutz GE, O'Brien SJ. (1999) Sural nerve entrapment after injury to the gastrocnemius: a case report. *Arch. Phys. Med. Rehabil.*, 80, 604-606.
15. Nayak SB. Sural nerve and short saphenous vein entrapment – a case report (2005) *Indian J. Plast. Surg*, 38, 171-172.

Cite this article:

Amalesh S. Honnekeri, Sharadkumar P. Sawant, Shaheen Rizvi. A case report on variant termination of sciatic nerve. *International Journal Of Advances In Case Reports*, 4(3), 2017, 181-184.

DOI: <http://dx.doi.org/10.21276/ijacr.2017.4.3.23>



Attribution-NonCommercial-NoDerivatives 4.0 International