



A CADAVERIC CASE REPORT ON VARIANT ARTERIAL PATTERN ON THE DORSUM OF FOOT

Divya A. Vaidya^{1*}, Sharadkumar P. Sawant², Shaheen Rizvi³

¹First MBBS, ²Professor and Head, ³Assistant Lecturer, Department of Anatomy, K. J. Somaiya Medical College, Somaiya Ayurvihar, Eastern Express Highway, Sion, Mumbai-400 022, Maharashtra, India.

ABSTRACT

During routine dissection, of the lower limb of a 70 year old donated embalmed male cadaver in the Department of Anatomy, at K.J. Somaiya Medical College, Sion, Mumbai, India, I observed two dorsalis pedis arteries arising from the anterior tibial artery in the lower part of the leg. Both the dorsalis pedis arteries travelled together on the dorsum of the foot up to the proximal part of the first intermetatarsal space. The pattern of nerves in the leg was normal. The variation was unilateral. The photographs of the double dorsalis pedis arteries of right lower limb were taken for proper documentation. Clinical Significance. The awareness of knowledge of any variation in dorsalis pedis arteries is clinically important for surgeons, plastic surgeons and orthopaedicians because the dorsalis pedis artery is used to record peripheral arterial pulsation. Non-healing diabetic foot ulcers which are challenging problems for surgeons, are commonly dealt with by musculocutaneous flaps based on the branches of dorsalis pedis artery. These musculocutaneous flaps are commonly used in reconstructive surgeries. A lack of knowledge of variations the dorsalis pedis arteries might complicate surgical repair.

Key words: Anterior Tibial Artery, Double Dorsalis Pedis Artery, Surgeons, Orthopaedicians, Peripheral Pulse, Musculocutaneous Flap.

Access this article online

Home page:

<http://www.mcmed.us/journal/ijacr>

DOI:

<http://dx.doi.org/10.21276/ijacr.2017.4.3.6>

Quick Response code



Received:25.02.17

Revised:12.03.17

Accepted:25.03.17

INTRODUCTION

The dorsalis pedis artery is also called as arteria dorsalis pedis. It is the continuation of the anterior tibial artery and passes forward from the ankle-joint along the medial side of the dorsum of the foot to the proximal part of the first intermetatarsal space, where it divides into two branches, the first dorsal metatarsal and the deep plantar arteries. The dorsal artery of the foot may be larger than usual, to compensate for a deficient plantar artery; or its terminal branches to the toes may be absent, the toes then being supplied by the medial plantar; or its place may be

taken altogether by a large perforating branch of the peroneal artery. This artery frequently curves laterally between the middle of the ankle and the back part of the first interosseous space. The branches of the dorsalis pedis artery are the lateral tarsal, arcuate, medial tarsal, first dorsal metatarsal and deep plantar arteries. The lateral tarsal artery arises from the dorsalis pedis, as that vessel crosses the navicular bone; it passes in an arched direction laterally, lying upon the tarsal bones, and covered by the extensor digitorum brevis; it supplies this muscle and the articulations of the tarsus, and anastomoses with branches of the arcuate, anterior lateral malleolar and lateral plantar arteries, and with the perforating branch of the peroneal artery. The medial tarsal arteries are two or three small

Corresponding Author

Divya A. Vaidya

Department of Anatomy, K.J. Somaiya Medical College, Somaiya Ayurvihar, Eastern Express Highway, Sion, Mumbai-400 022, Maharashtra, India.

Email: divyavaidya13@gmail.com

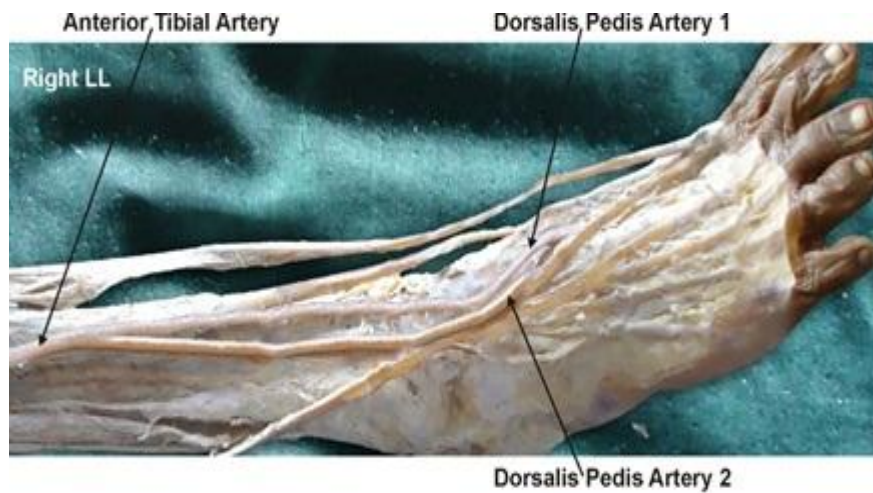
branches which ramify on the medial border of the foot and arises a little anterior to the lateral tarsal artery; it passes laterally, over the bases of the metatarsal bones, beneath the tendons of the extensor digitorum brevis, its direction being influenced by its point of origin; and its anastomoses with the lateral tarsal and lateral plantar arteries. This vessel gives off the second, third, and fourth dorsal metatarsal arteries, which run forward upon the corresponding dorsal Interossei; in the clefts between the toes, each divides into two dorsal digital branches for the adjoining toes. [1]. At the proximal parts of the interosseous spaces these vessels receive the posterior perforating branches from the plantar arch, and at the distal parts of the spaces they are joined by the anterior perforating branches, from the plantar metatarsal arteries. The fourth dorsal metatarsal artery gives off a branch which supplies the lateral side of the fifth toe. The first dorsal metatarsal artery runs forward on the first Interosseous dorsalis, and at the cleft between the first and second toes divides into two branches, one of which passes beneath the tendon of the extensor hallucis longus, and is distributed to the medial border of the great toe; the other bifurcates to supply the adjoining sides of the great and second toes. The deep plantar artery descends into the sole of the foot, between the two heads of the first interosseous dorsalis, and unites with the termination of the lateral plantar artery, to complete the plantar arch. It sends a

join the medial malleolar network. The arcuate artery branch along the medial side of the great toe, and is continued forward along the first interosseous space as the first plantar metatarsal artery, which bifurcates for supplying the adjacent sides of the great and second toes [2].

CASE REPORT

During routine dissection, of the lower limb of a 70 year old donated embalmed male cadaver in the Department of Anatomy, at K.J. Somaiya Medical College, Sion, Mumbai, India, I observed two dorsalis pedis arteries arising from the anterior tibial artery in the lower part of the leg. Both the dorsalis pedis arteries travelled together on the dorsum of the foot up to the proximal part of the first intermetatarsal space. The anterior tibial artery was exposed through a longitudinal incision in lateral calf over the mid portion of anterior compartment. The tibialis anterior and extensor hallucis longus muscles were fused, and neurovascular bundle was exposed between these and the extensor digitorum muscle; The anterior tibial artery, its paired tibial veins, and the tibial nerve were dissected along the surface of the interosseous membrane and the two dorsalis pedis arteries were observed. The pattern of nerves in the leg was normal. The variation was unilateral. The photographs of the double dorsalis pedis arteries were taken for proper documentation.

Figure 1 showing photographic presentation of two dorsalis pedis arteries arising from the right anterior tibial artery.



DISCUSSION

In humans, the dorsalis pedis artery (dorsal artery of foot), is a blood vessel of the lower limb that carries oxygenated blood to the dorsum of the foot. It arises at the anterior aspect of the ankle joint and is a continuation of the anterior tibial artery. It terminates at the proximal part of the first intermetatarsal space, where it divides into two branches, the first dorsal metatarsal artery and the deep plantar artery. Along its course, it is accompanied by a

deep vein, the dorsalis pedis vein. In the foot it gives off medial and lateral tarsal arteries, arcuate artery and first dorsal metatarsal artery.

The dorsalis pedis artery pulse can be palpated readily lateral to extensor hallucis longus tendon (or medial to extensor digitorum longus tendon) on the dorsum of the foot, distal to the dorsal most prominence of the navicular bone which serves as a reliable landmark for

palpation [3]. It is often examined, by physicians, when assessing whether a given patient has peripheral vascular disease. It is absent, unilaterally or bilaterally, in 2-3 % of young healthy individuals. A number of anomalies of dorsalis pedis artery have been noted by anatomists and surgeons.

The dorsalis pedis artery has been found to arise from the perforating branch of peroneal artery. The dorsalis pedis artery has been found to divide into two terminal branches 3cm distal to its origin. The dorsalis pedis artery has been found to be a continuation of peroneal artery in 8% cases [4].

In the present study two dorsalis pedis arteries were seen arising from the anterior tibial artery. Both the arteries ran together side by side to reach the first intermetatarsal space, The dorsalis pedis artery – 1, dipped in the proximal aspect of the space and the dorsalis pedis artery – 2, continued as 1st dorsal metatarsal artery. The aberrant arteries or anomalous course of the arteries of the lower limb can be attributed to their development.

Developmental Basis

The axis artery of the lower limb develops from the 5th lumbar intersegmental artery. The embryonic blood vessels acquire a plexiform appearance in the foot. The dorsalis pedis artery is a constant embryonic vessel that plays an important role in the normal arterial morphogenesis of the lower limb. The tiny blood vessels derived from the blood islands in the 3rd and 4th week of development merge with each other forming a continuous network of fine vessels. New vessels buds out from the walls grow out and get canalized to form newer vessels. These newer vessels of the neighbouring areas join to form a closed network. The adult arterial pattern of the lower limb develops from multiple and plexiform sources of vessels, and emergence of anastomoses between these vessels, which is followed by regression of some channels depending on the functional dominance. This explains why the anomalies of the blood vessels of the limbs not only present as divergence in the origin and course but also as supernumerary vessels in the region [5,6].

Clinical significance

The knowledge of any variation in the course and distribution of the dorsalis pedis artery is clinically important because the dorsalis pedis artery is used to record peripheral arterial pulsation. Since the dorsalis pedis

artery serves as an important pedicle for most of the reconstructive surgeries of the foot, the knowledge about the aberration of the usual anatomic pattern of origin, branching and anastomosing patterns of the artery are of prime importance to the general surgeons, orthopedic surgeons, plastic and reconstructive surgeons who deal with this area. The change in lifestyle in this 21st century has increased the number of diabetic patients. Long standing and neglected cases of Diabetes end up with diabetic neuropathy and diabetic foot ulcers. These non-healing diabetic foot ulcers are challenging problems, for surgeons, which are commonly dealt with by musculocutaneous flaps based on the branches of dorsalis pedis artery [7].

CONCLUSION

The knowledge of double dorsalis pedis artery is clinically important for surgeons operating on non-healing diabetic foot ulcers using musculocutaneous flaps to improve blood supply and soft tissue coverage based on the branches of dorsalis pedis artery. A lack of knowledge of such type of variations might complicate surgical repair.

ACKNOWLEDGEMENT:

Authors are thankful to Dean Dr. Vinayak Sabnis Sir for his support and encouragement. Authors are also thankful to Mr. M. Murugan, Mrs. Pallavi Kadam, Mr. Shivaji Dalvi, Mr. Kishor Rangle, Mr. Sankush Adkhale, Mr. Sanjay Shinde, Mr. Kishor Baradiya and Mr. Panduj for their help. Authors also acknowledge the immense help received from the scholars whose articles are cited and included in references of this manuscript. The authors are also grateful to authors / editors / publishers of all those articles, journals and books from where the literature for this article has been reviewed and discussed.

CONFLICT OF INTEREST

The authors declare that they have no conflict of interest.

STATEMENT OF HUMAN AND ANIMAL RIGHTS

All procedures performed in human participants were in accordance with the ethical standards of the institutional research committee and with the 1964 Helsinki declaration and its later amendments or comparable ethical standards. This article does not contain any studies with animals performed by any of the authors.

REFERENCES

1. Williams PL, Warwick R, Dyson M & Bannister LH. (2005). Gray's Anatomy. 39th Edition Edinburgh, Churchill Livingstone, 1540.
2. Huber JF, (1941). The arterial network supplying the dorsum of foot. *Anat Res*, 80, 373.
3. Mowlavi A, Whiteman J, Wilhelmi BJ, Neumeister MW, McLafferty R. (2002). Dorsalis pedis arterial pulse, palpation using a bony landmark. *Postgraduate Medical Journal* 78 (926), 746-747.
4. Bailleul JP, Olivez PR, Mestdag H. (1984). Desgra-phical anatomy of the dorsalis pedis artery of the foot. *Bull Association of Anatomy (Nancy)*, 68, 15-25.

5. Maral TM, Celik TC. (1994). Anomalous dorsalis pedis artery. *Surg Radiol Anat*, 6, 319-323.
6. Sadler TW, In, Langman's Medical Embryology. (1985). 5th Edition, William and Wilkins, 68-69.
7. Robertson, GS, Ristic, CD, Bullen, BR. (1990). The incidence of congenitally absent foot pulses. *Annals of the Royal College of Surgeons of England*, 72(2), 99-100.

Cite this article:

Divya A. Vaidya, Sharadkumar P. Sawant, Shaheen Rizvi. A Cadaveric Case Report On Variant Arterial Pattern On The Dorsum Of Foot. *International Journal Of Advances In Case Reports*, 4(3), 2017, 117-120.

DOI: <http://dx.doi.org/10.21276/ijacr.2017.4.3.6>



Attribution-NonCommercial-NoDerivatives 4.0 International