



## VARIANT LOW LEVEL DIVISION OF THE SCIATIC NERVE AT KNEE LEVEL – A CASE REPORT

Khushboo C. Arora<sup>1\*</sup>, Sharadkumar P. Sawant<sup>2</sup>, Shaheen Rizvi<sup>3</sup>

<sup>1</sup>First MBBS, <sup>2</sup>Professor and Head, <sup>3</sup>Assistant Lecturer, Department of Anatomy, K. J. Somaiya Medical College, Somaiya Ayurvihar, Eastern Express Highway, Sion, Mumbai-400 022, Maharashtra, India.

### ABSTRACT

During routine dissection, of the right lower limb of 70 years old donated embalmed male cadaver in the Department of Anatomy, K.J. Somaiya Medical College, Sion, Mumbai, India, we observed the low level division of the sciatic nerve in the popliteal fossa. The gluteal region, back of thigh and leg of the lower limb was dissected meticulously to record the course of the tibial and common peroneal nerve. The further course of the tibial and common peroneal nerve was normal. The pattern of vessels in the lower limb was normal. The variation was unilateral and the left lower limb was normal. The photographs of the division of the sciatic nerve was taken for proper documentation. In sciatic nerve neuropathies, the extent of neurological deficits depends on the level of the sciatic nerve division. The sciatic nerve divided into the tibial and the common peroneal components at a lower level can result in the involvement of both the divisions in sciatic neuropathy. There is no failure of popliteal block anaesthesia in case of the low level division of the sciatic nerve.

**Key words:** Sciatic nerve, Gluteal region, Piriformis, Sciatic nerve block, Piriformis syndrome, Sciatica.

Access this article online

Home page:

<http://www.mcmed.us/journal/ijacr>

DOI:

<http://dx.doi.org/10.21276/ijacr.2017.4.3.20>

Quick Response code



Received:25.02.17

Revised:12.03.17

Accepted:25.03.17

### INTRODUCTION

The sciatic nerve is 2 cm wide at its origin and is the thickest nerve in the body. It leaves the pelvis via the greater sciatic foramen below piriformis and descends between the greater trochanter and ischial tuberosity, along the back of the thigh, dividing into the tibial and common peroneal or fibular nerves at a varying level proximal to the knee. Superiorly it lies deep to the gluteus maximus, resting first on the posterior ischial surface with the nerve to quadratus femoris between them. It then crosses posterior to obturator internus, the gemelli and quadratus femoris, separated by the latter from obturator externus and

the hip joint. It is accompanied medially by the posterior femoral cutaneous nerve and the inferior gluteal artery. More distally it lies behind the adductor magnus and is crossed posteriorly by the long head of the biceps femoris. It corresponds to a line drawn from just medial to the midpoint between the ischial tuberosity and greater trochanter to the apex of the popliteal fossa. Articular branches arise proximally to supply the hip joint through its posterior capsule, these are sometimes derived directly from the sacral plexus. Muscular branches are distributed to biceps femoris, semitendinosus, semimembranosus and the ischial part of adductor magnus [1]. The point of division of the sciatic nerve into tibial and common peroneal components is very variable. The common site is at the junction of the middle and lower thirds of the thigh, near the apex of the popliteal fossa. The division may occur at any level above this, though rarely below it. It is

### Corresponding Author

**Khushboo C. Arora**

Department of Anatomy, K.J. Somaiya Medical College, Somaiya Ayurvihar, Eastern Express Highway, Sion, Mumbai-400 022, Maharashtra, India.

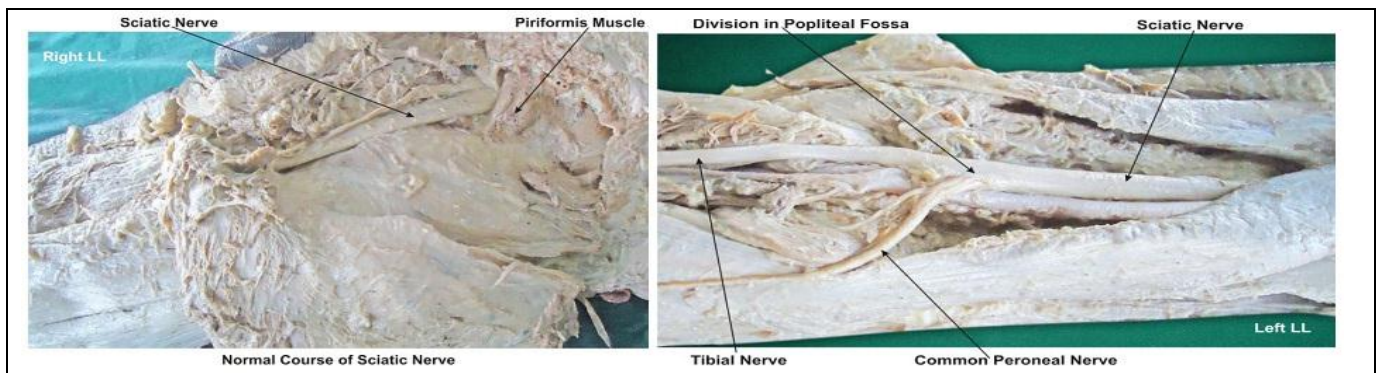
Email: kcarora98@gmail.com

not uncommon for the major components to leave the peroneal component usually passes through piriformis at the greater sciatic notch while the tibial component passes below the muscle [2]. The sciatic nerve supplies the knee flexors and all the muscles below the knee, so that a complete palsy of the sciatic nerve results in a flail foot and severe difficulty in walking. This is rare and usually related to trauma [3].

**Case Report:**

During routine dissection, of the right lower limb of 70 years old donated embalmed male cadaver in the

sacral plexus separately, in which case the common Department of Anatomy, K.J. Somaiya Medical College, Sion, Mumbai, India, we observed the low level division of the sciatic nerve in the popliteal fossa. The gluteal region, back of thigh and leg of the lower limb was dissected meticulously to record the course of the tibial and common peroneal nerve. The further course of the tibial and common peroneal nerve was normal. The pattern of vessels in the lower limb was normal. The variation was unilateral and the left lower limb was normal. The photographs of the sciatic nerve were taken for proper documentation.



**Table 1. The division of the sciatic nerve documented in various studies**

Study	Year	No. of specimens	Before exit	After exit
Pokomy et al (10)	2006	91; 182	20.9%	79.1%
Ugrenovic et al(11)	2005	100; 200	4.0%	96.0%
Gabrielli et al (12)	1997	40; 80	13.7%	86.3%
Guvencer et al(13)	2009	25; 50	48.0%	52.0%

**DISCUSSION**

The sciatic nerve divides into tibial and common peroneal components, most commonly at the lower part of the posterior compartment of the thigh [4]. Several authors have reported variations in its division into the tibial and common peroneal nerve from the sacral plexus to the lower part of the popliteal space [5-14]. Various studies have reported on the level of sciatic nerve division into tibial and common peroneal nerves (See the Table).

Saleh et al studied the level of division of the sciatic nerve into the tibial nerve and common peroneal nerve above the knee in 30 cadavers, and reported that the sciatic nerve divided at a distance of 50–180 mm above the popliteal fossa crease [15]. Güvençer et al examined 50 gluteal regions in 25 cadavers and observed that in 52% of the cases, the sciatic nerve exited the pelvis as a whole nerve without any division, whereas in 48% of the cases, a high division of sciatic nerve was recorded [13]. Suresh et al recorded the measurements from the magnetic resonance images of 59 patients and proposed a formula for determining the point of bifurcation of the sciatic nerve in the posterior thigh using a linear regression model [14]. The sciatic nerve is vulnerable in the posterior dislocation

of the hip. The sciatic nerve palsy occurs after total hip replacements [10]. As the sciatic nerve leaves the pelvis it passes either behind piriformis or sometimes through the muscle causing the piriformis syndrome. The piriformis syndrome is a common anatomical variant but an extremely rare entrapment neuropathy [6, 8-11]. In the present case the sciatic nerve divided proximal to its exit and the common peroneal nerve was coming out through the piriformis muscle. External compression over the buttock e.g. in patients who lie immobile on a hard surface for a considerable length of time, can injure the nerve. The commonest cause of serious sciatic nerve injury is iatrogenic. It may be damaged in misplaced therapeutic injections into gluteus maximus. The safe zone for deep intramuscular injections here is the upper outer quadrant of the buttock. Perhaps safer still is to inject into the quadriceps, though this can produce problems of its own, e.g. haemorrhage, leading to contracture of the muscle, which limits knee movement [15-17]. The sciatic nerve palsy can be due to sharp injury, burning from bone cement, traction from instruments, manipulation of the hip, inadvertent lengthening of the femur, or haematoma surrounding the nerve or within its soft tissue coverings.

Haematoma is characterised by the development of severe pain in the immediate postoperative period. Early surgical exploration and evacuation of haematoma can reverse the nerve lesion. The complete sciatic nerve palsy is very rare. For some reason, possibly anatomical, the common peroneal part is more usually affected. The patient has a foot drop and a high stepping gait. These anatomical variations may contribute to piriformis syndrome, sciatica, coccygodynia and muscle atrophy [17]. This should be taken into account by clinicians who are planning interventions around the sciatic nerve and its division in the lower extremity. Acute sciatic neuropathies commonly result from hip arthroplasty, hip fracture or dislocation [18]. Beaton & Anson classified variations of the piriformis and sciatic nerve in 120 specimens in 1937, and in 240 specimens in 1938 [19, 20]. Their classification, known as the Beaton & Anson classification, is as follows: Type 1: Undivided nerve below undivided muscle, Type 2: Divisions of nerve between and below undivided muscle, Type 3: Divisions above and below undivided muscle, Type 4: Undivided nerve between heads, Type 5: Divisions between and above heads and Type 6: Undivided nerve above undivided muscle. In the present case the sciatic nerve was coming out below the piriformis muscle i.e. Type 1 of Beaton & Anson classification.

#### Developmental Basis:

During embryological development at the base of the limb bud, the nerves contributing to the lower limb forms two plexuses i. e. lumbar and sacral. Later, as the elements from each of these plexuses grow out into the limb, they are subdivided into the dorsal and ventral components, for the dorsal and ventral musculatures. The sciatic nerve is formed when the large dorsal component of the sacral plexus the common peroneal nerve and the ventral component the tibial nerve move downward close together. Hence, based on their developmental formation, it is possible that the common peroneal and the tibial divisions of the sciatic nerve separate from each other at different levels from their origins; in the gluteal region, the posterior compartment of the thigh or the popliteal fossa [2, 19].

#### REFERENCES

1. Romanes GJ (2012) *Cunningham's Manual of Practical Anatomy*, Vol. 1, 15th Edition, Oxford University, United States, New York, 152 – 168.
2. Standring S. *Gray's Anatomy*, 39th Ed, London: Elsevier Churchill Livingstone. pp 1364-1458.
3. Yuen EC, So YT. (1999) Sciatic neuropathy. *Neurol Clin*, 17, 617-31.
4. Rosse C, Gaddum-Rosse P, Hollinshead WH. Hollinshead's (1997) *Textbook of Anatomy*. 5th ed. Philadelphia: Lippincott-Raven Publishers, 324-651.
5. Paval J, Nayak S. (2006) A case of bilateral high division of sciatic nerve with a variant inferior gluteal nerve. *Neuroanatomy*, 5, 33-4.

#### Clinical significance:

There is no failure of popliteal block anaesthesia in case of the low level division of the sciatic nerve [18, 20, 21]. The extent of involvement and neurological deficits vary depending on the level of division of the sciatic nerve. A low level division of the sciatic nerve into the tibial and common peroneal nerves can result in the involvement of the entire nerve, which would result in an increase in neurological deficits.

#### CONCLUSION

The awareness of low level division of the sciatic nerve into the tibial and common peroneal nerves is clinically important for surgeons dealing with entrapment or compressive neuropathies, orthopaedicians operating on the fractures of femur, anaesthetist performing pain management therapies on the lower limb and physiotherapist doing electromyography for evaluating and recording the electrical activity produced by skeletal muscles. A lack of knowledge of such type of variations might complicate surgical repair.

#### Acknowledgement:

Authors are thankful to Dean Dr. Vinayak Sabnis Sir for his support and encouragement. Authors are also thankful to Mr. M. Murugan, Mrs. Pallavi Kadam, Mr. Shivaji Dalvi, Mr. Kishor Rangle, Mr. Shankush Adkhale, Mr. Sanjay Shinde, Mr. Kishor Beradiya and Mr. Panduj for their help. Authors also acknowledge the immense help received from the scholars whose articles are cited and included in references of this manuscript. The authors are also grateful to authors / editors / publishers of all those articles, journals and books from where the literature for this article has been reviewed and discussed.

#### Conflict of Interest

The authors declare that they have no conflict of interest.

#### Statement of Human and Animal Rights

All procedures performed in human participants were in accordance with the ethical standards of the institutional research committee and with the 1964 Helsinki declaration and its later amendments or comparable ethical standards. This article does not contain any studies with animals performed by any of the authors.

6. Arifoglu Y, Sürücü HS, Sargon MF, Tanyeli E, Yazar F. (1997) Double superior gemellus together with double piriformis and high division of the sciatic nerve. *Surg Radiol Anat*, 19, 407-8.
7. Schwemmer U, Markus CK, Greim CA, et al. (2004) Sonographic imaging of the sciatic nerve and its division in the popliteal fossa in children. *Paediatr Anaesth*, 14,1005-8.
8. Babinski MA, Machado FA, Costa WS. (2003) A rare variation in the high division of the sciatic nerve surrounding the superior gemellus muscle. *Eur J Morph*, 41, 41-2.
9. Demiryurek D, Bayramoglu A, Erbil M, Aldur MM, Mustafa ES. (2002) Bilateral divided piriformis muscle together with the high division of the sciatic nerve. *Gazi Med J*, 13, 41-4.
10. Pokorný D, Jahoda D, Veigl D, Pinskerová V, Sosna (2006) A. Topographic variations of the relationship of the sciatic nerve and the piriformis muscle and its relevance to palsy after total hip arthroplasty. *Surg Radiol Anat*, 28, 88-91.
11. Ugrenović S, Jovanović I, Krstić V, et al. (2005) The level of the sciatic nerve division and its relations to the piriform muscle. *Vojnosanit Pregl*, 62, 45-9.
12. Gabrielli C, Olave E, Mandiola E, et al. (1997) Inferior gluteal nerve course associated to the high division of the sciatic nerve. *Rev Chil Anat*, 15, 79-83.
13. Güvencer M, Iyem C, Akyer P, Tetik S, Naderi S. (2009) Variations in the high division of the sciatic nerve and relationship between the sciatic nerve and the piriformis. *Turk Neurosurg*, 19, 139-44.
14. Suresh S, Simion C, Wyers M, et al. (2007) Anatomical location of the bifurcation of the sciatic nerve in the posterior thigh in infants and children: a formula derived from MRI imaging for nerve localization. *Reg Anesth Pain Med*, 32, 351-3.
15. Ndiaye A, Sakho Y, Fall F, Dia A, Sow ML. (2004) Sciatic nerve in gluteal portion: application of sciatic nerve post injection lesion. *Morphologie*, 88, 135-8.
16. Valade N, Ripart J, Nouvellon E, et al. (2008) Does sciatic parasacral injection spread to the obturator nerve? An anatomic study. *Anesth Analg*, 106, 664-7.
17. Benzon HT, Katz JA, Benzon HA, Iqbal MS. (2003) Piriformis syndrome: anatomic considerations, a new injection technique, and a review of the literature. *Anesthesiology*, 98, 1442-8.
18. Nayak S. An unusual case of trifurcation of the sciatic nerve. *Neuroanatomy*, 5, 6-7.
19. Beaton LE, Anson BJ: (2008) The relation of the sciatic nerve and its subdivisions to the piriformis muscle. *Anat Rec 1937*, 70: 1–5.
20. Beaton LE: (1938) The sciatic nerve and piriform muscle: Their interrelationa possible cause of coccgodynia. *J Bone Joint Surgery Am*, 20, 686–688.
21. Moore KL, Dalley AF. (1999) *Clinically Oriented Anatomy*. 4th ed. Philadelphia: Lippincott Williams & Wilkins, 347-560.

**Cite this article:**

Khushboo C. Arora, Sharadkumar P. Sawant, Shaheen Rizvi. Variant Low Level Division Of The Sciatic Nerve At Knee Level – A Case Report. *International Journal Of Advances In Case Reports*, 4(3), 2017, 169-172.

DOI: <http://dx.doi.org/10.21276/ijacr.2017.4.3.20>



Attribution-NonCommercial-NoDerivatives 4.0 International