



## VARIANT BRANCHING PATTERN OF RADIAL NERVE - A CASE REPORT

Medha. H. Shah<sup>1\*</sup>, Sharadkumar P. Sawant<sup>2</sup>, Shaheen Rizvi<sup>3</sup>

<sup>1</sup>First MBBS, <sup>2</sup>Professor and Head, <sup>3</sup>Assistant Lecturer, Department of Anatomy, K. J. Somaiya Medical College, Somaiya Ayurvihar, Eastern Express Highway, Sion, Mumbai-400 022, Maharashtra, India.

### ABSTRACT

During routine dissection, of the right upper limb of a 70 year old donated embalmed male cadaver in the Department of Anatomy, K.J. Somaiya Medical College, Sion, Mumbai, India, I observed a variant division of radial nerve in the lower part of the left arm. The radial nerve divided into three branches, a superficial branch of radial nerve (the radial nerve proper), a deep branch of the radial nerve (posterior interosseous nerve) and a nerve to the extensor carpi radialis brevis muscle. The arterial pattern of upper limb was normal. The variation was unilateral. The right upper limb was also normal. The photographs of the variations were taken for proper documentation. Conclusions. The awareness of the nerve supply to extensor carpi radialis brevis from the terminal branch of radial nerve is clinically important for surgeons dealing with entrapment or compressive neuropathies, orthopaedicians operating on the fractures of the lower end of the humerus, anesthetist performing pain management therapies on the upper limb and physiotherapist doing electromyography for evaluating and recording the electrical activity produced by skeletal muscles. A lack of knowledge of such type of variations might complicate surgical repair.

**Key words:** Extensor Carpi Radialis Brevis, Trifurcation of Radial Nerve, Radial Nerve Proper, Posterior Interosseous Nerve, Nerve to Extensor Carpi Radialis Brevis, Surgeons, Compressive Neuropathies, Orthopaedicians, Fractures, Anesthetist, Pain Management Therapy, Physiotherapist, Electromyography.

Access this article online

Home page:

<http://www.mcmed.us/journal/ijacr>

DOI:

<http://dx.doi.org/10.21276/ijacr.2017.4.3.9>

Quick Response code



Received:25.02.17

Revised:12.03.17

Accepted:25.03.17

### INTRODUCTION

The extrinsic extensor muscles of the hand are located in the back of the forearm and have long tendons connecting them to bones in the hand, where they exert their action. Extrinsic denotes their location outside the hand. Extensor denotes their action which is to extend, or open flat, joints in the hand. The extensor carpi radialis brevis is one of the superficial muscles of the extensor compartment of the forearm. The extensor carpi radialis

brevis muscle is shorter and thicker than the extensor carpi radialis longus muscle.

It arises from the lateral epicondyle of the humerus, by a tendon common to it and the three following muscles; from the radial collateral ligament of the elbow-joint; from a strong aponeurosis which covers its surface; and from the intermuscular septa between it and the adjacent muscles. The fibers end about the middle of the forearm in a flat tendon, which is closely connected with that of the extensor carpi radialis longus muscle, and accompanies it to the wrist; it passes beneath the abductor pollicis longus and extensor pollicis brevis, then beneath the dorsal carpal ligament, and is inserted into the dorsal surface of the base of the third metacarpal bone on its

### Corresponding Author

**Medha H. Shah**

Department of Anatomy, K.J. Somaiya Medical College, Somaiya Ayurvihar, Eastern Express Highway, Sion, Mumbai-400 022, Maharashtra, India.

Email: medha2707@gmail.com

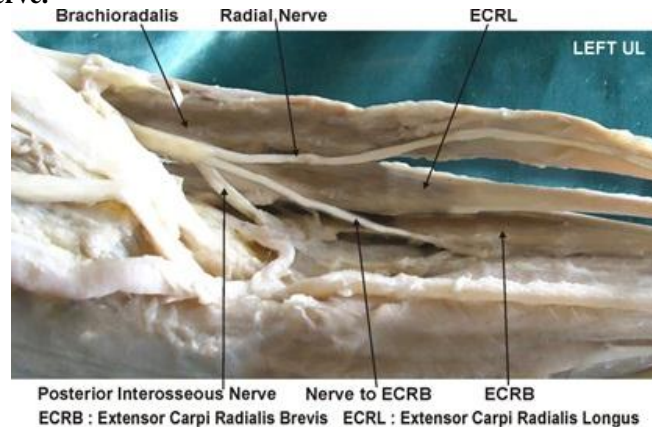
radial side. Under the dorsal carpal ligament the tendon lies on the back of the radius in a shallow groove, to the ulnar side of that which lodges the tendon of the extensor carpi radialis longus, and separated from it by a faint ridge. The tendons of the two preceding muscles pass through the same compartment of the dorsal carpal ligament in a single mucous sheath. The extensor carpi radialis longus muscle is supplied by the radial nerve and the extensor carpi radialis brevis muscle by the deep branch of the radial nerve (posterior interosseous nerve). The extensor carpi radialis longus and brevis muscles receive blood from the radial artery [1]. It is a universally accepted fact that the variation in the nerve supply to any muscle of the extremity is of definite surgical importance in order to avoid any error surgery.

### CASE REPORT

During routine dissection, of the right upper limb of a 70 year old donated embalmed male cadaver in the Department of Anatomy, K.J. Somaiya Medical College, Sion, Mumbai, India, I observed the variant division of

radial nerve in the lower part of the left arm. The radial nerve divided into three branches, a superficial branch of radial nerve (the radial nerve proper), a deep branch of the radial nerve (posterior interosseous nerve) and a nerve to the extensor carpi radialis brevis muscle. The finding was noted after thorough and meticulous dissection of the upper limbs of both sides. The superficial muscles of the extensor compartment of the forearm were separated from each other, starting with the tendons at the wrist. The three anterolateral muscles the brachioradialis, extensor carpi radialis longus and brevis were completely separated from the extensor digitorum and the supinator muscle which lay deep in these muscles, was exposed. The deep branch of the radial nerve, the posterior interosseous nerve, was dissected. The nerve which supplied extensor carpi radialis brevis was then identified in all the specimens. The arterial pattern of upper limb was also observed. The variation was unilateral. The right upper limb was normal. The photographs of the variations were taken for proper documentation.

**Figure 1. showing photographic presentation of the nerve to the extensor carpi radialis brevis arising from the angle of bifurcation of the radial nerve.**



### DISCUSSION

The nerve supply to the extensor carpi radialis brevis muscle is studied by many authors in the past [1,2,3]. The superficial branch of the radial nerve i.e. radial nerve proper is a purely sensory nerve and the nerve supply to the extensor carpi radialis brevis muscle is from the posterior interosseous nerve. The standard text books did not mention about the nerve supply to the extensor carpi radialis brevis arising from the superficial branch of the radial nerve i.e. radial nerve proper [1]. The incidence of the nerve supply to the extensor carpi radialis brevis muscle from the superficial branch of the radial nerve i.e. radial nerve proper had been reported by Salisbury, Al-Qattan and Brash as 56%, 48% and 21% limbs respectively [4, 5, 6]. In the present case it was observed that the radial nerve divides into three branches, superficial branch of radial nerve i.e. the radial nerve proper, deep branch of the

radial nerve i.e. posterior interosseous nerve and nerve to the extensor carpi radialis brevis muscle.

The nerve supply to the extensor carpi radialis brevis muscle was from the terminal branch of the radial nerve. In tennis elbow the muscle involved is the extensor carpi radialis brevis. The non-inflammatory, chronic degenerative changes occur in the origin of the extensor carpi radialis brevis muscle. It is well known that the normal origin and the course of the nerve to the extensor carpi radialis brevis lie very close to the posterolateral aspect of the radius, a frequent site of pathology (e.g. infections and tumors), trauma and surgical procedures[7]. The anterior approach to the elbow and the variations in this approach are used frequently in the surgical management of proximal radial fractures, as well as a variety of other pathologies. Such maneuvers involve the separation of the extensor carpi radialis brevis distally,

with resultant exposure of the radial nerve and its branches. Hence, the knowledge of variations of the nerve supply of the extensor carpi radialis brevis is essential in preventing injury to this nerve branch by the retractors [8].

### Clinical Significance

The knowledge of the variant nerve supply to the extensor carpi radialis brevis muscle is important before injecting corticosteroid injections in the treatment of tennis elbow. The surgeons performing Z-shaped tenotomy on tennis elbow to lengthen the tendon of extensor carpi radialis brevis must be aware of this variation in order to avoid unwanted complications (9,10). Variations in the nerve supply of the extensor carpi radialis brevis are important clinically. The extensor carpi radialis brevis may be spared in injuries to the posterior interosseous nerve, thereby explaining the preservation of some wrist function clinically after penetrating injuries which may otherwise result in a complete wrist drop [11]. Recently, extensor carpi radialis brevis has also gained importance for use in 'free functional muscle transfer' i.e. transfer of a muscle with its motor nerve and vascular pedicle from one site of the body to another distant site, in order to restore the motor function. The knowledge of the variations in the nerve supply is thus important while this muscle is being harvested [12].

### CONCLUSION

The trifurcation of the radial nerve is not a rare occurrence. The awareness of the trifurcation of radial nerve is clinically important for surgeons dealing with entrapment or compressive neuropathies, orthopaedicians

### REFERENCES

1. Williams PL, Bannister LH, Berry MM, Collins P, Dyson M, Dussek JE, et al. (2005). The Nervous system. In: *Gray's Anatomy*, 39th edn, Churchill Livingstone, New York, 879 - 880.
2. Hamilton WJ. (1976). *Textbook of the Human Anatomy*, 2nd edn, Macmillan Press Ltd, London. 651.
3. Last RJ. (1984). *Anatomy: Regional and Applied*, 7th edn, Churchill Livingstone, Edinburgh. 89.
4. Salisbury CR. (1938). The nerve to the extensor carpi radialis brevis. *Brit. J. Surg*, 26, 95-98.
5. Al-Qattan M.M. (1996). The nerve supply to the extensor carpi radialis brevis. *J. Anat.* 188, 249-50.
6. Brash JC. (1955) *Neurovascular hila of the limb muscles*. E and S Livingstone Ltd., Edinburgh, 36.
7. Snell RS. (1995). *Clinical Anatomy for Medical Students*, 5th edn, Little Brown and Company, USA. 434.
8. Turck SL. (1984). *Orthopaedic principles and their applications*, 4th edn, JB Lippincott., Philadelphia. 497- 498.
9. Garden RS. (1961) Tennis elbow. *J Bone Joint Surg*, 43B(1), 100-106.
10. Boyer MI, Hastings H (1999). "Lateral tennis elbow: "Is there any science out there?"". *Journal of Shoulder and Elbow Surgery*, 8(5), 481-91.
11. Kaplan EB, Taleisnik J. (1984). The wrist. In: *Kaplan's Functional and Surgical Anatomy of the Hand*, 3rd edn, J. B. Lippincott, Philadelphia. 153-178.
12. Sabiston DC. (1997). The biological basis of modern surgical practice. In: *The Textbook of Surgery*, 15th edn, W. B. Saunders Company, Philadelphia. 1484.

### Cite this article:

Medha. H. Shah, Sharadkumar P. Sawant, Shaheen Rizvi. Variant branching pattern of radial nerve - a case report. *International Journal Of Advances In Case Reports*, 4(3), 2017, 130-132. DOI: <http://dx.doi.org/10.21276/ijacr.2017.4.3.9>



Attribution-NonCommercial-NoDerivatives 4.0 International